

This trademark shows our wish for everyone to be healthy.

©All rights are reserved by Eiji Tomita December 2014

Group Ultima (Confidential)

- ① What are the techniques of removing pain caused by using denture in one second**
- ② Non-clasp denture**
- ③ Occlusion brings about miracle**

“Easy to fall over”

“Feeling nauseous”

“Unpleasant feeling of tongue”

“Lockjaw”

“Dul”

“Unable to bite well”

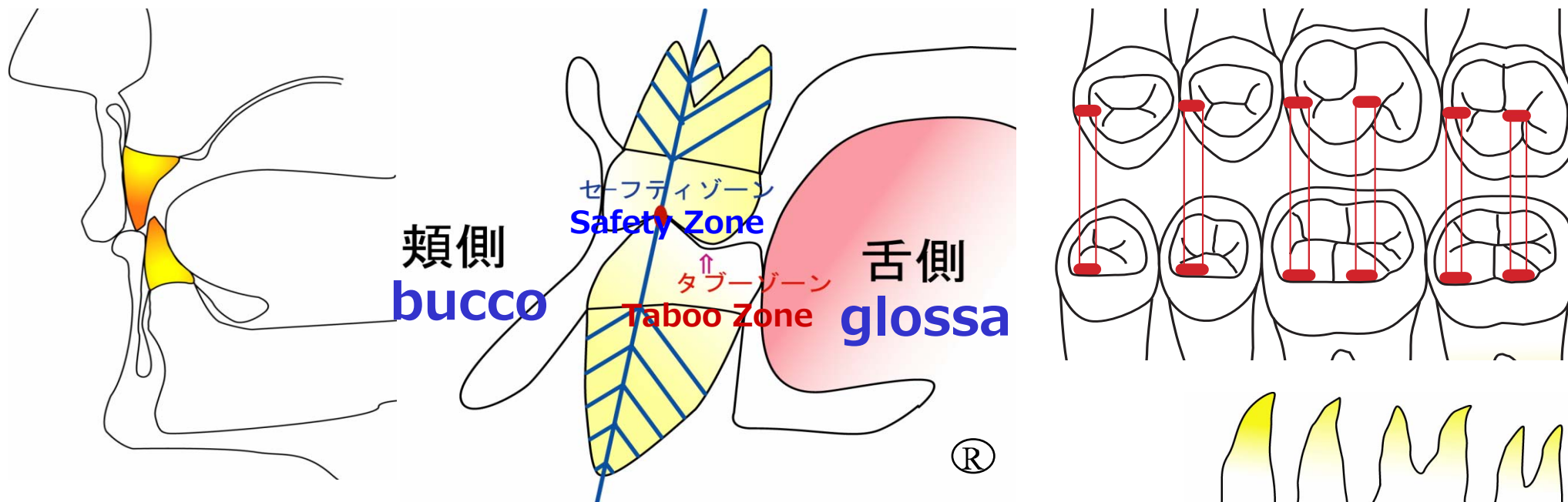
**“Speech disorder difficult to
pronounce “s” sound”**

“migraine headache”

L · B · O[®]

lower buccalized occlusion

Definition of healthy occlusion



頬側
bucco

セーフティゾーン
Safety Zone

↑
タブーゾーン
Taboo Zone

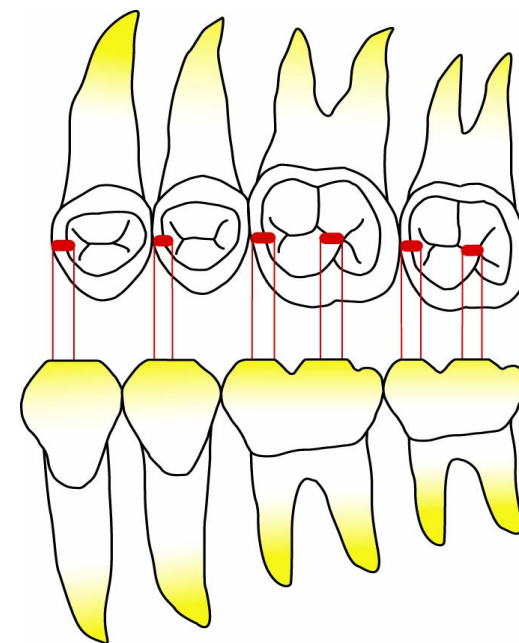
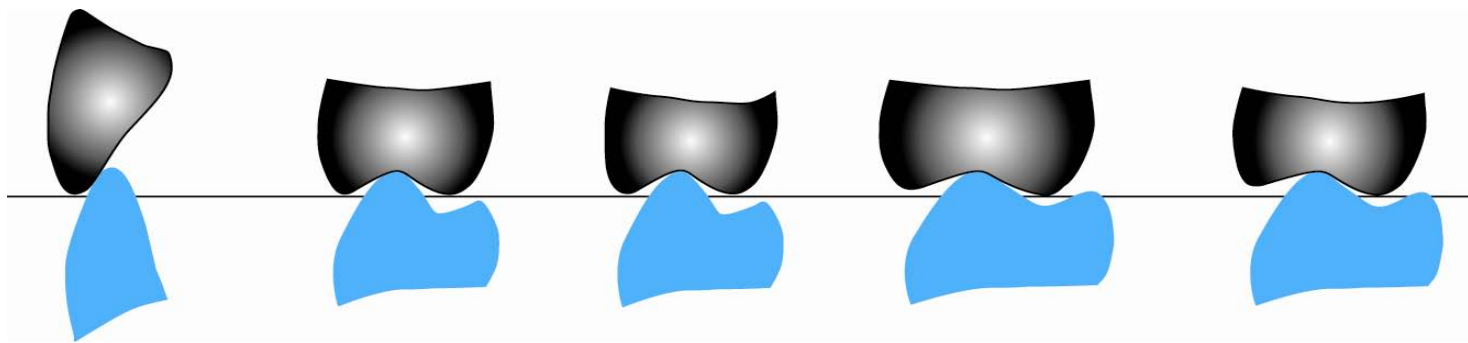
舌側
glossa

®

Leave the space of
1 sheet of paper in
between

Safety Zone ... occlusion point

Taboo Zone...non-occlusion point



©All rights are reserved by
Eiji Tomita December 2014

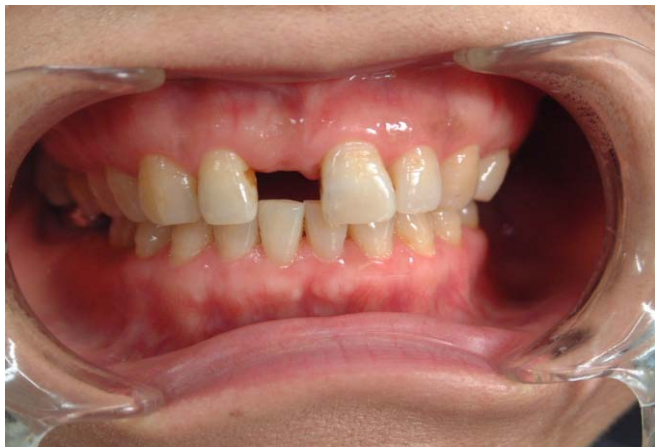Your health starts from teeth

Natural teeth

Denture

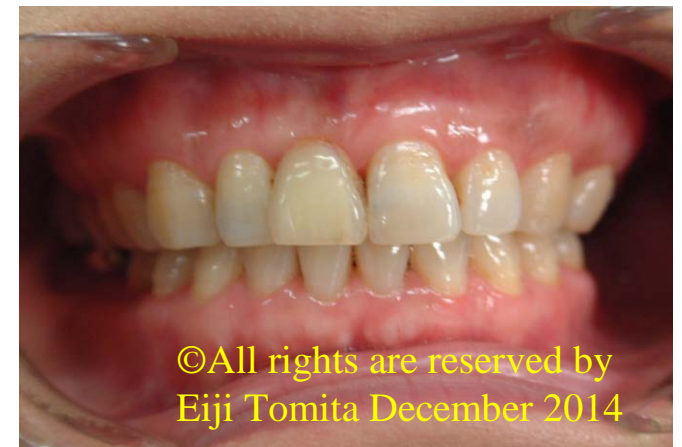Full Denture

Partial Denture



crown prosthesis

L.B.O[®] application



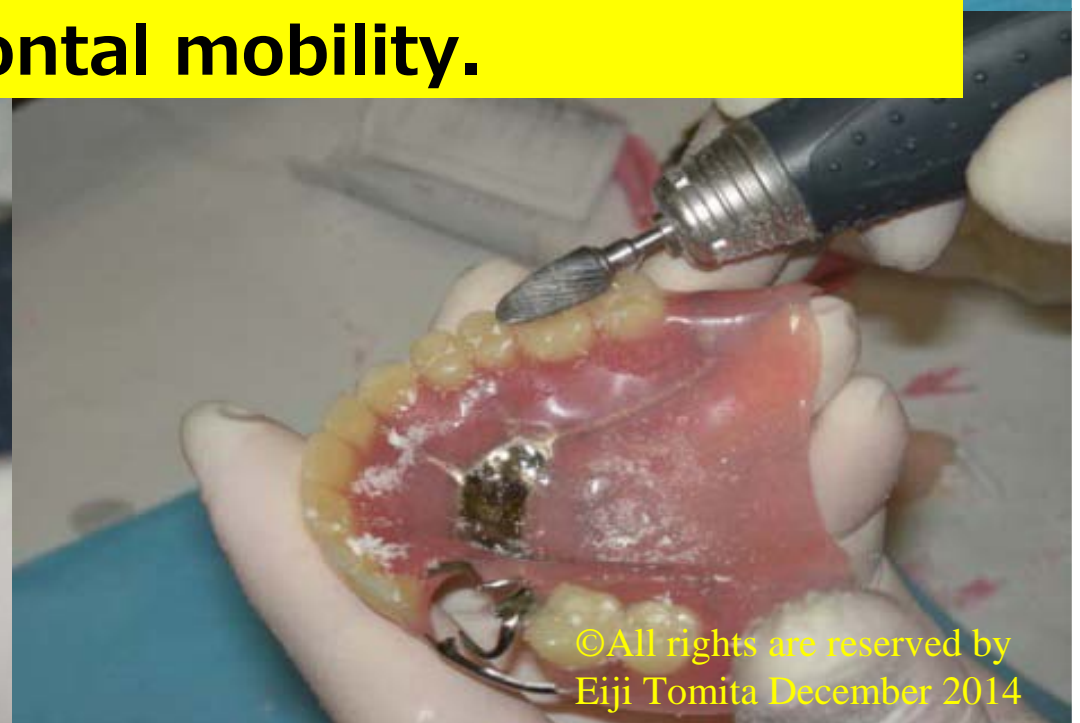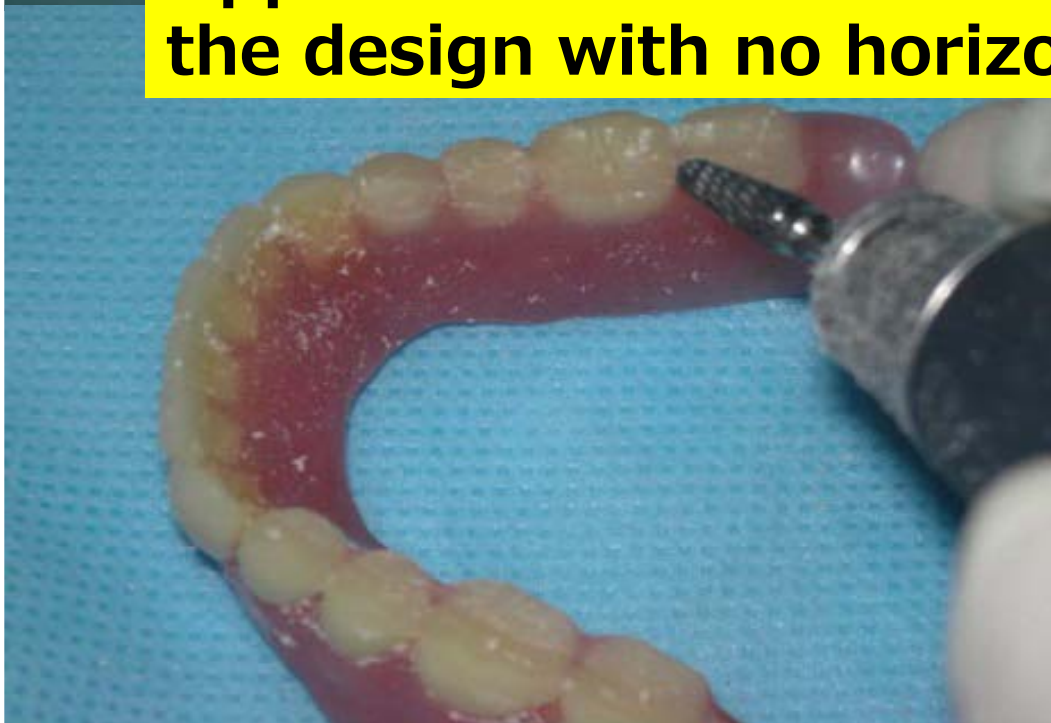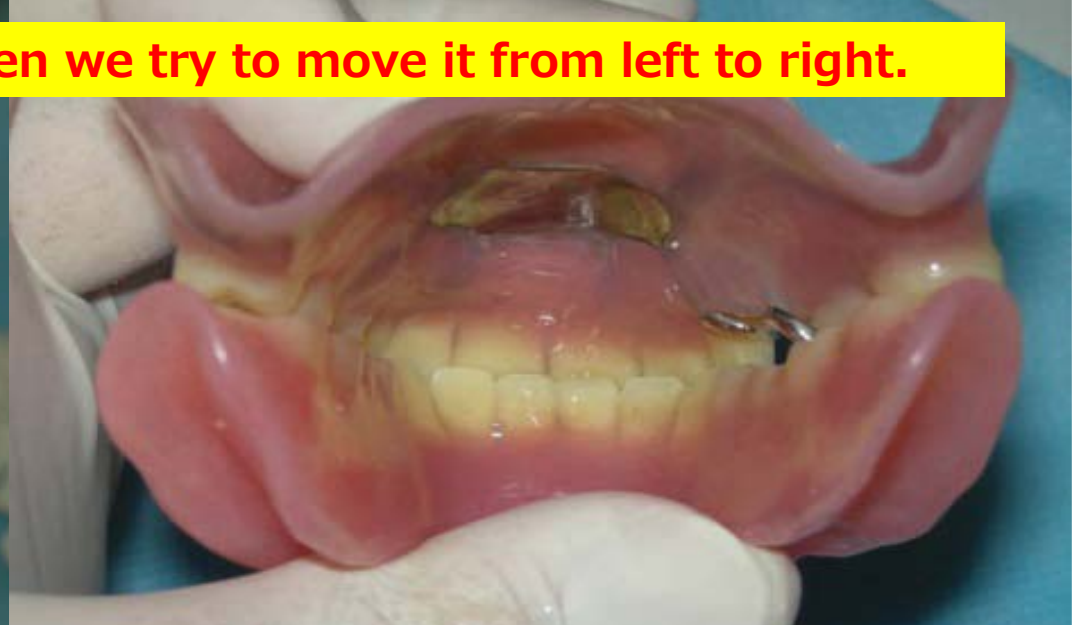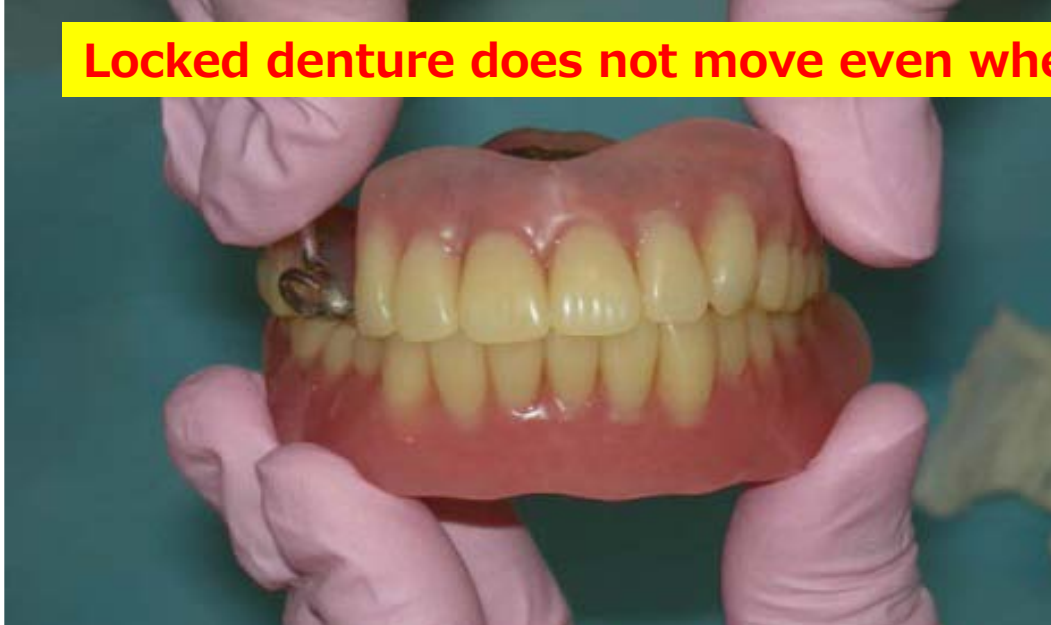©All rights are reserved by
Eiji Tomita December 2014

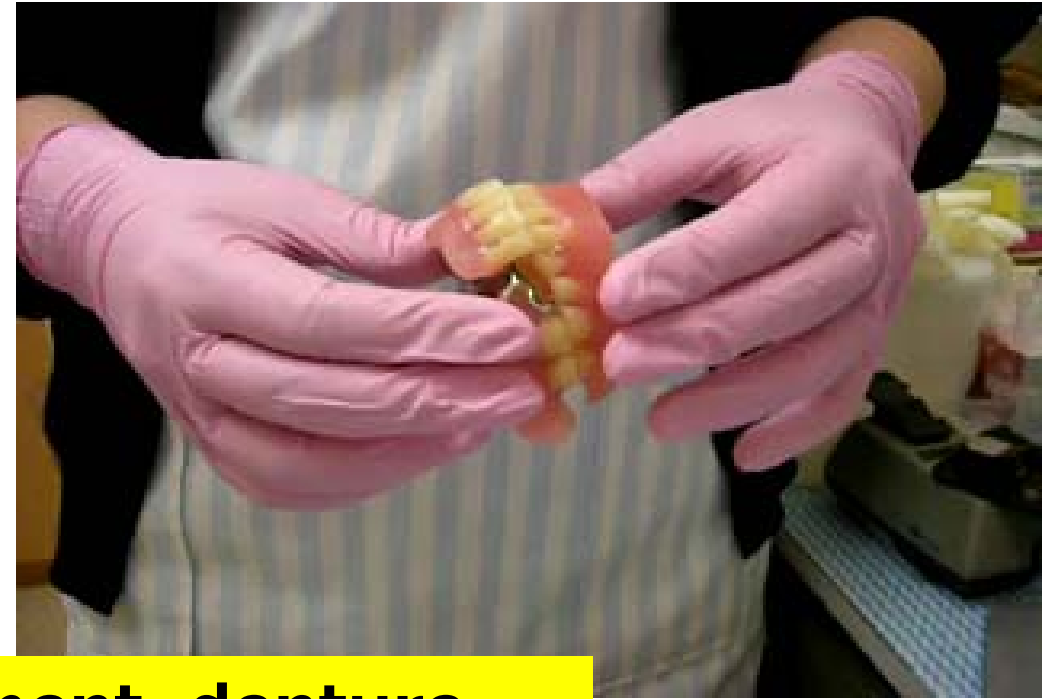
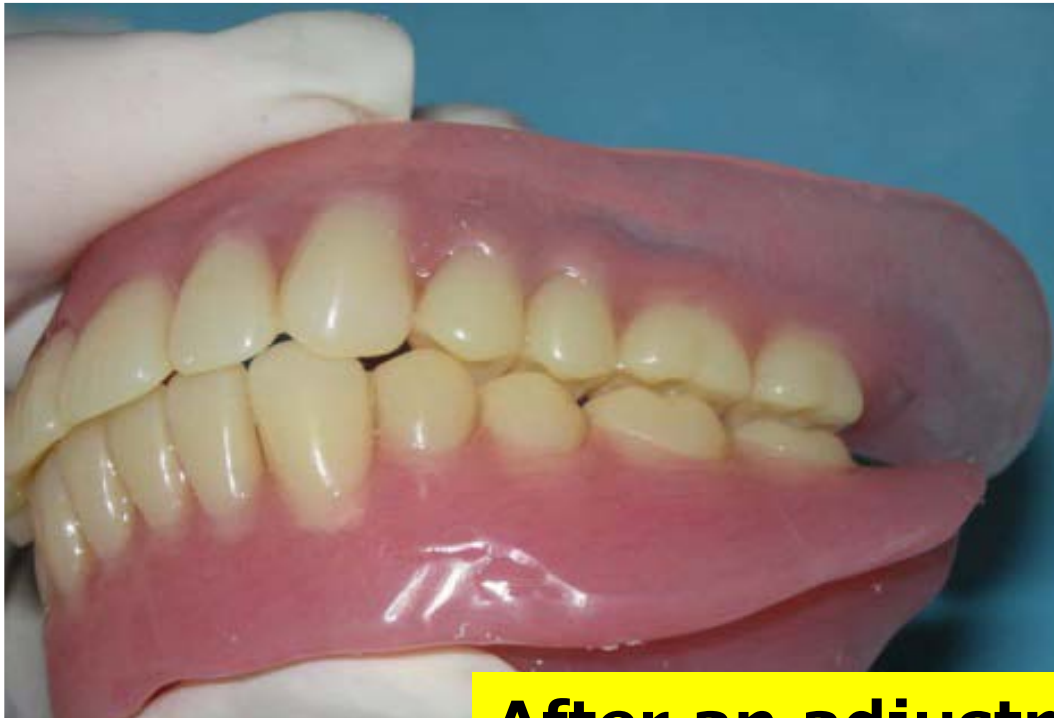
**Technique to
remove pains
in one
second**

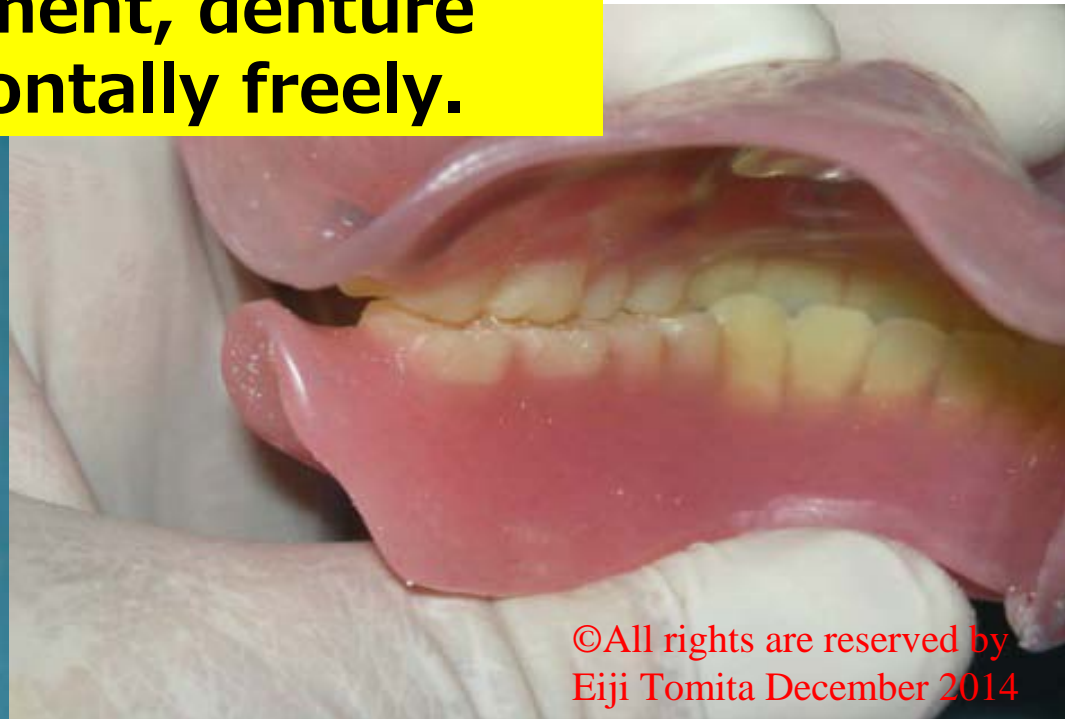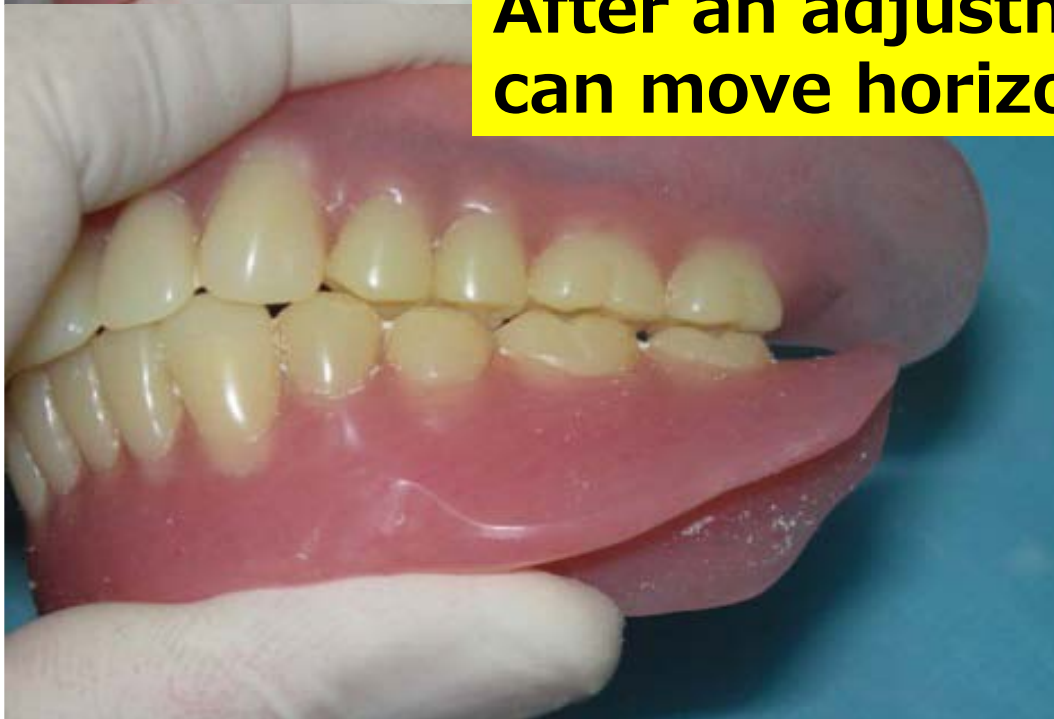Locked denture does not move even when we try to move it from left to right.

Upper and lower dentures that are made based on the design with no horizontal mobility.





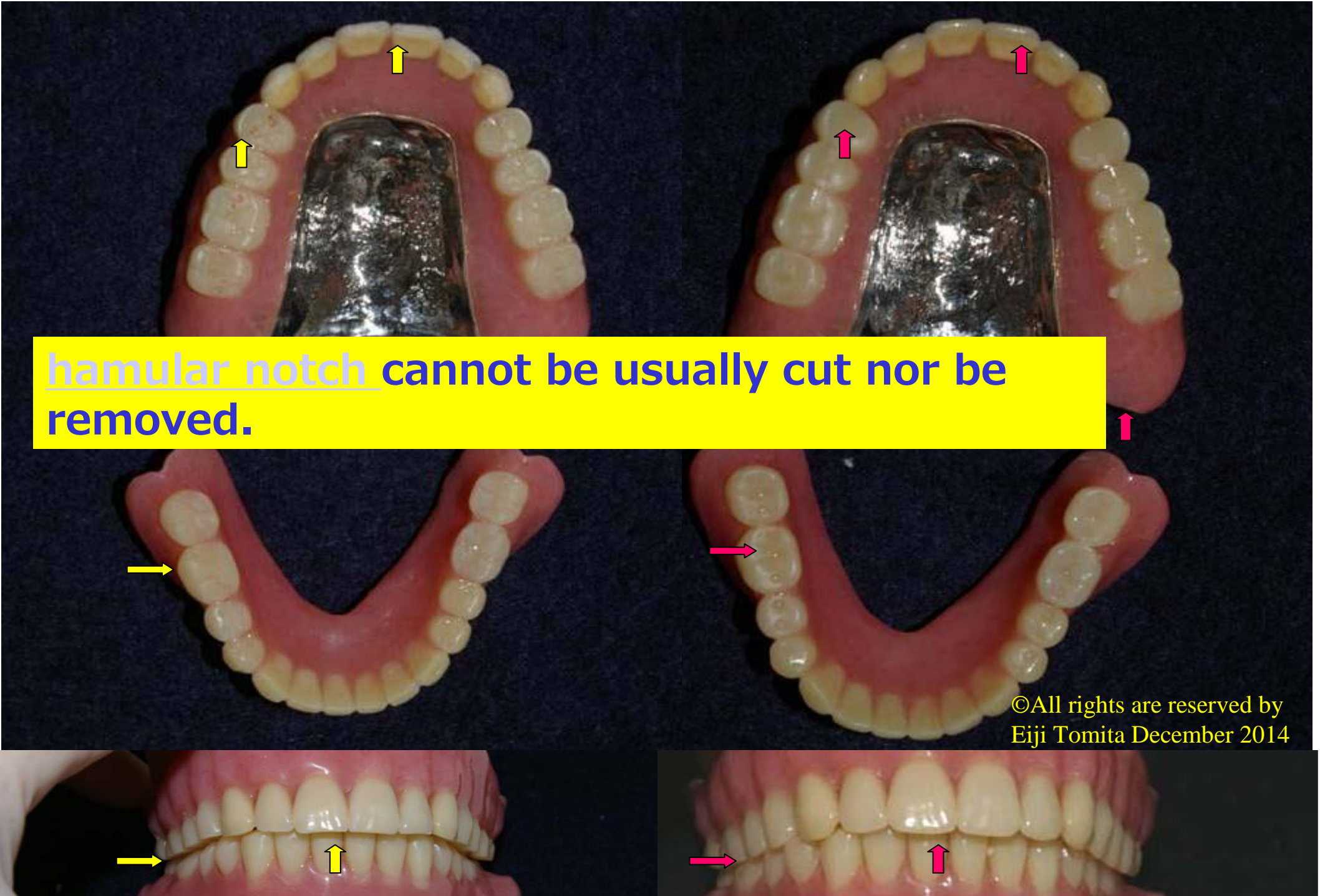**After an adjustment, denture
can move horizontally freely.**





Pain is removed by just having a bite control by the technical specialist.

©All rights are reserved by
Eiji Tomita December 2014

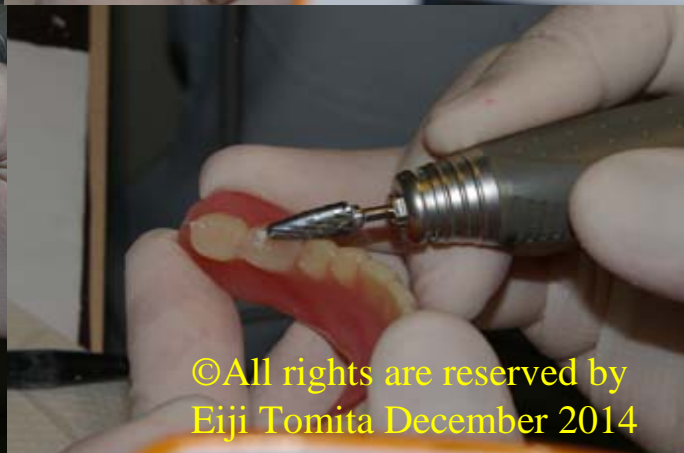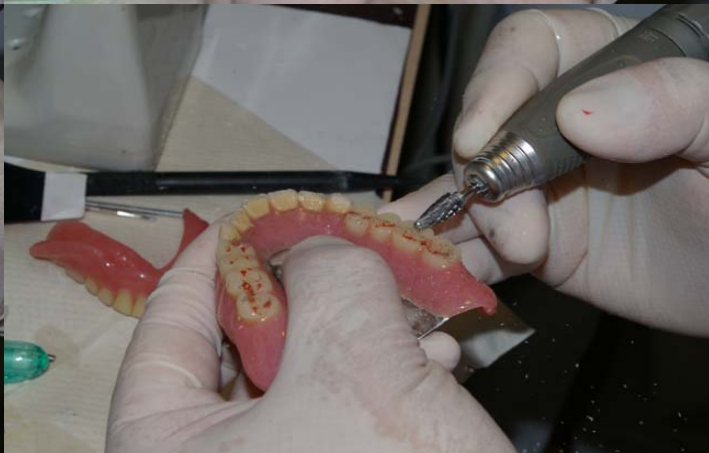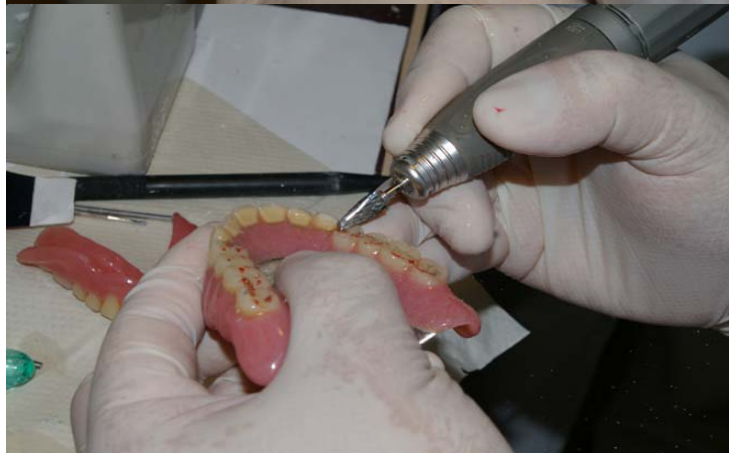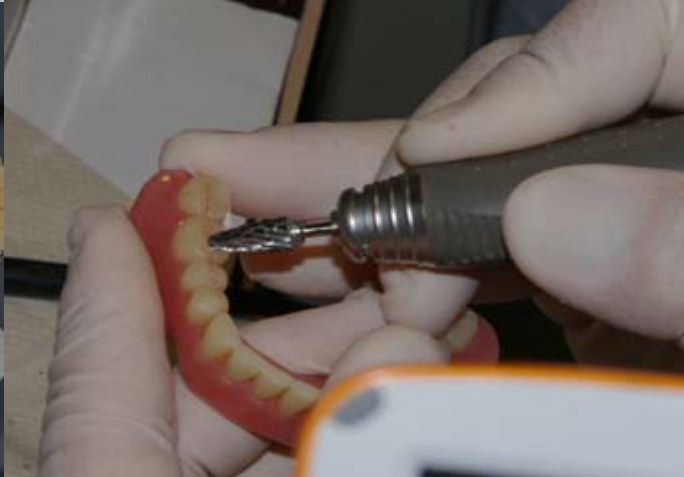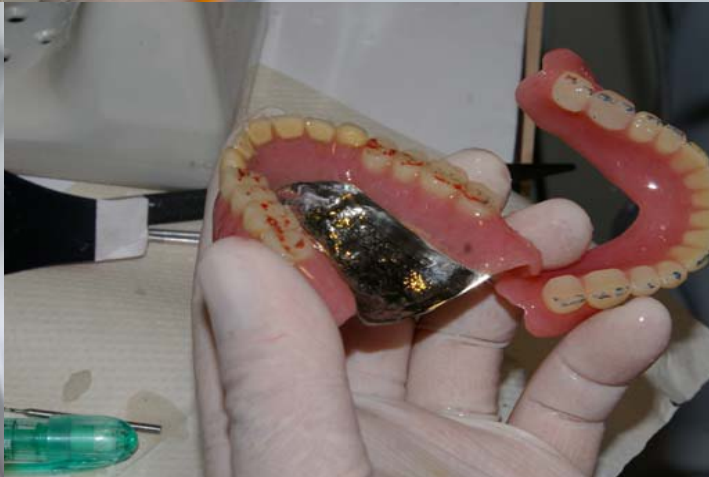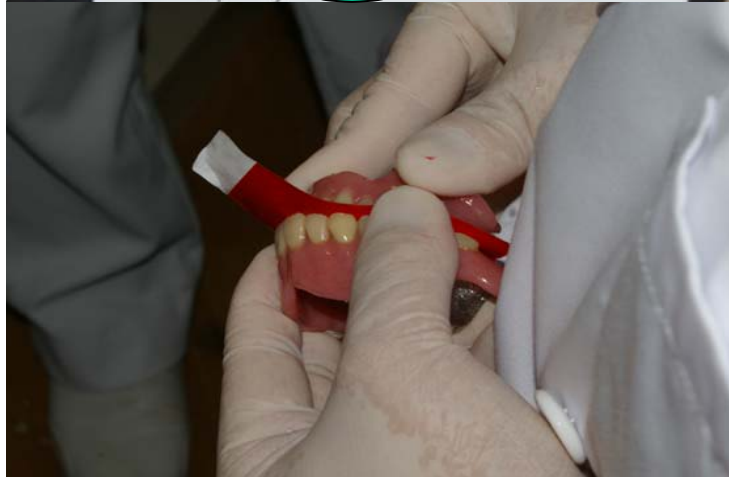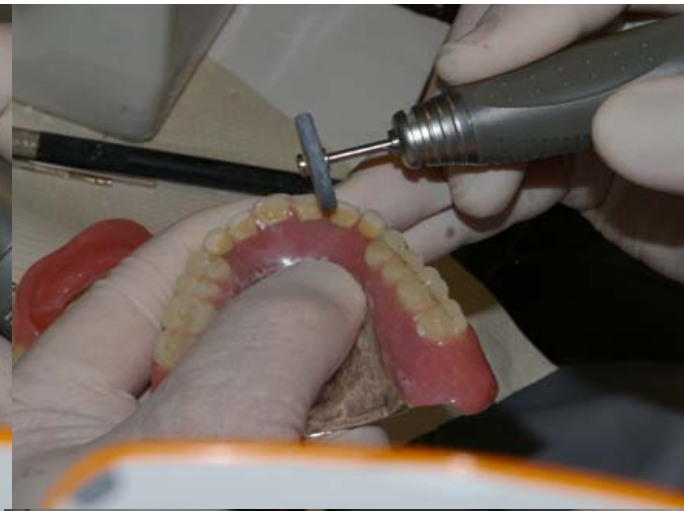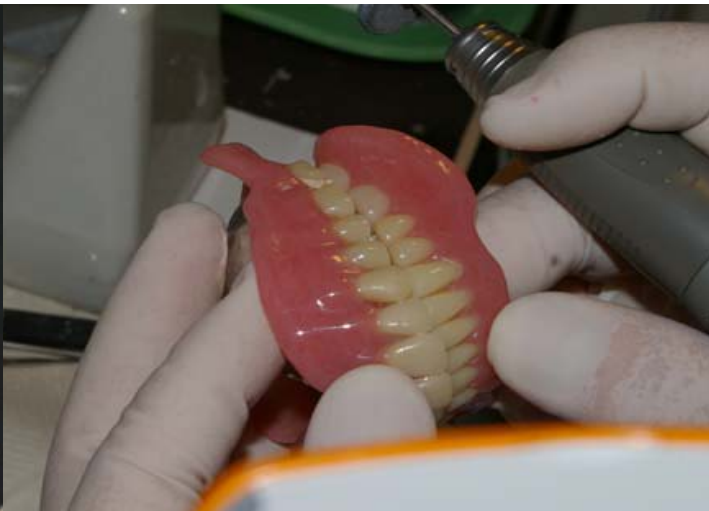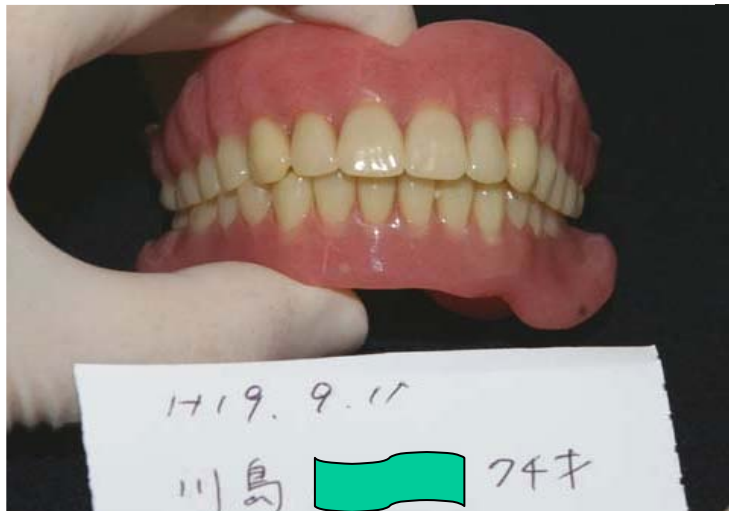



hamular notch cannot be usually cut nor be removed.

©All rights are reserved by Eiji Tomita December 2014



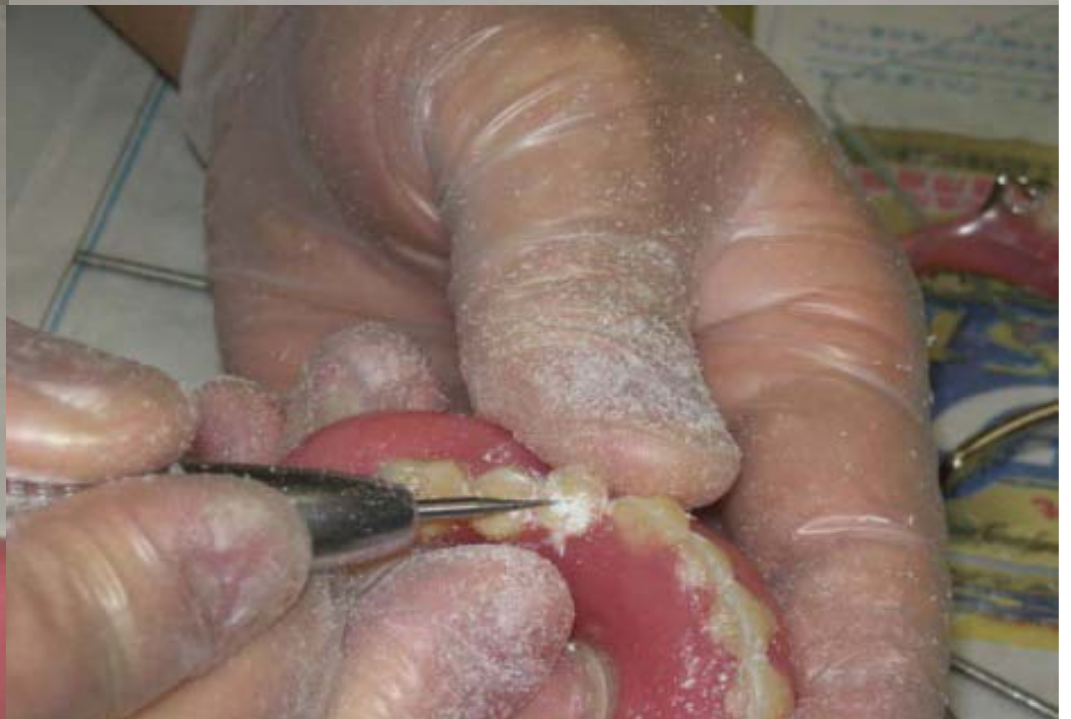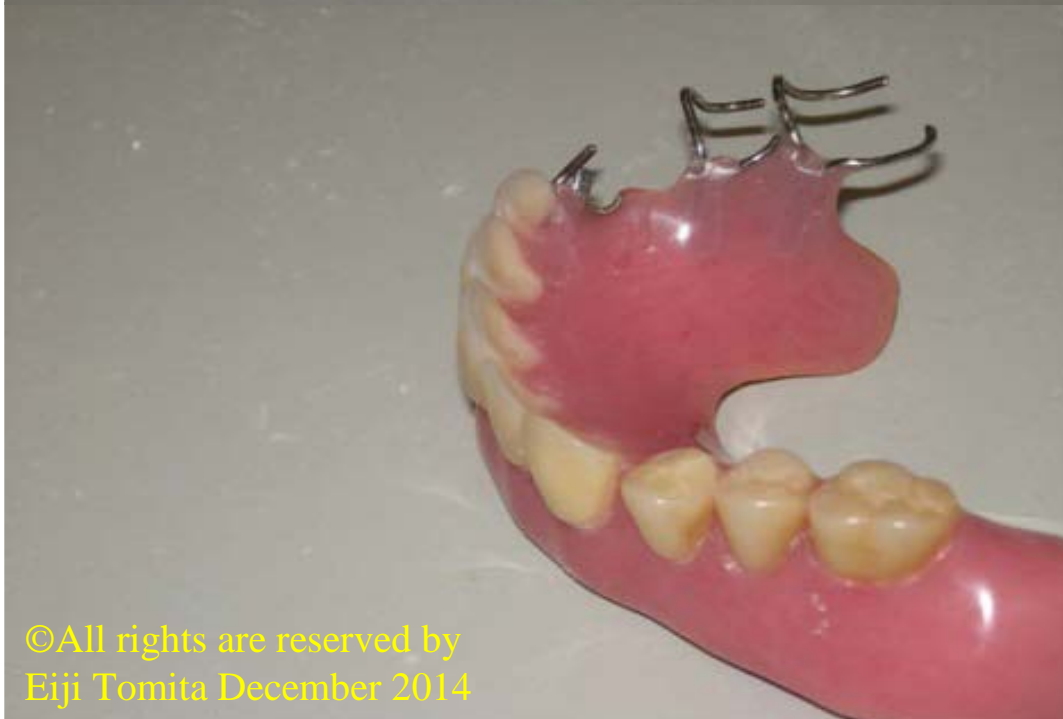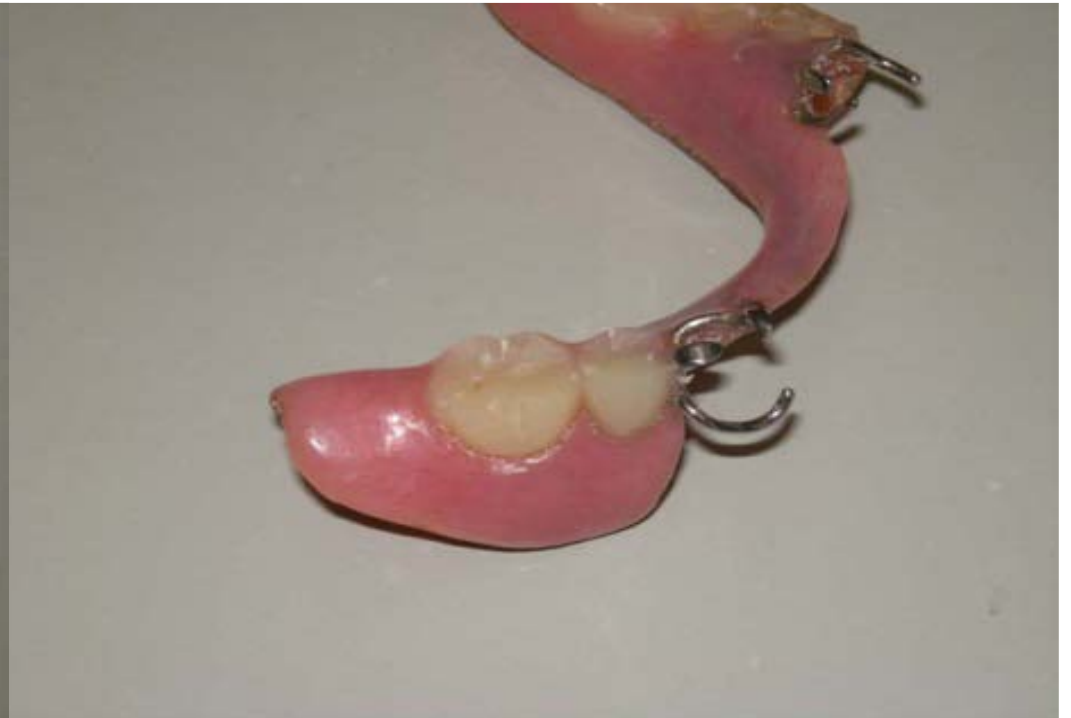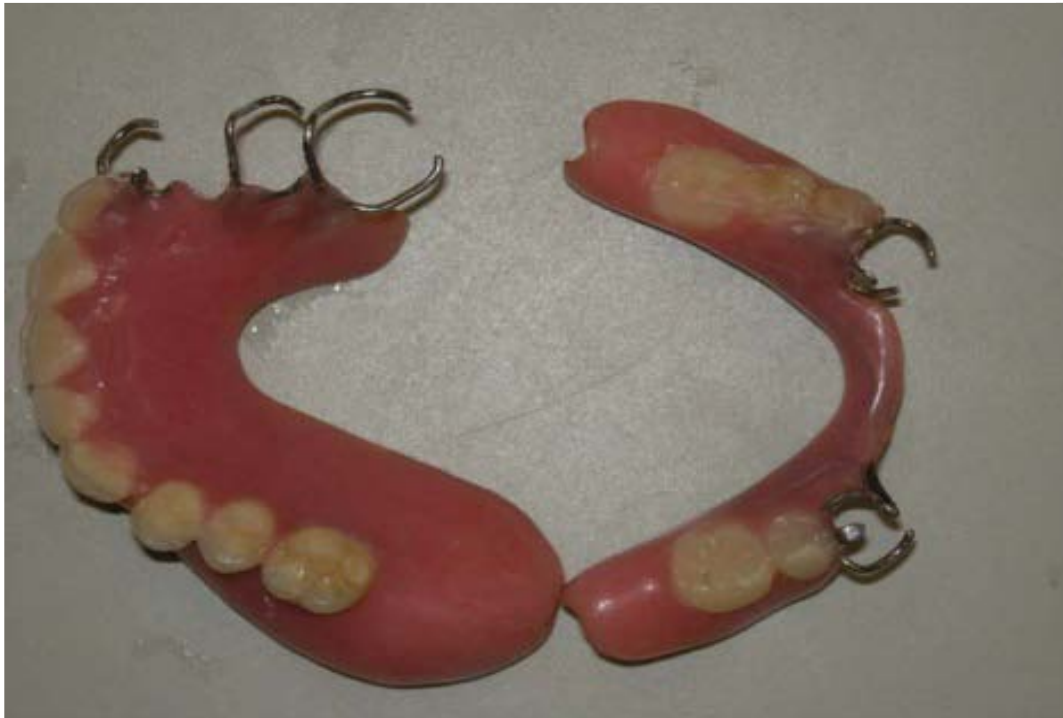©All rights are reserved by
Eiji Tomita December 2014



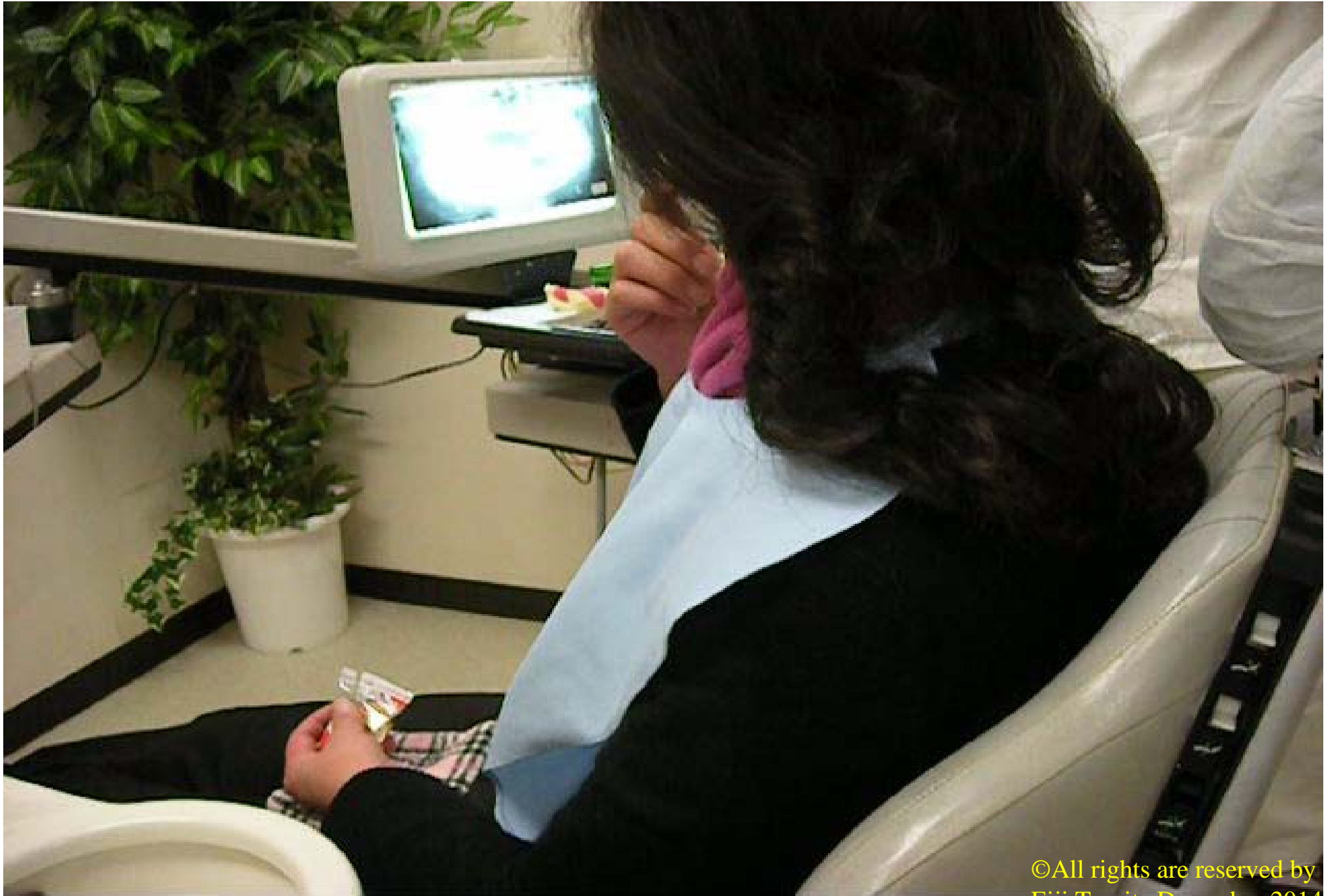A photograph of a person in a dental office. The person is wearing a light blue shirt and has their mouth open. A yellow thought bubble is superimposed over the image, containing text. The background shows dental equipment and a window.

The upper denture does not fall when opening the mouth, I can eat now!

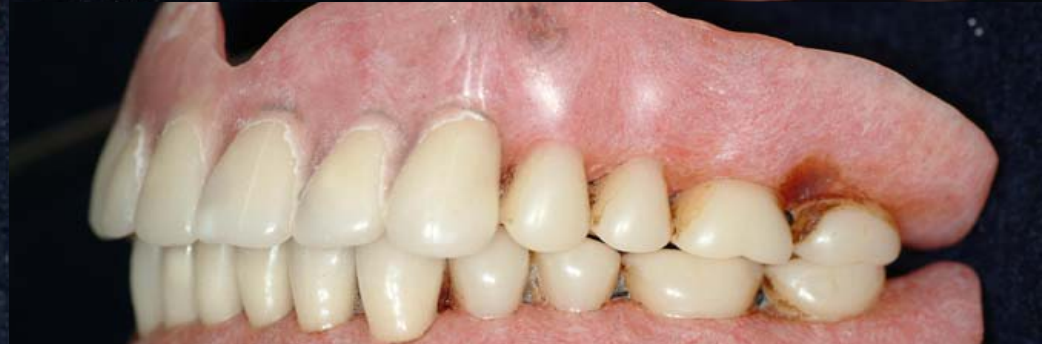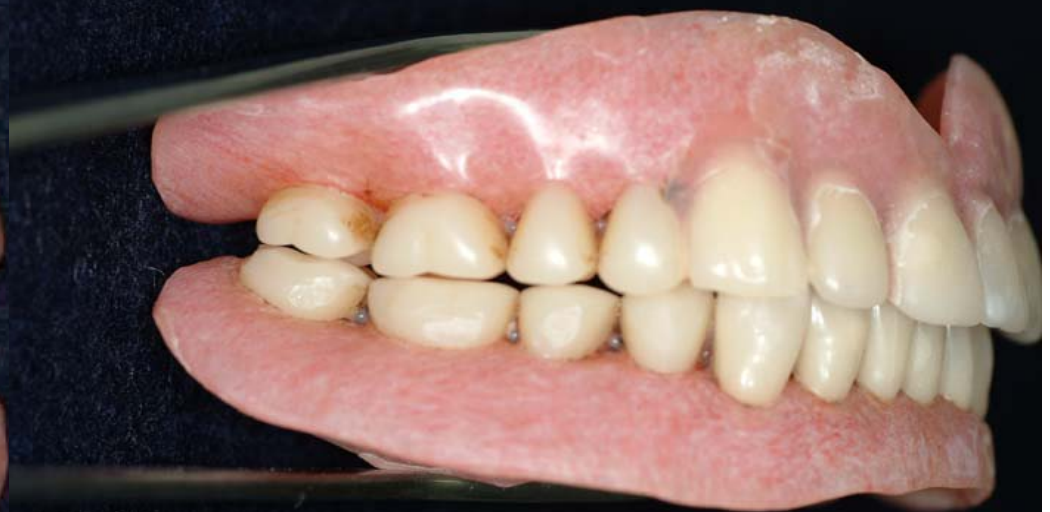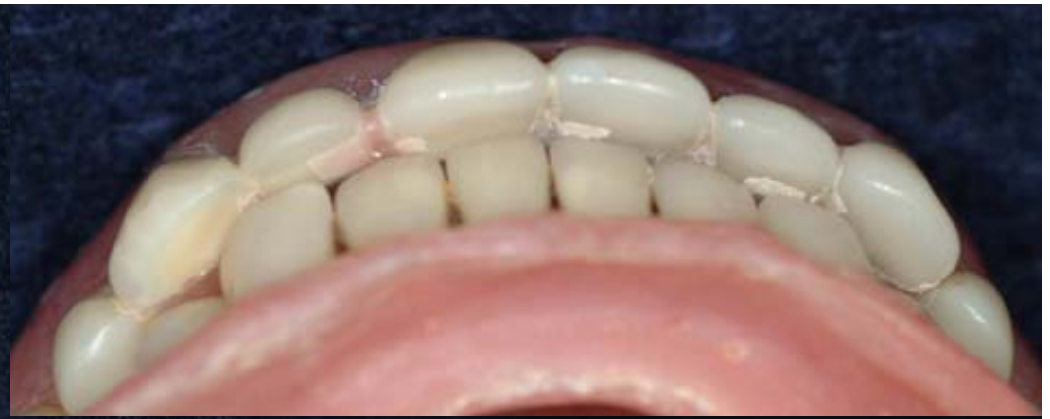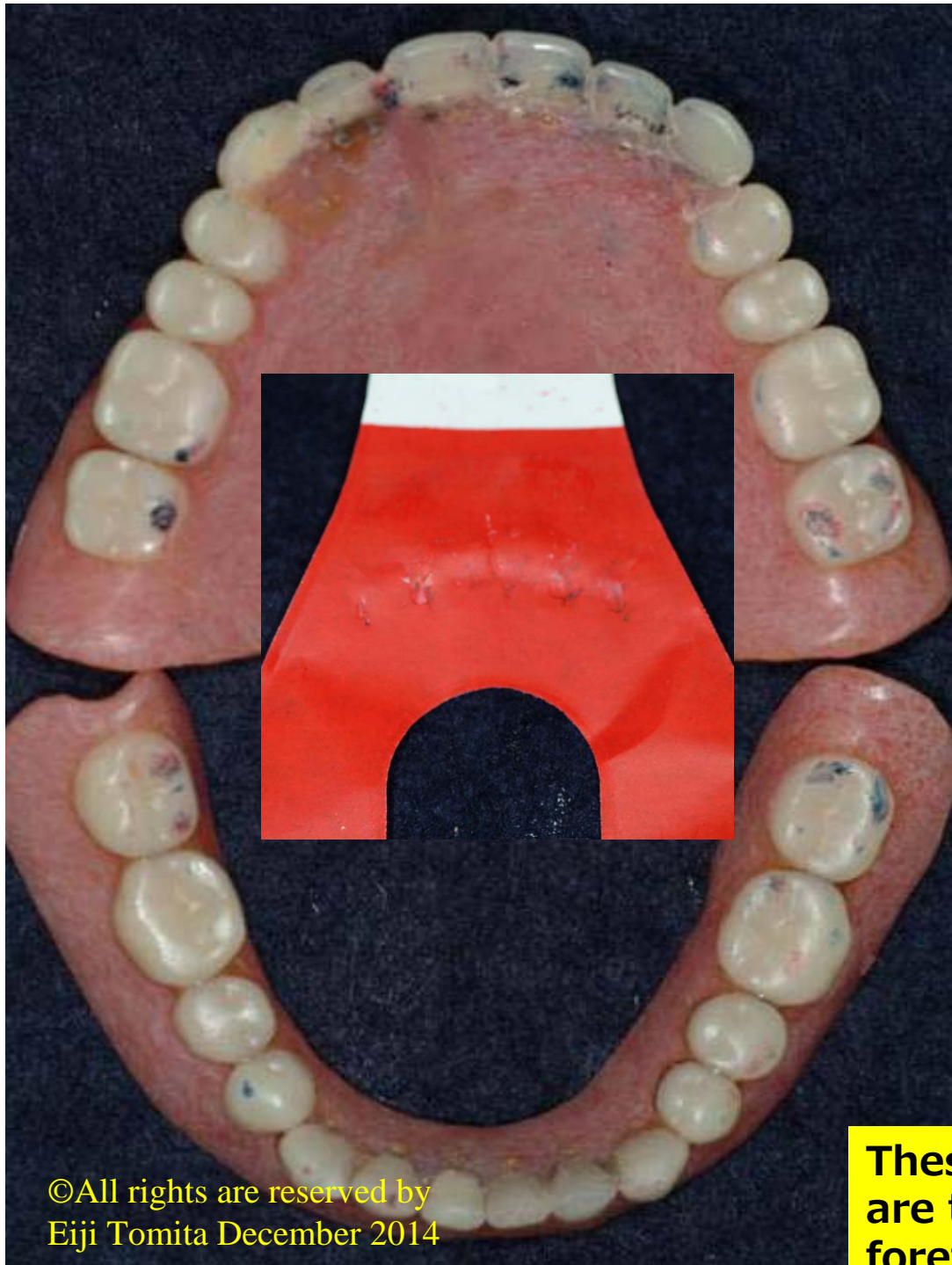©All rights are reserved by
Eiji Tomita December 2014



©All rights are reserved by
Eiji Tomita December 2014

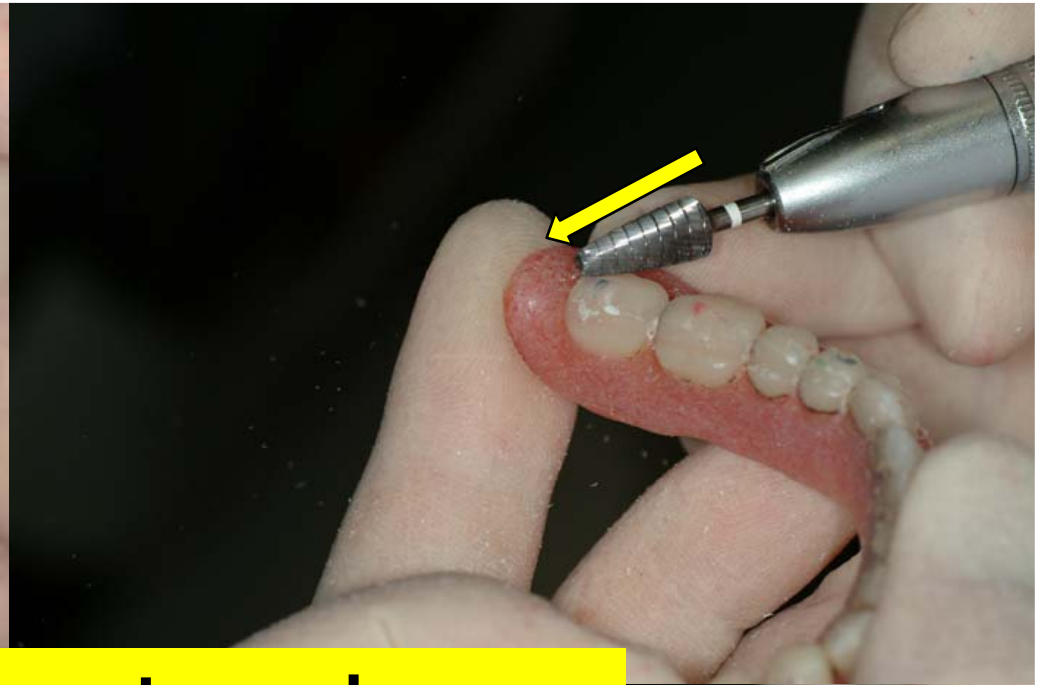
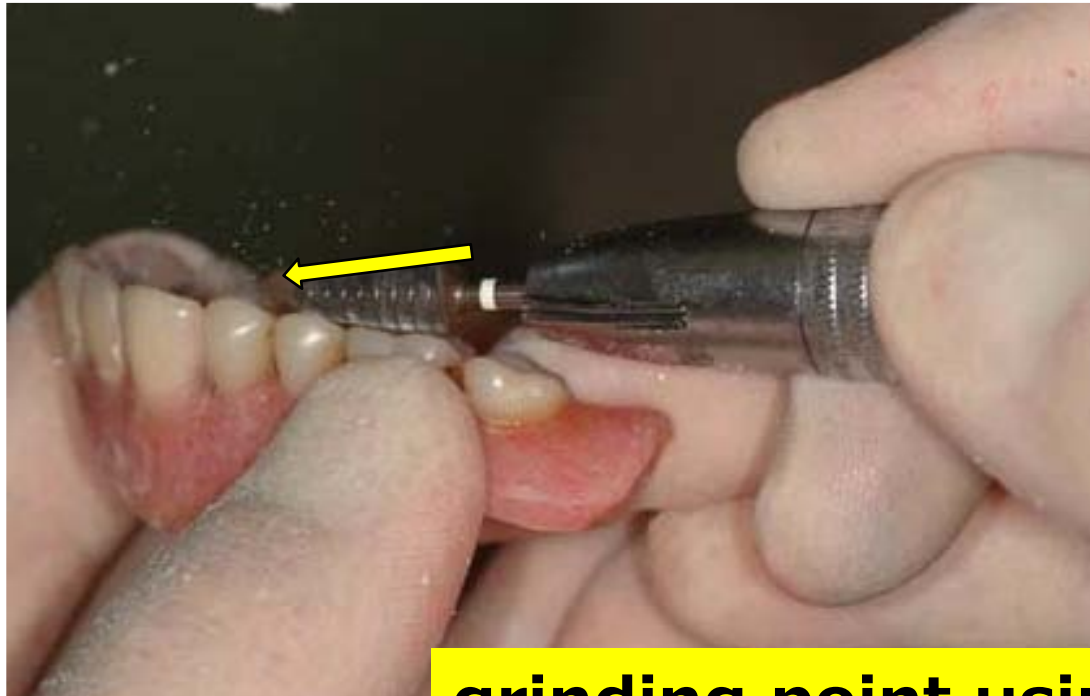
©All rights are reserved by
Eiji Tomita December 2014

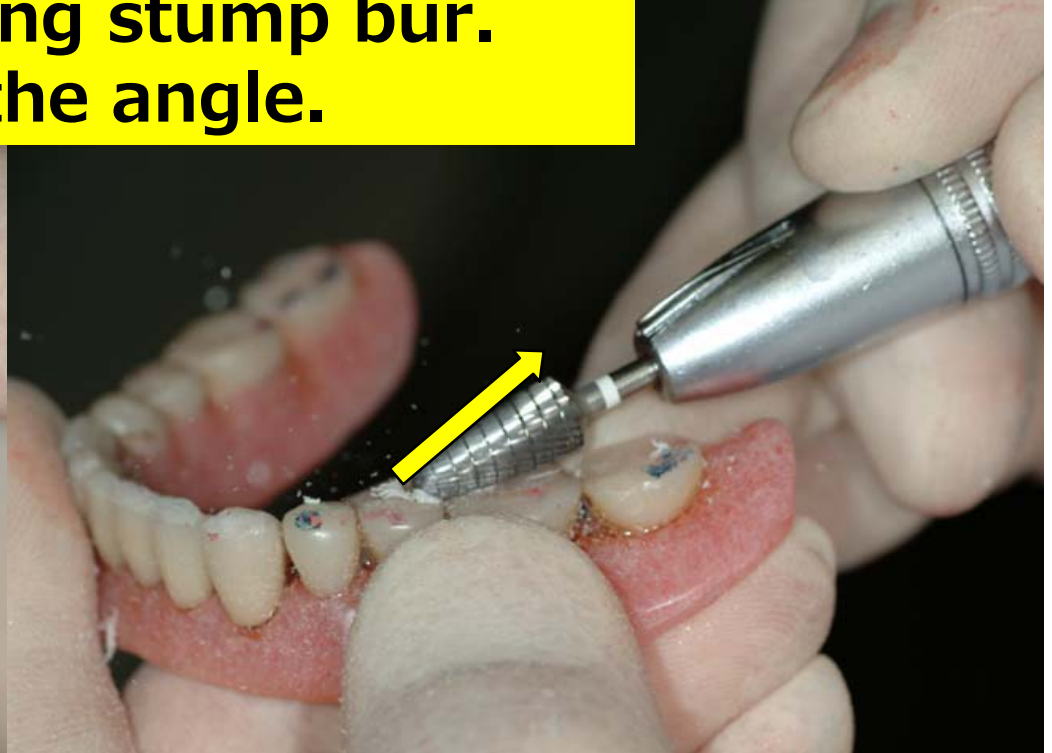
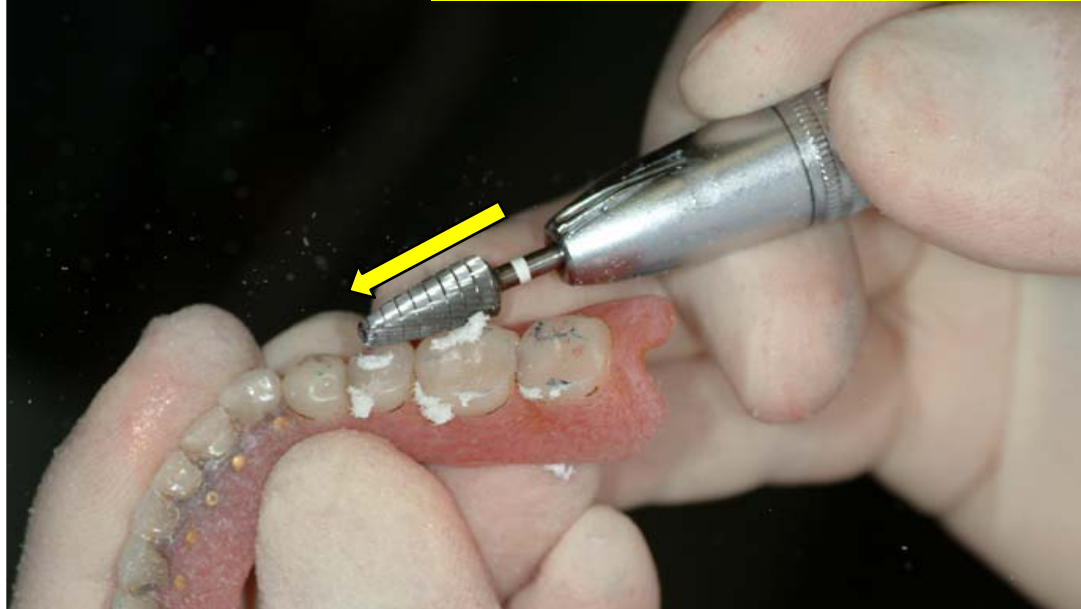
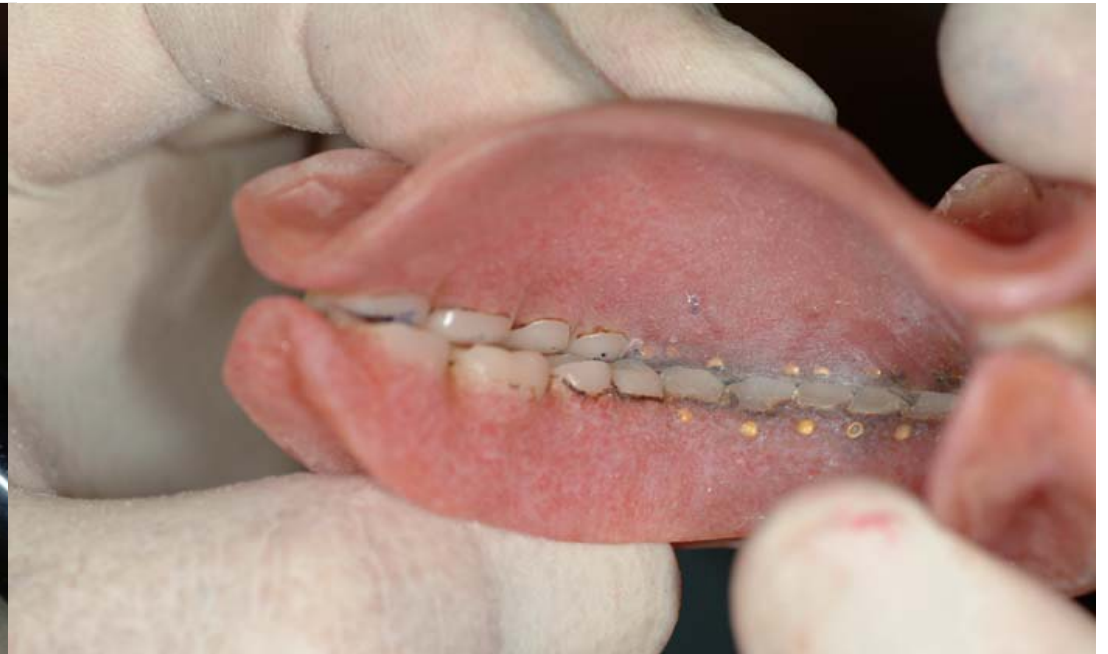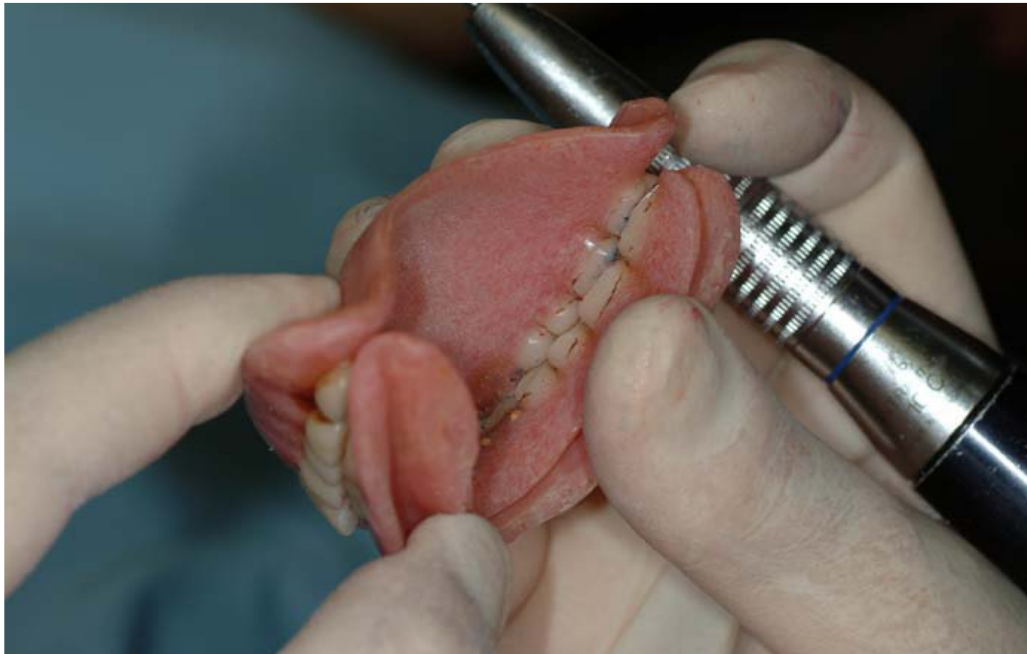©All rights are reserved by
Eiji Tomita December 2014

These pictures are taken at a seminar. They are the denture of a patient whose only foretooth hit when biting

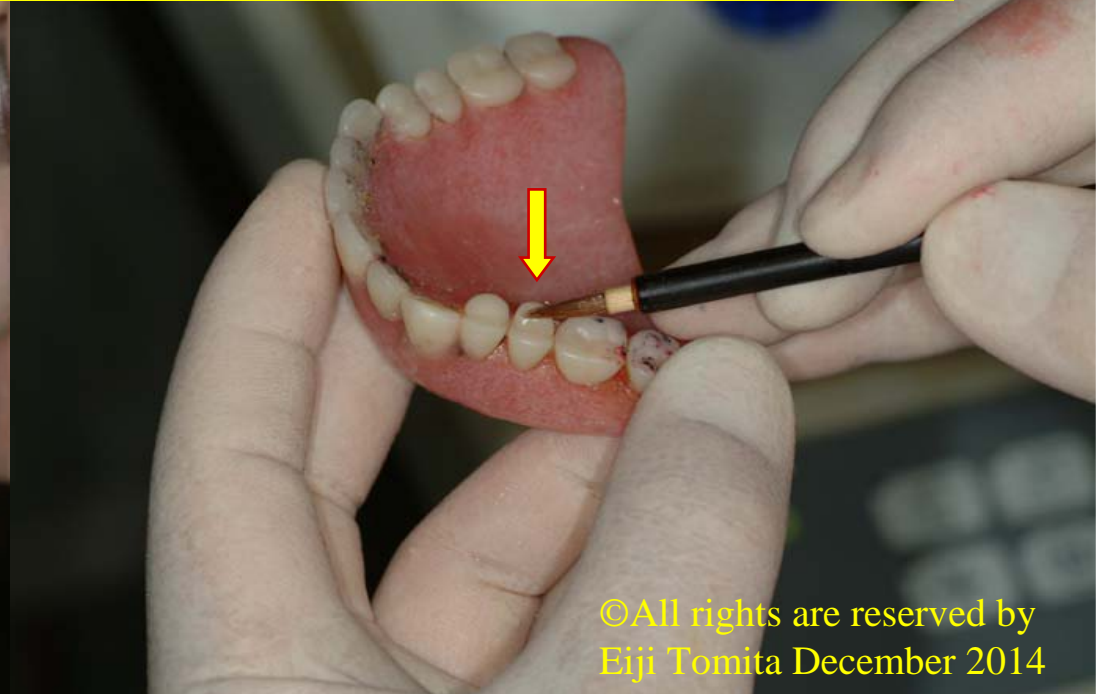
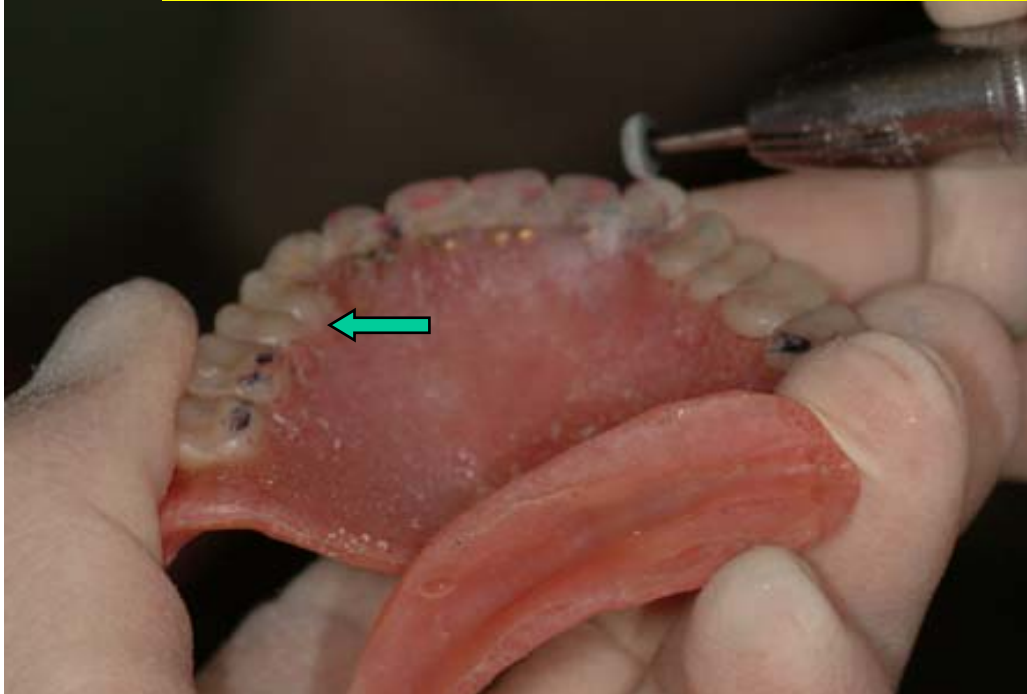


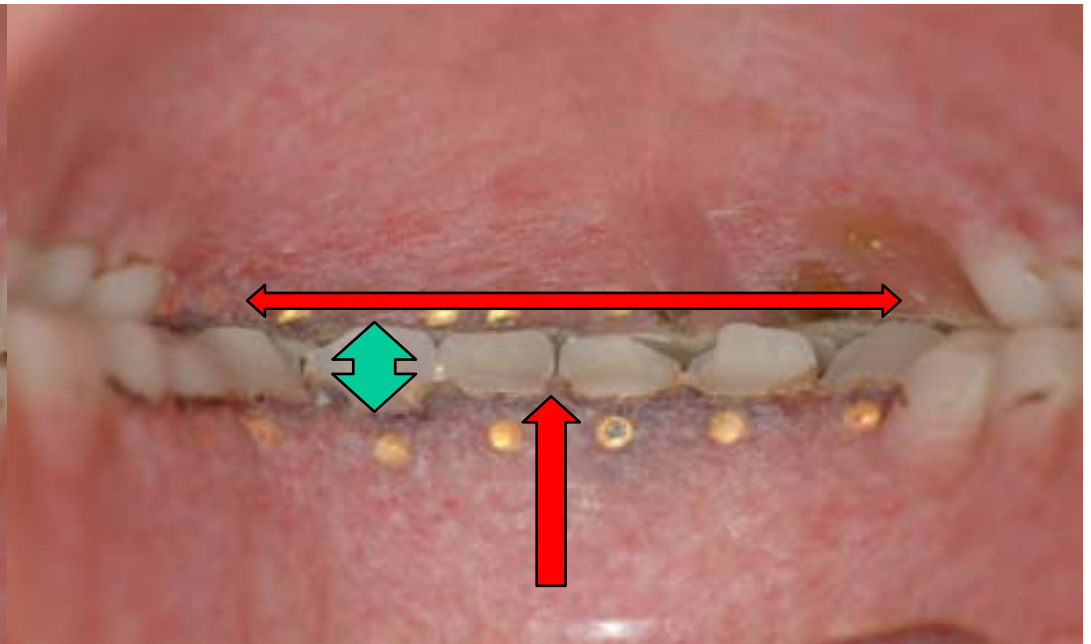
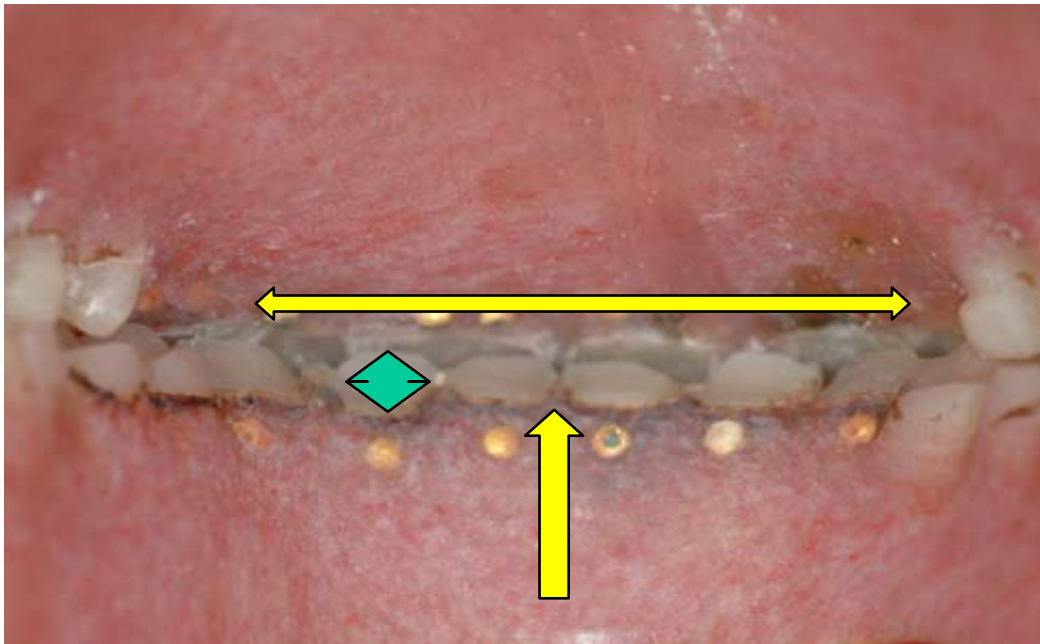
**grinding point using stump bur.
Be careful about the angle.**



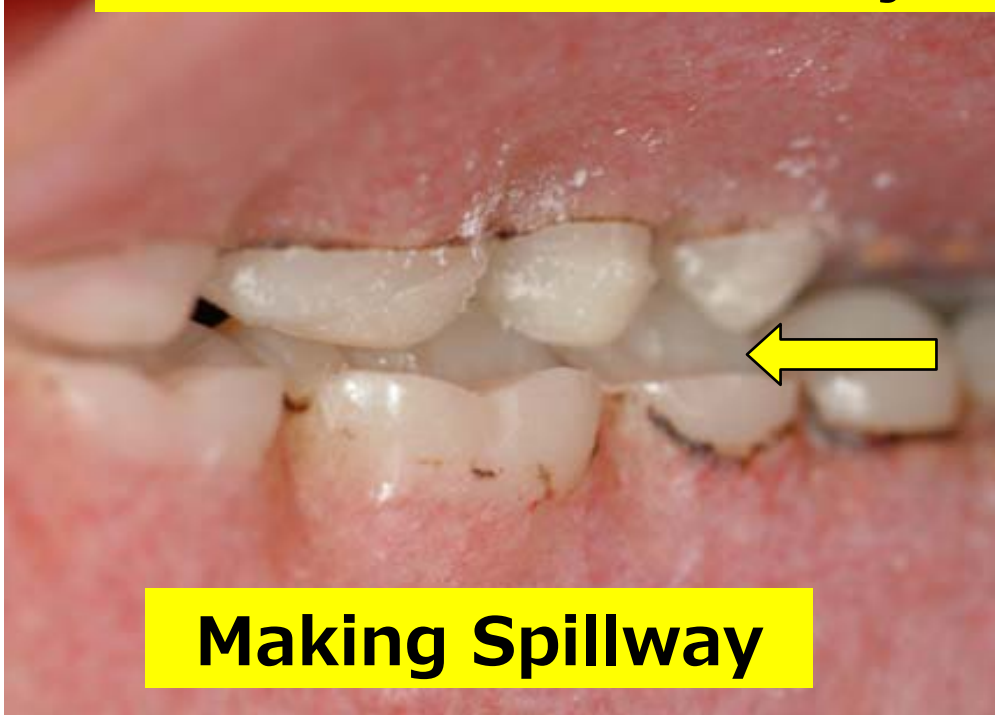

If you have time, add more sokujuu on occlusal surface.

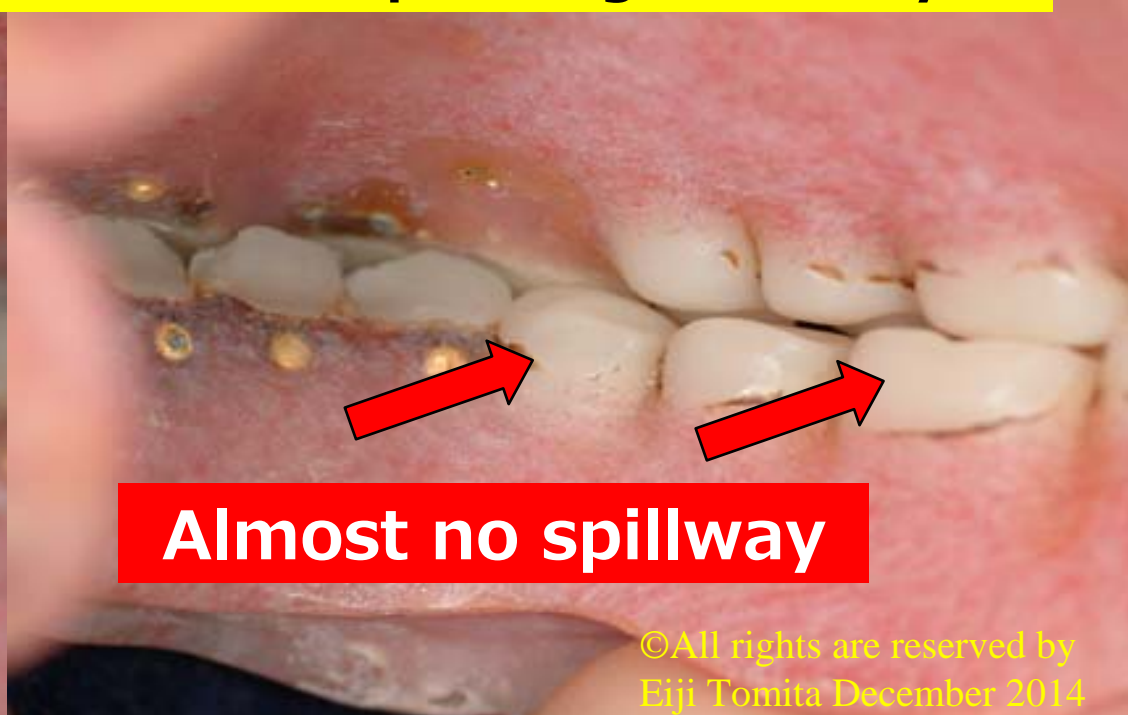



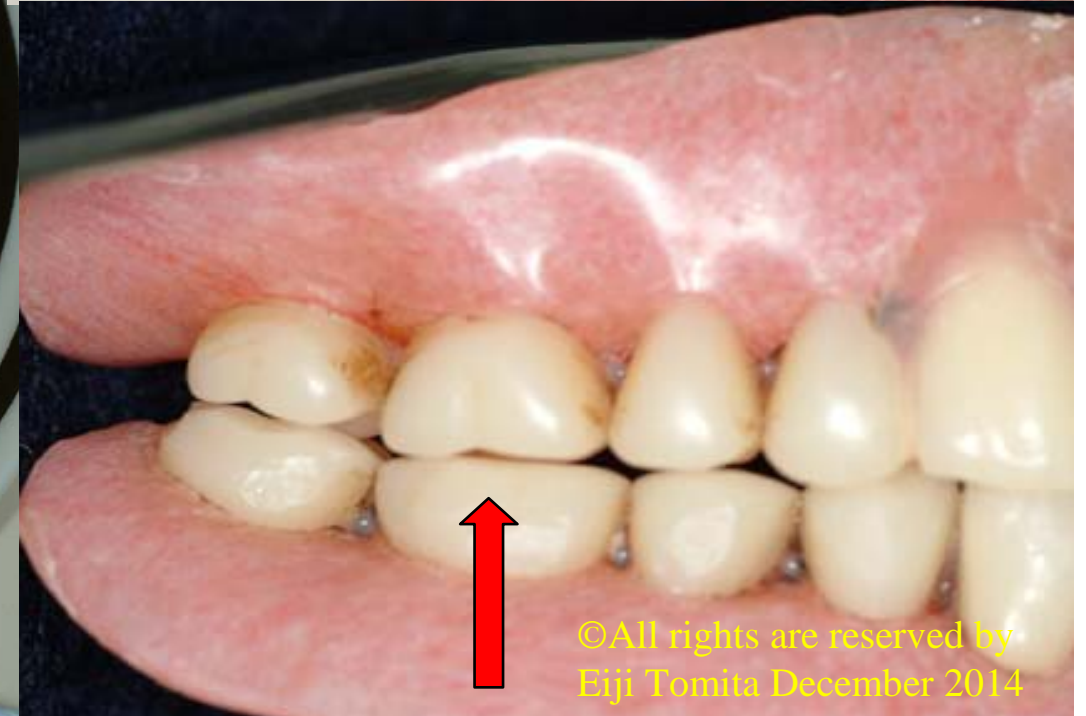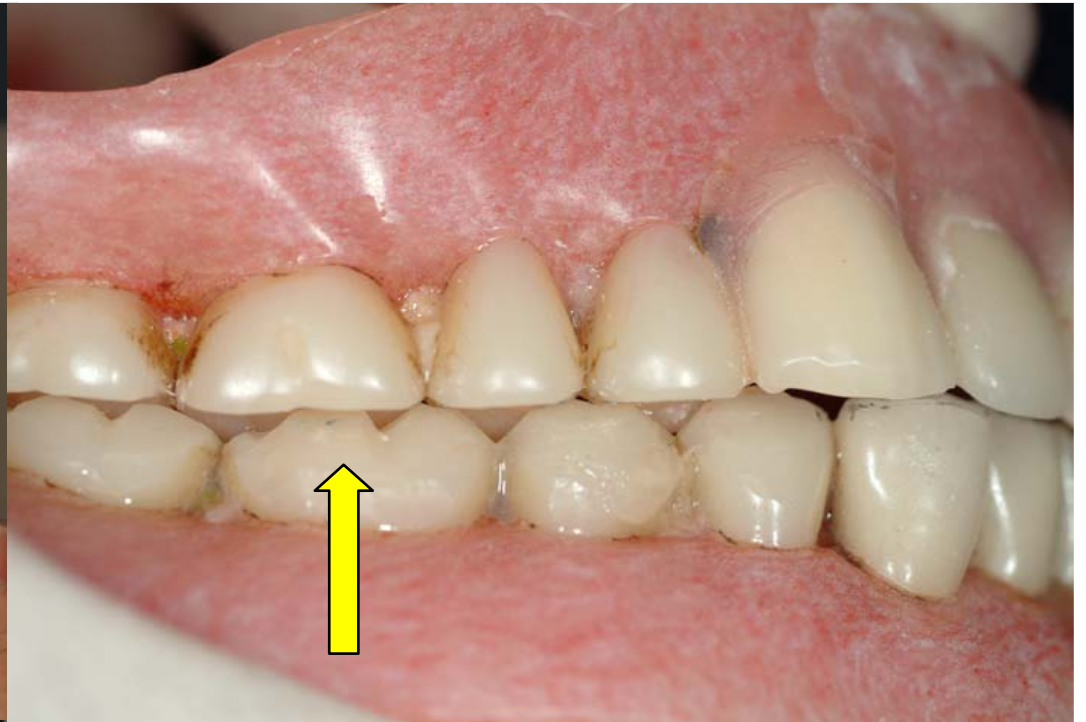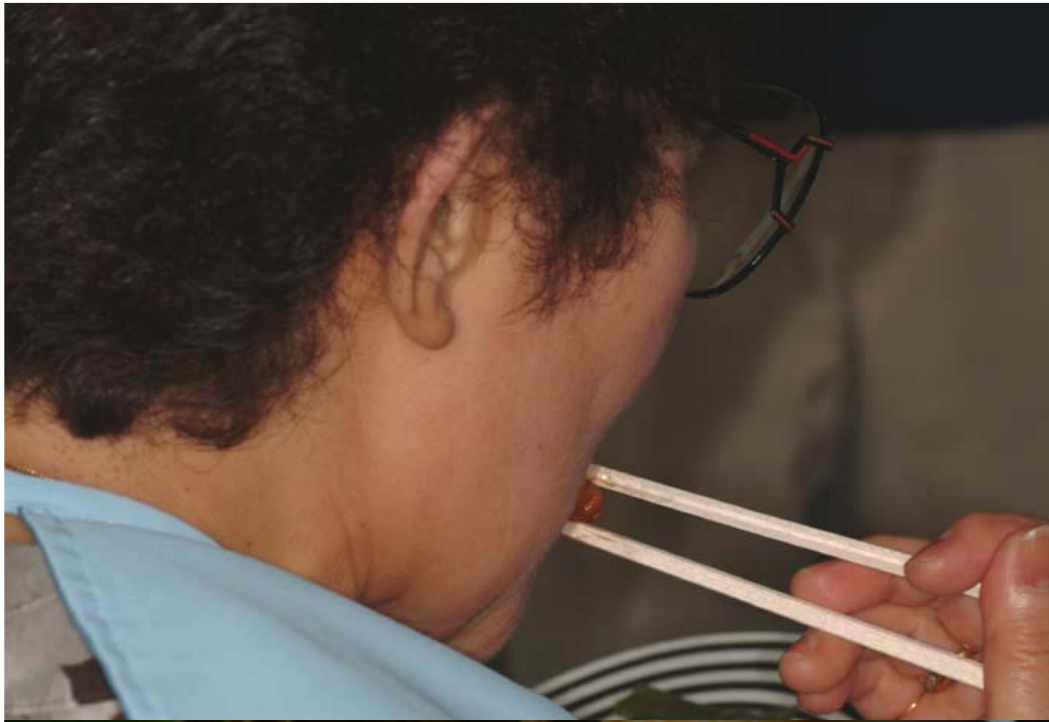Front teeth occlusal adjustment will stop hitting vertically



Making Spillway

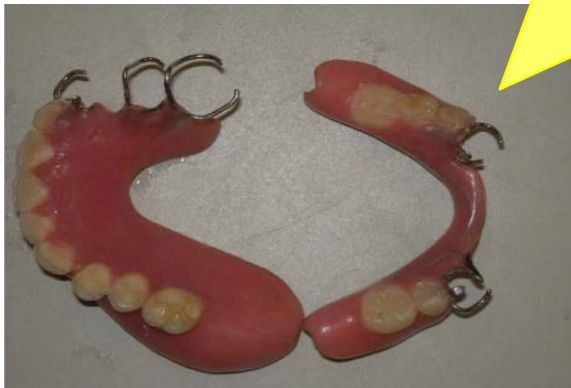

Almost no spillway

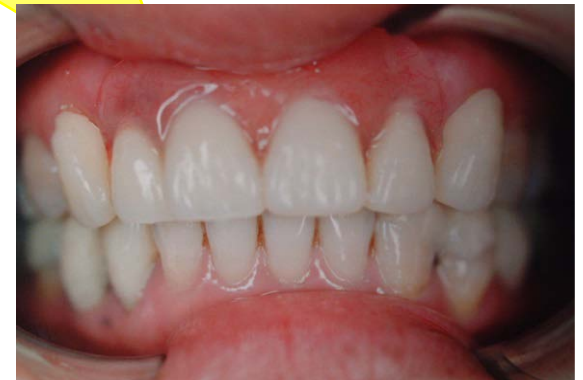

©All rights are reserved by
Eiji Tomita December 2014

Non-clasp denture



©All rights are reserved by
Eiji Tomita December 2014

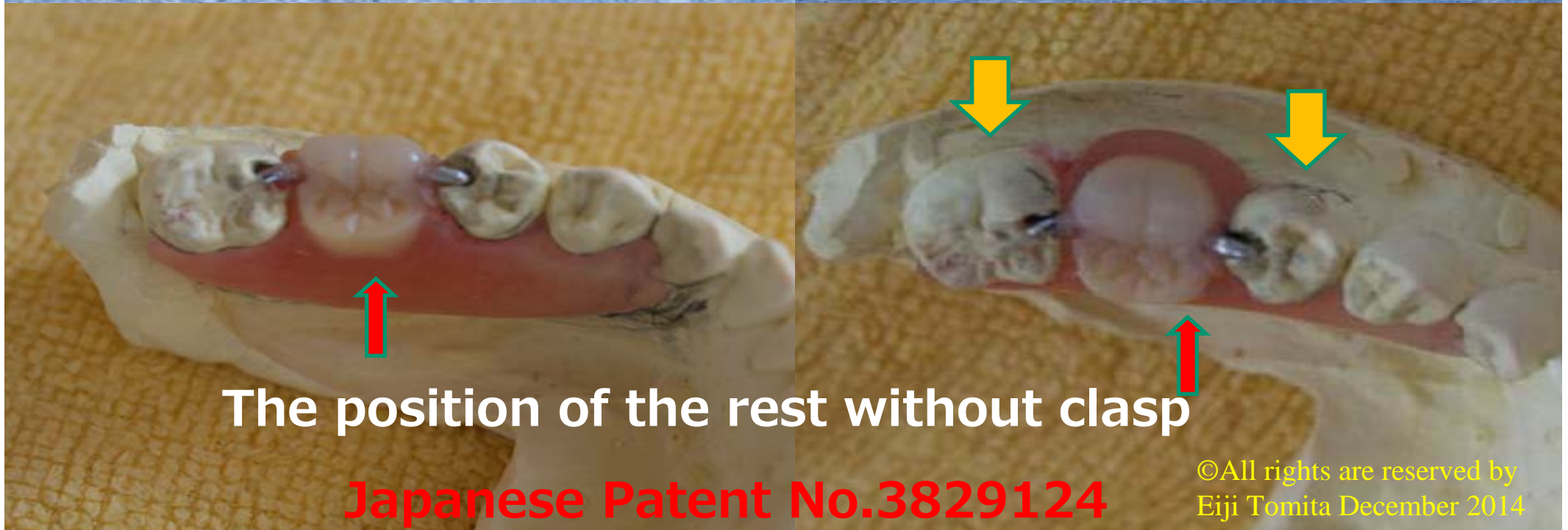

Non-clasp denture

Artificial teeth which brings back your teeth work naturally.

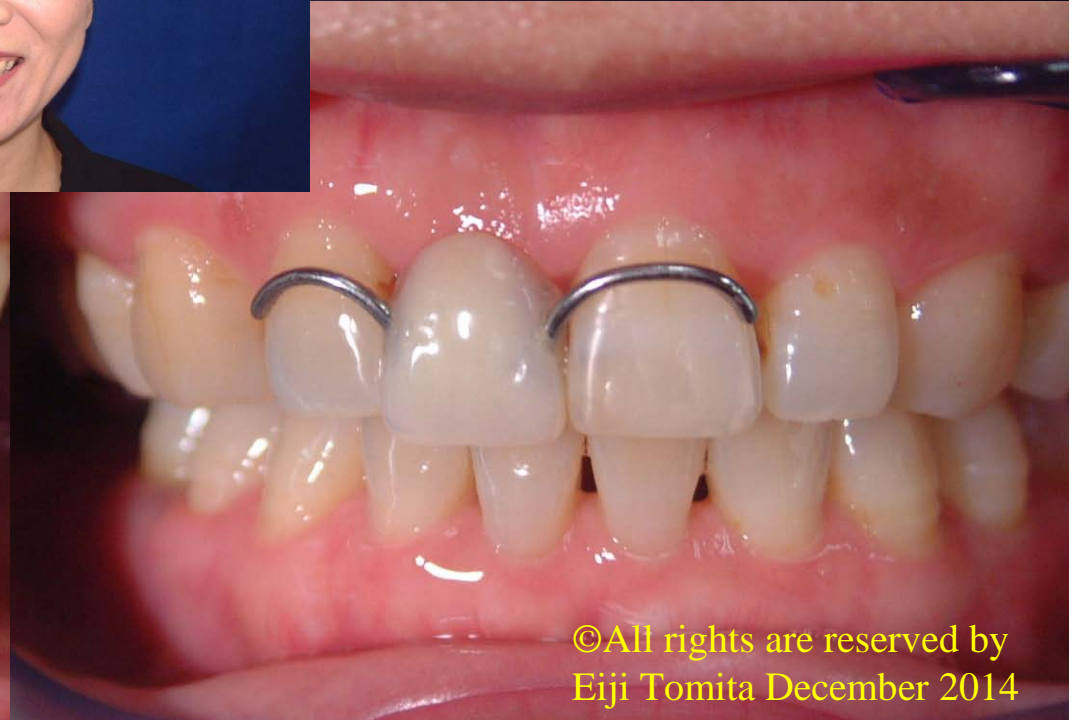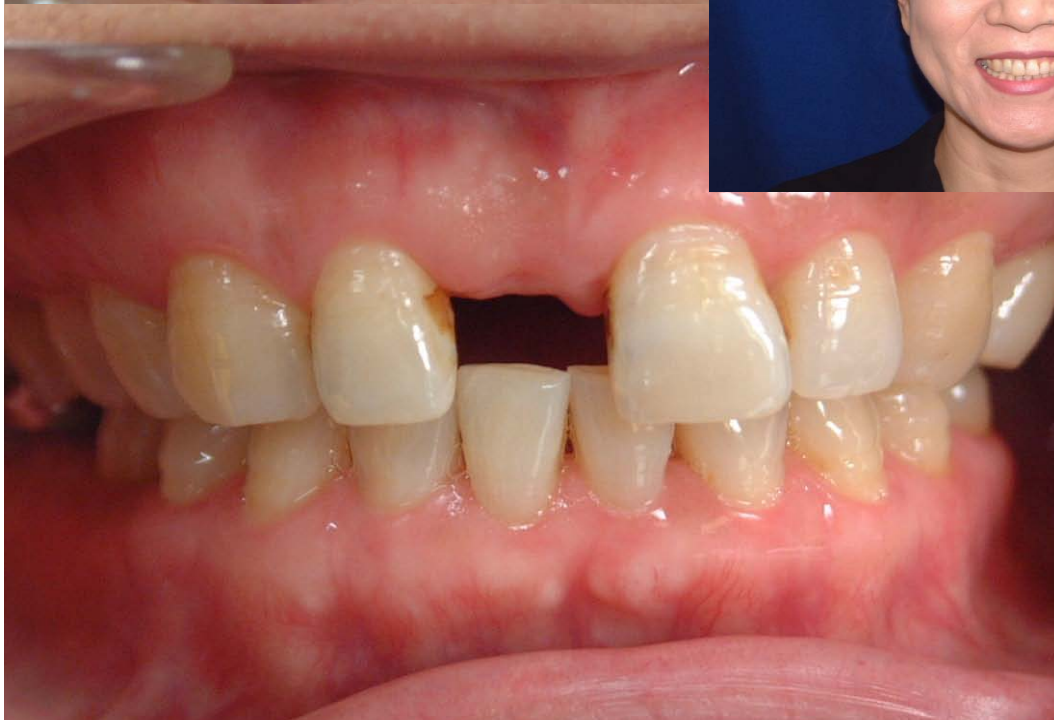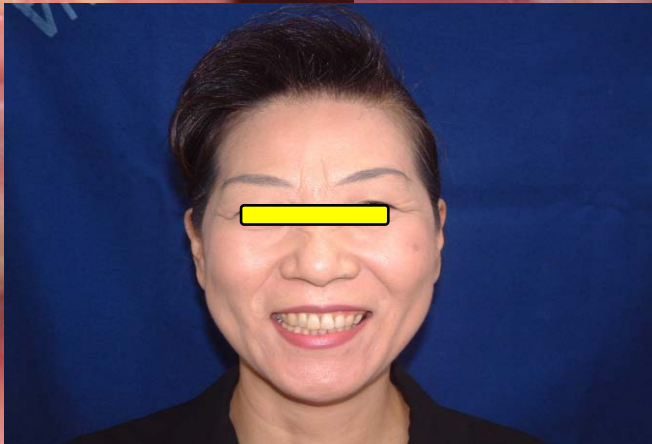
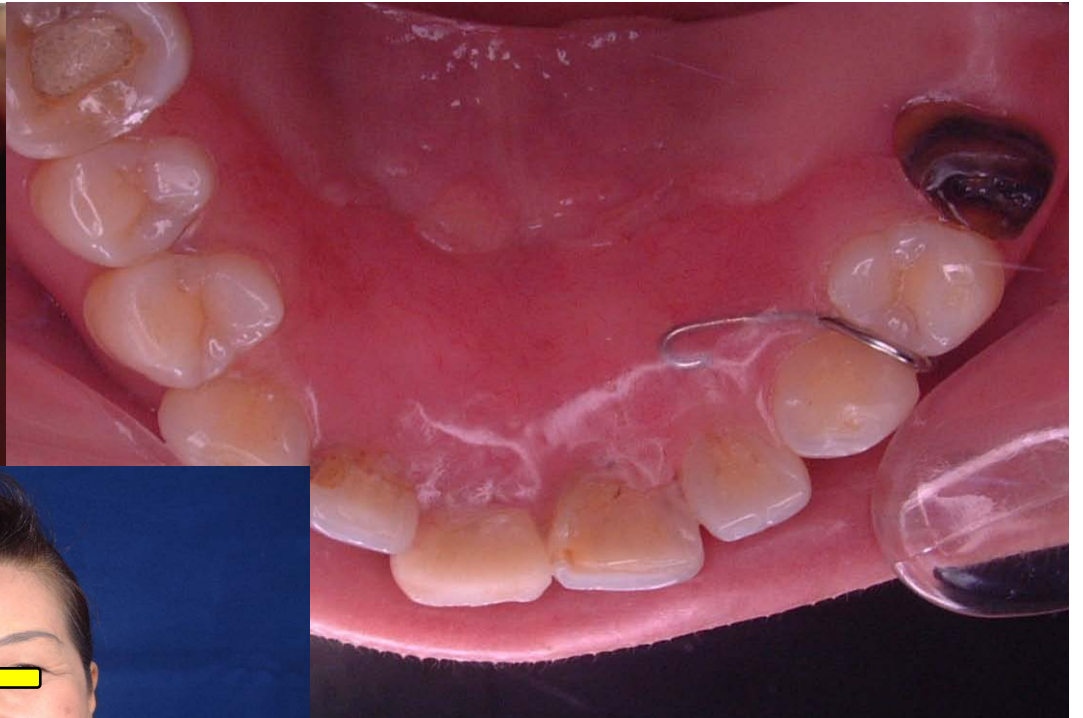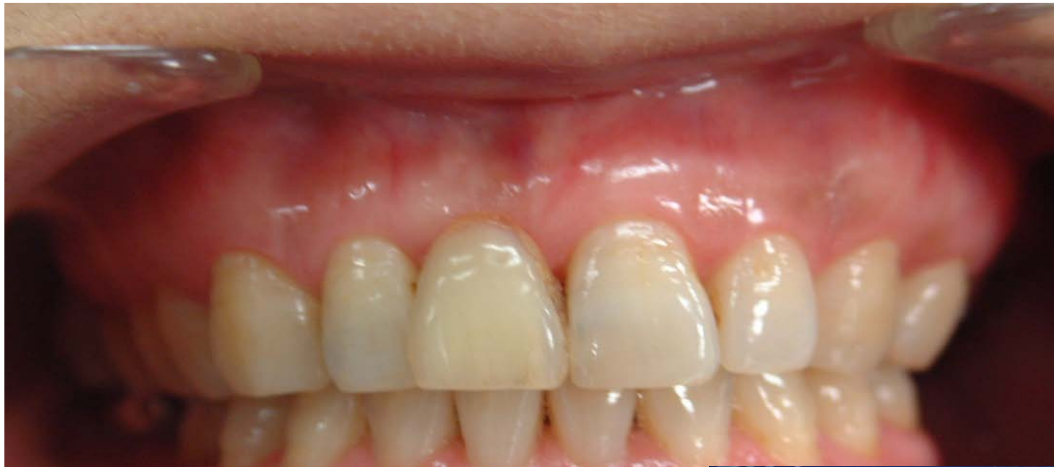L · B · O[®]

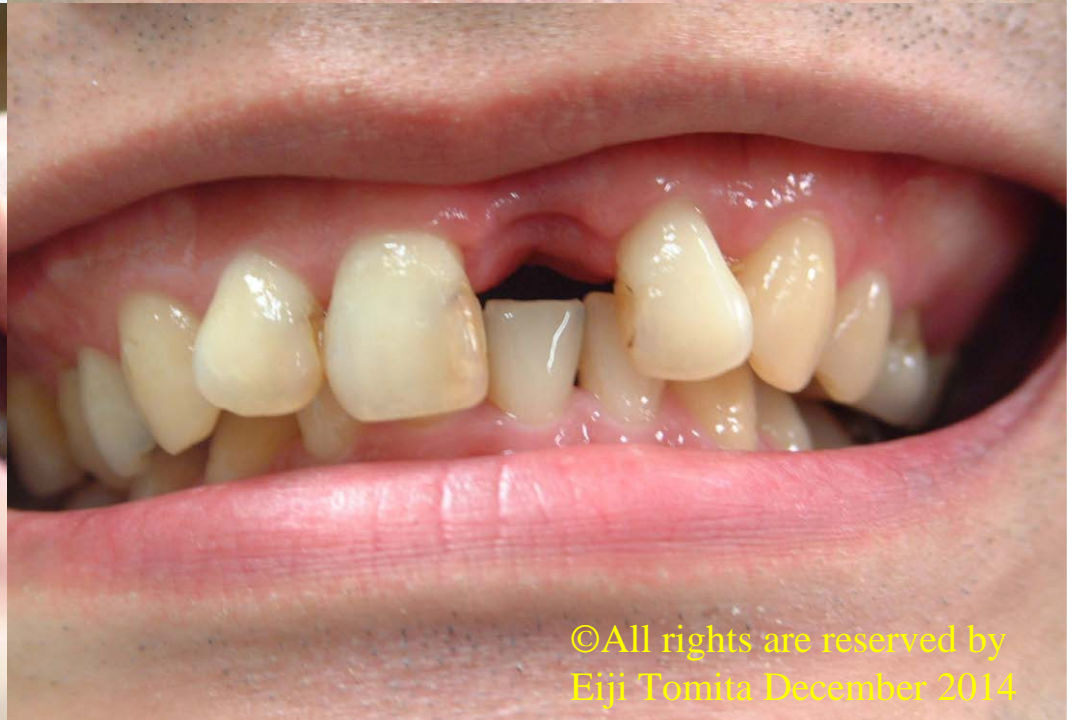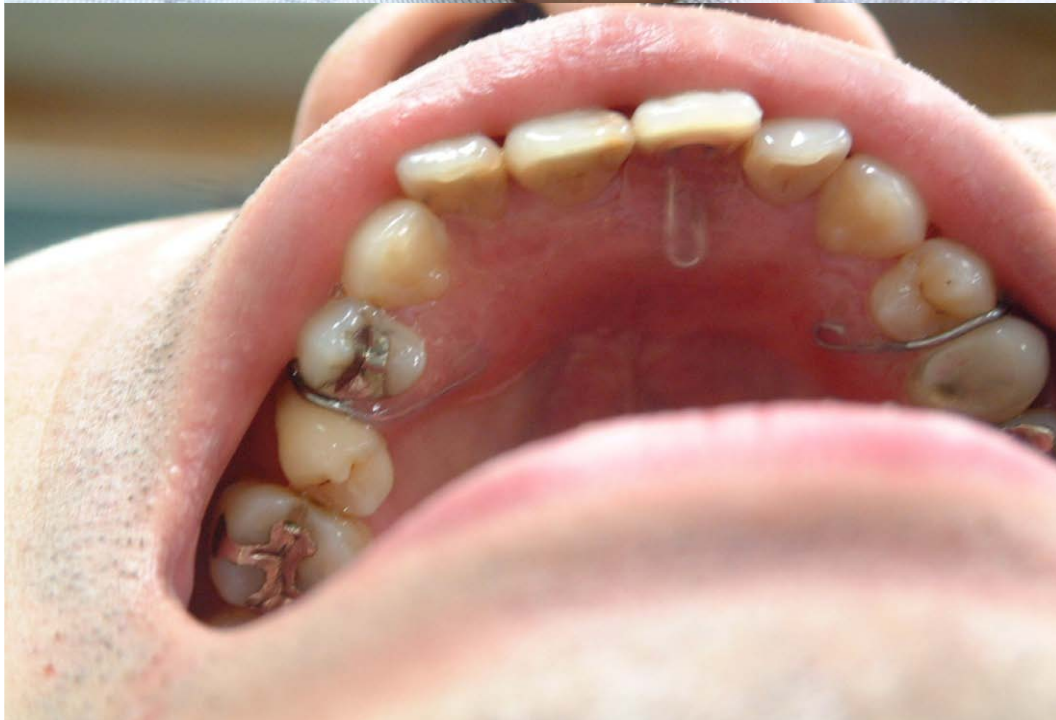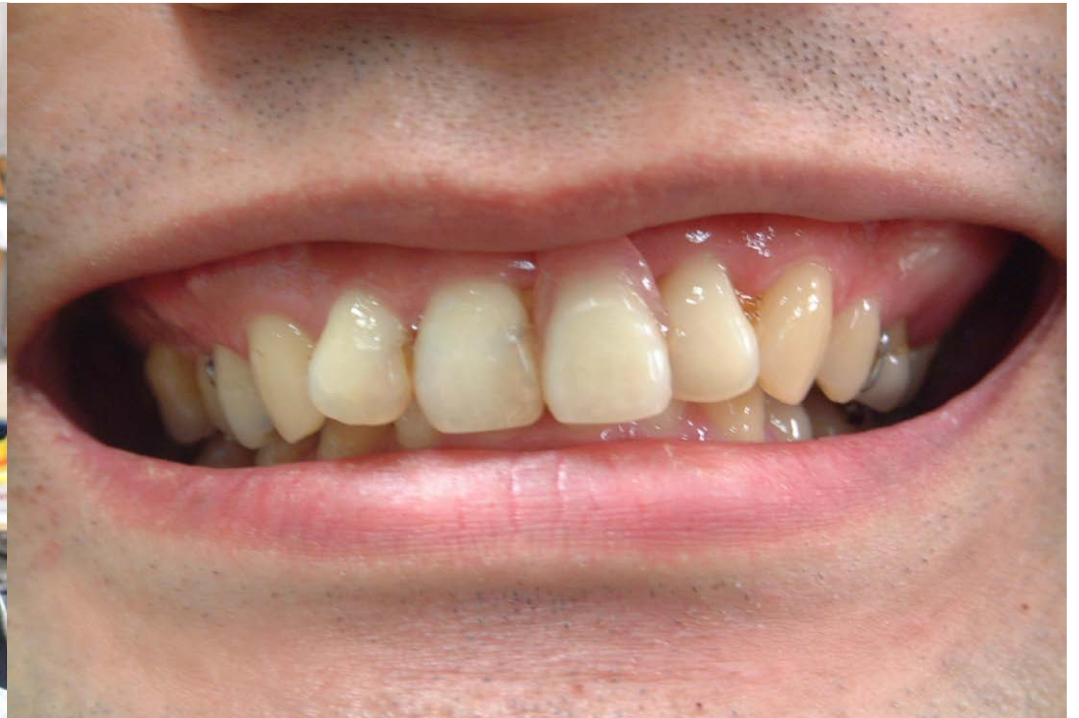**Eat deliciously, your health
starts from one tooth**



Japanese Patent No.3829124

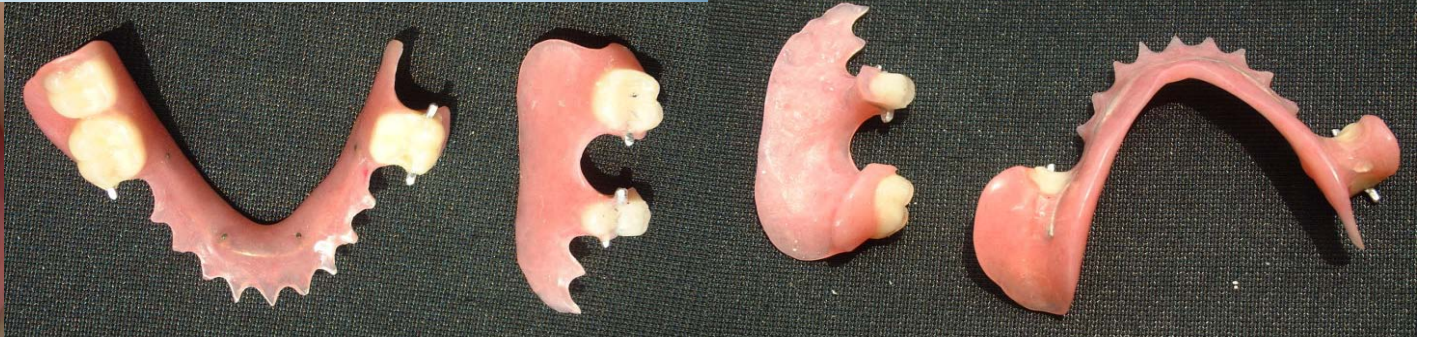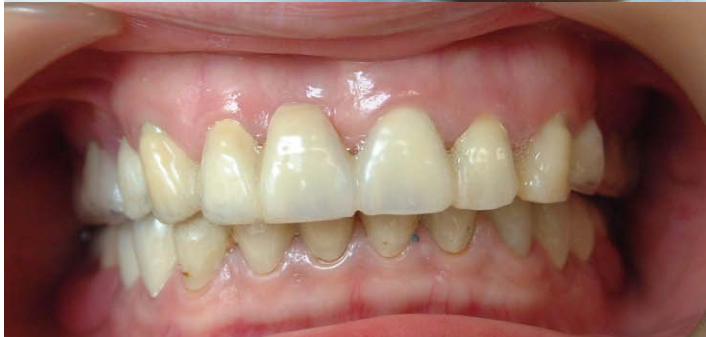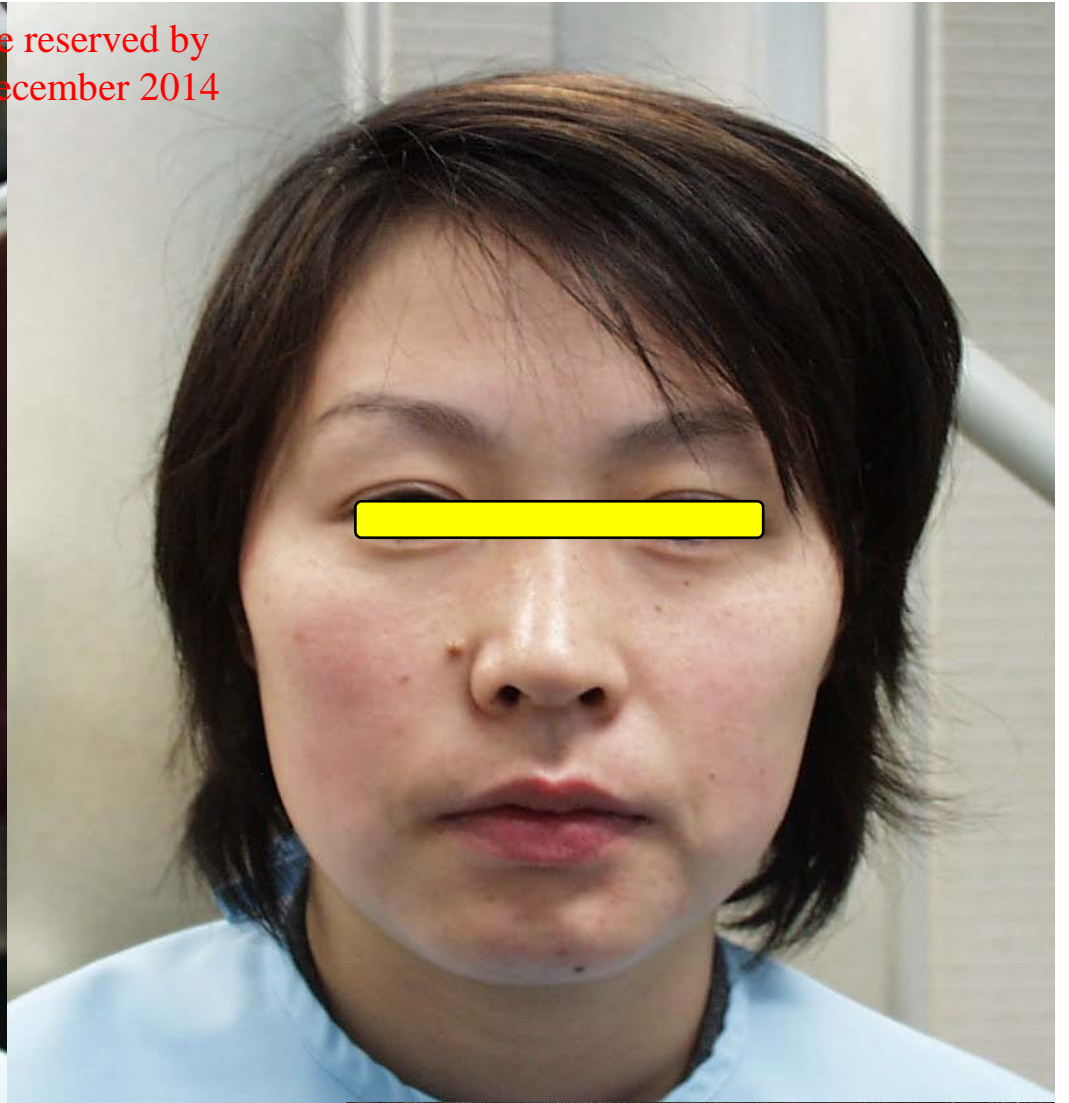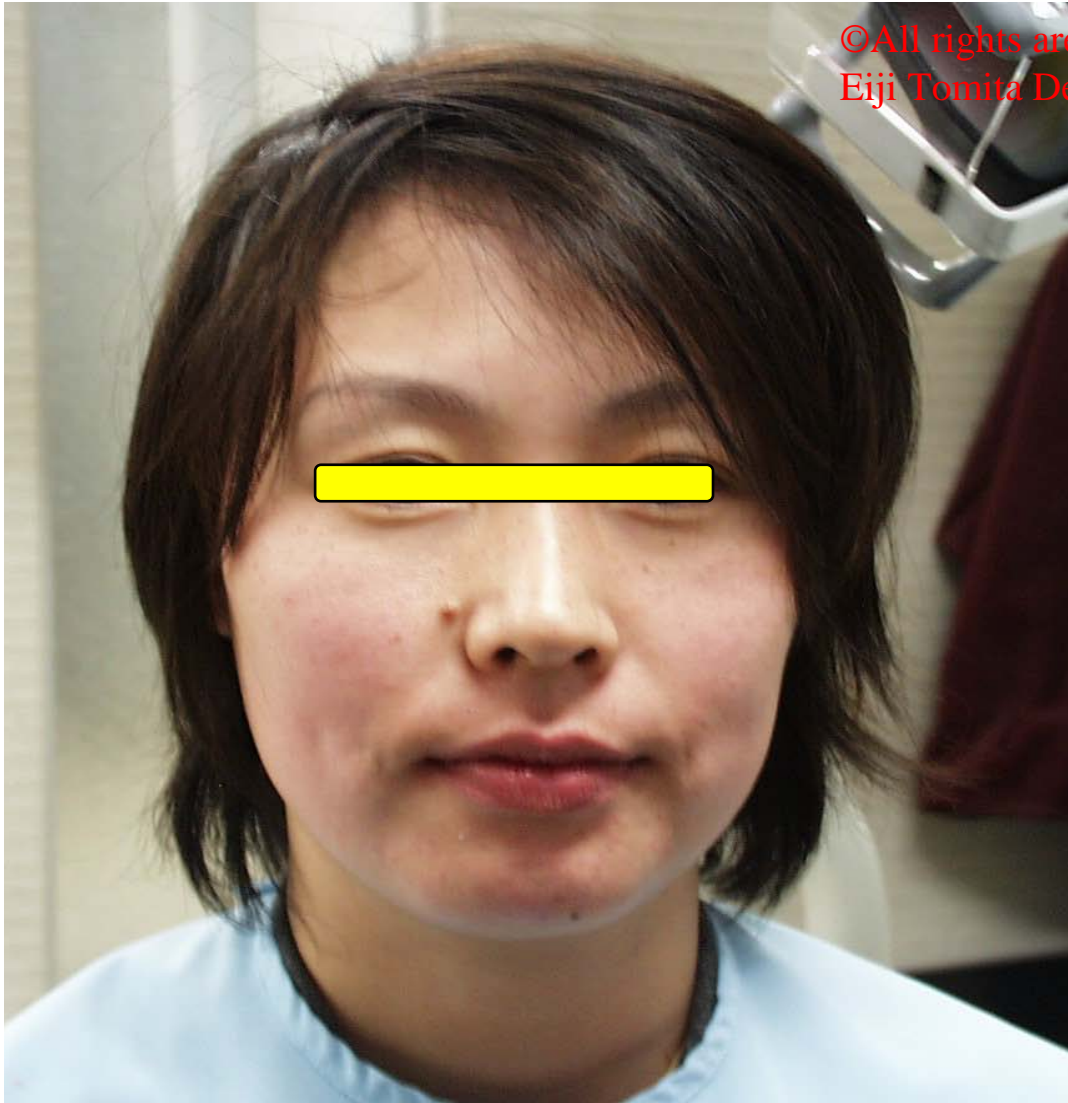
©All rights are reserved by
Eiji Tomita December 2014

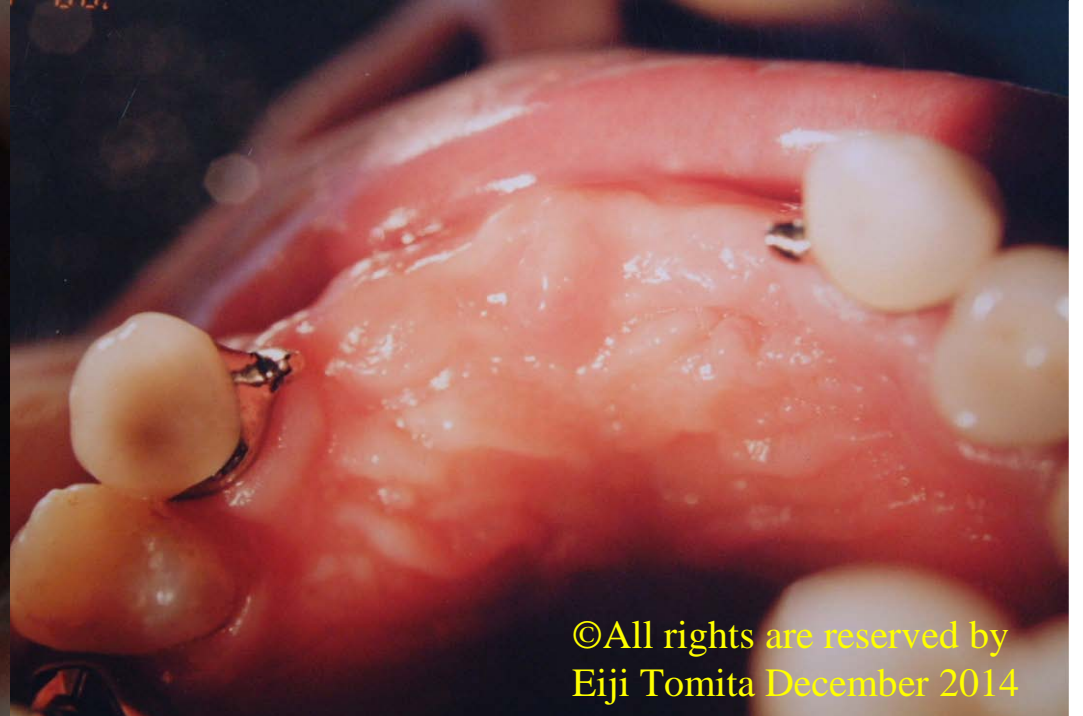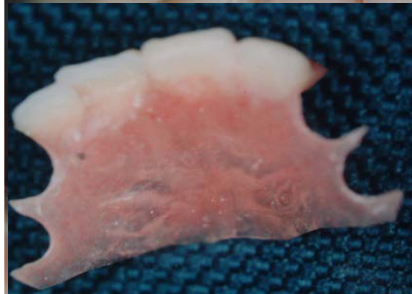
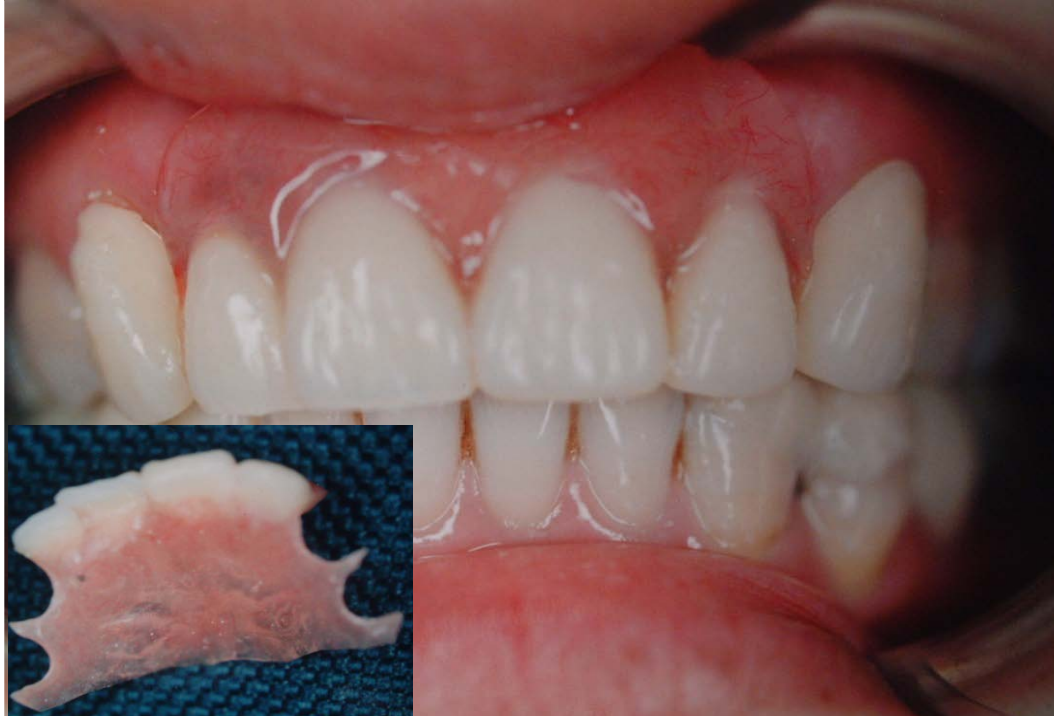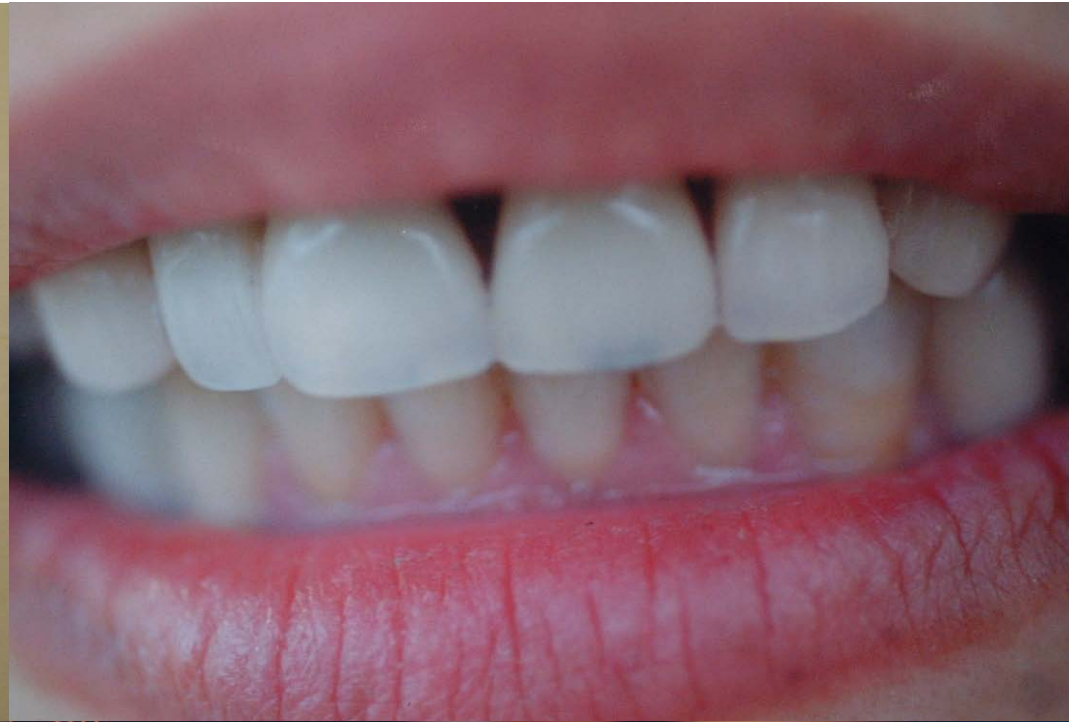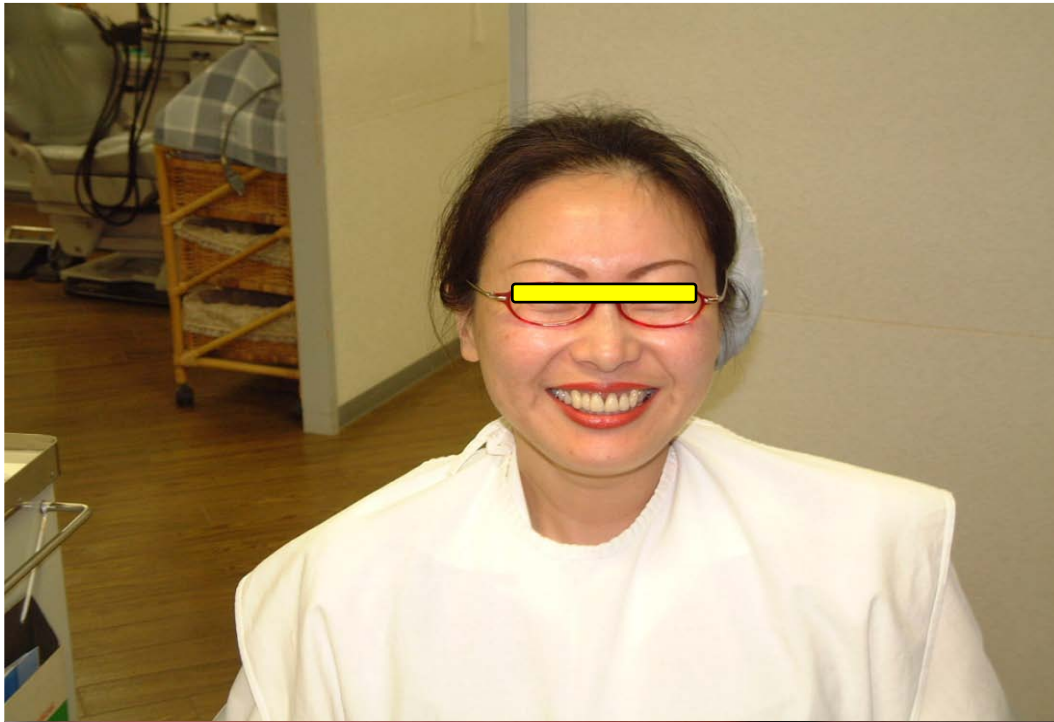




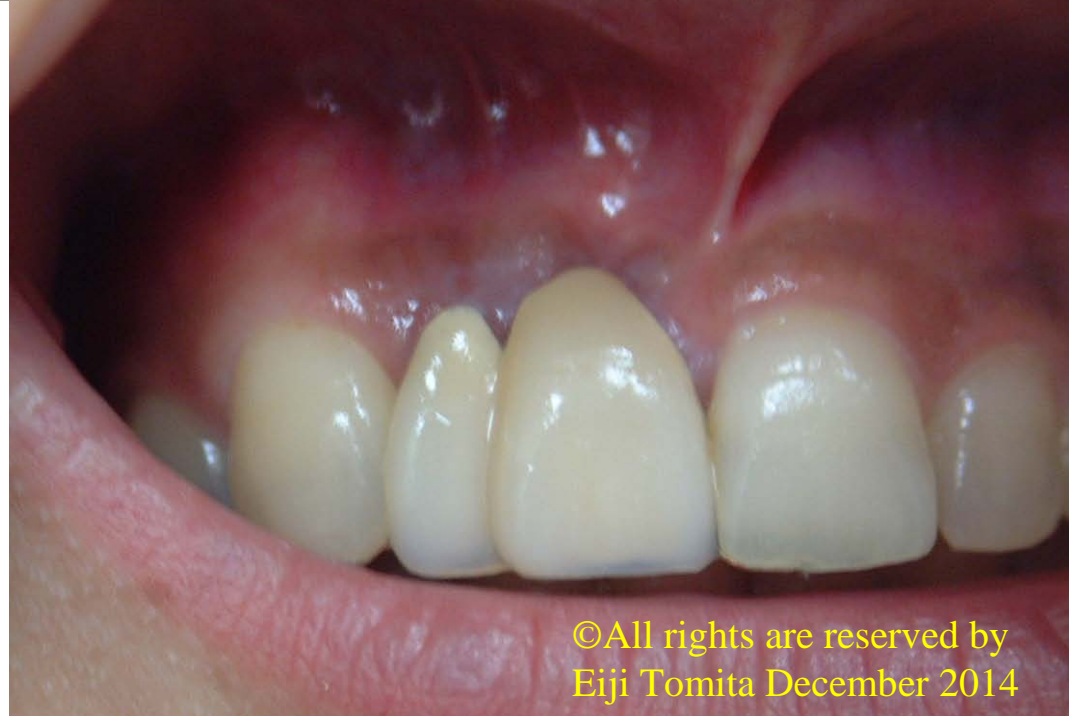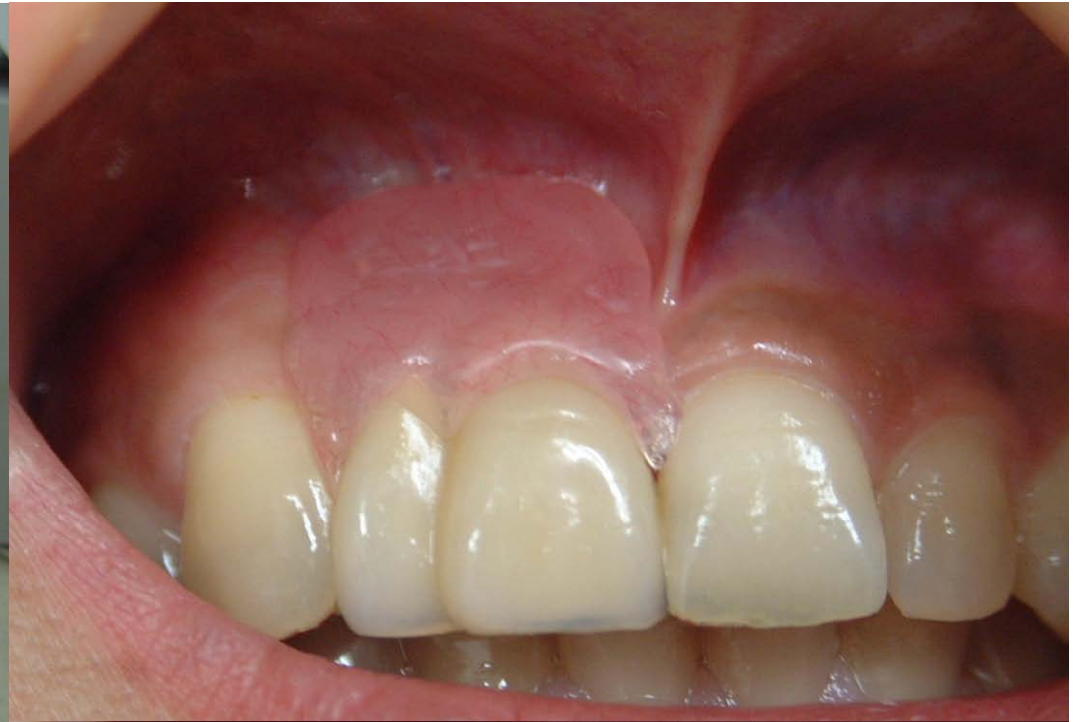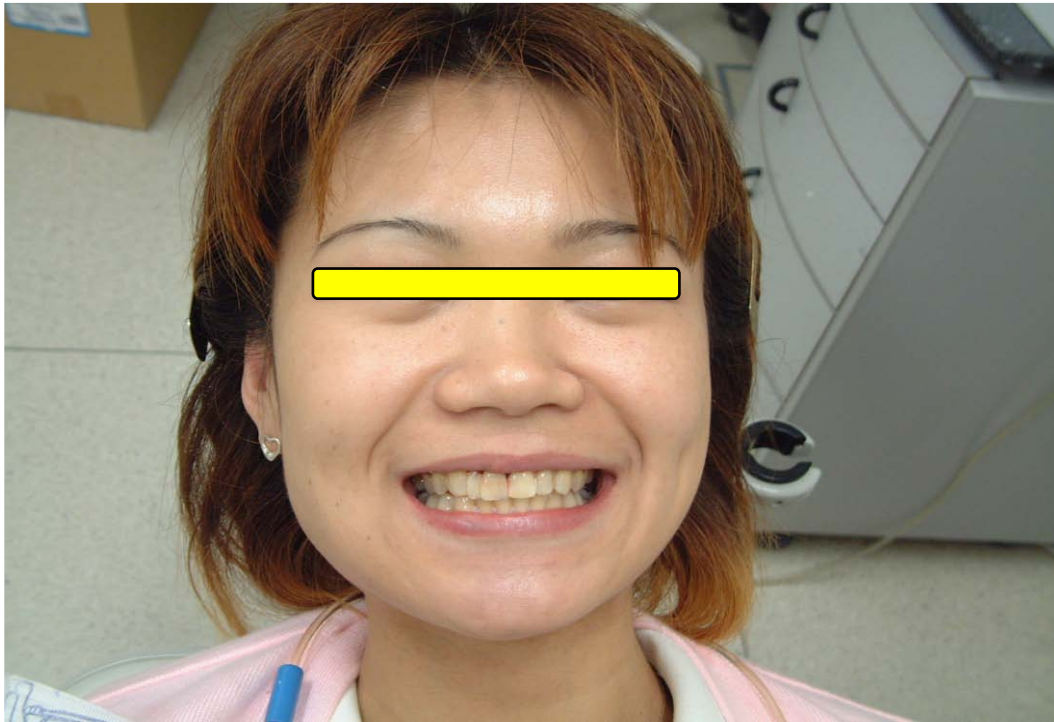
©All rights are reserved by
Eiji Tomita December 2014

©All rights are reserved by
Eiji Tomita December 2014



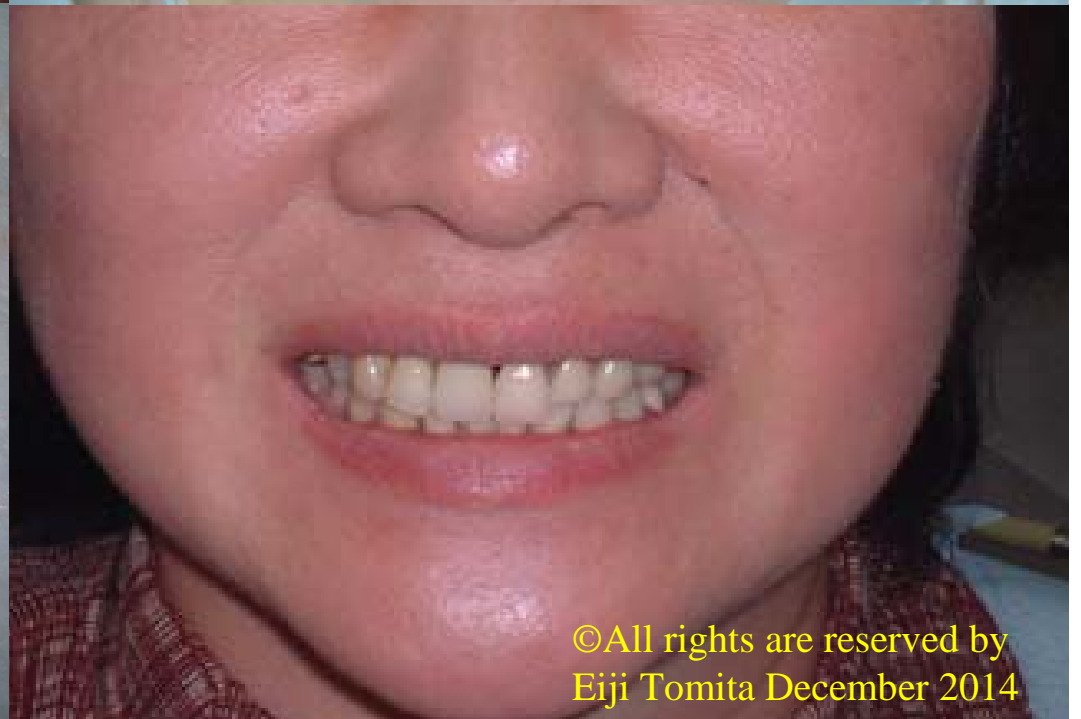
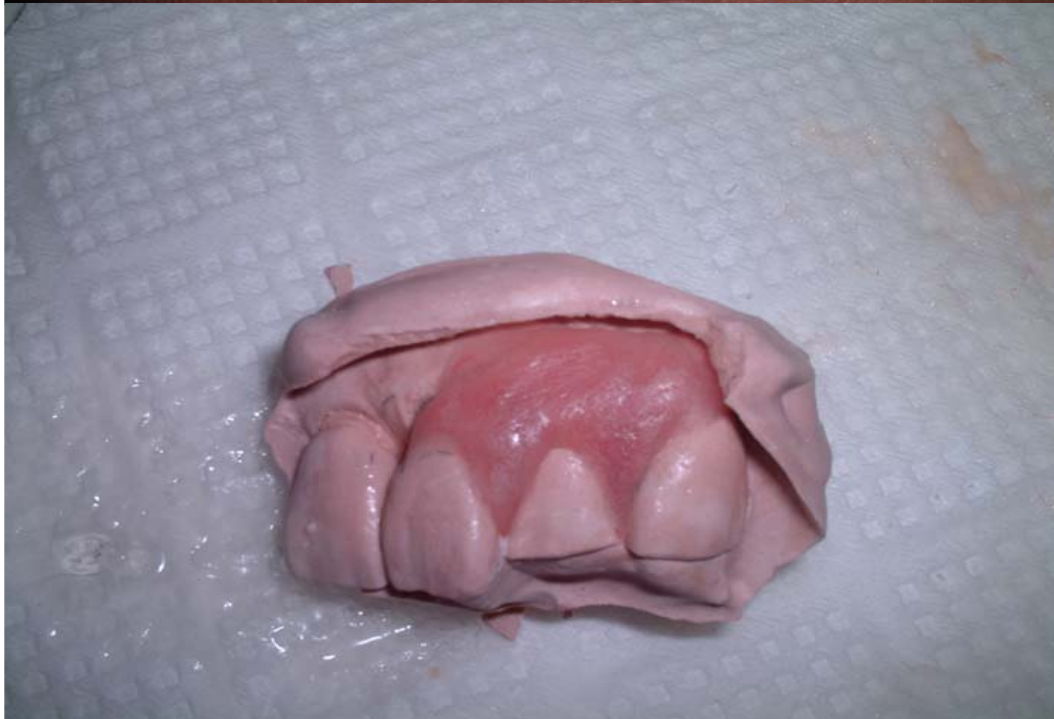
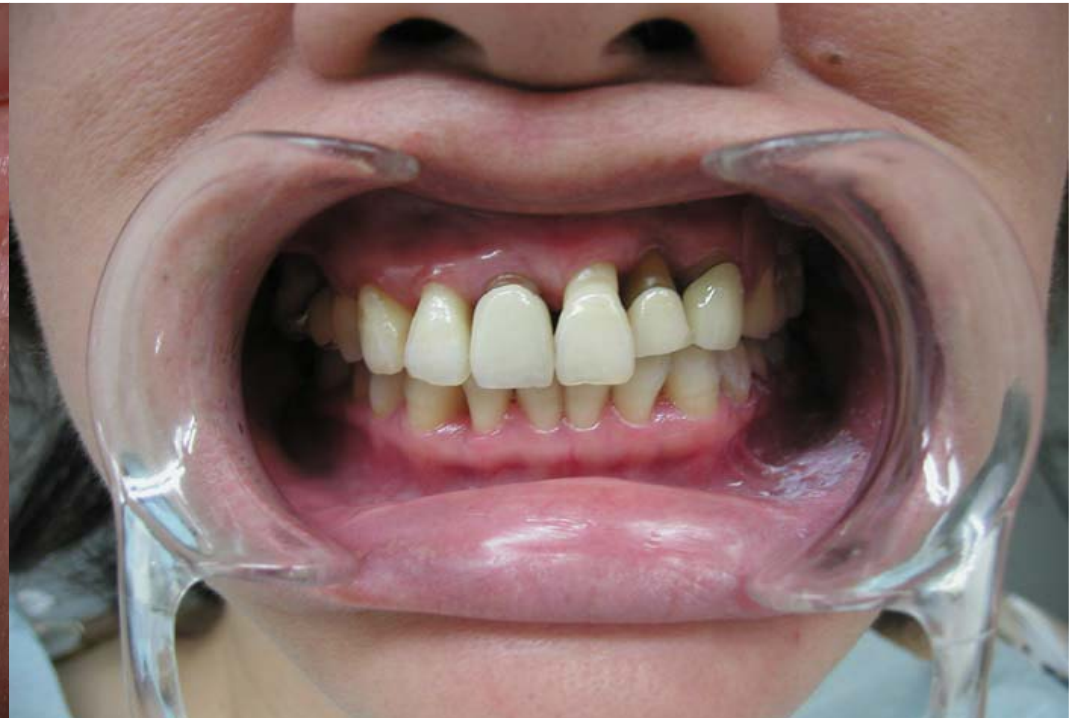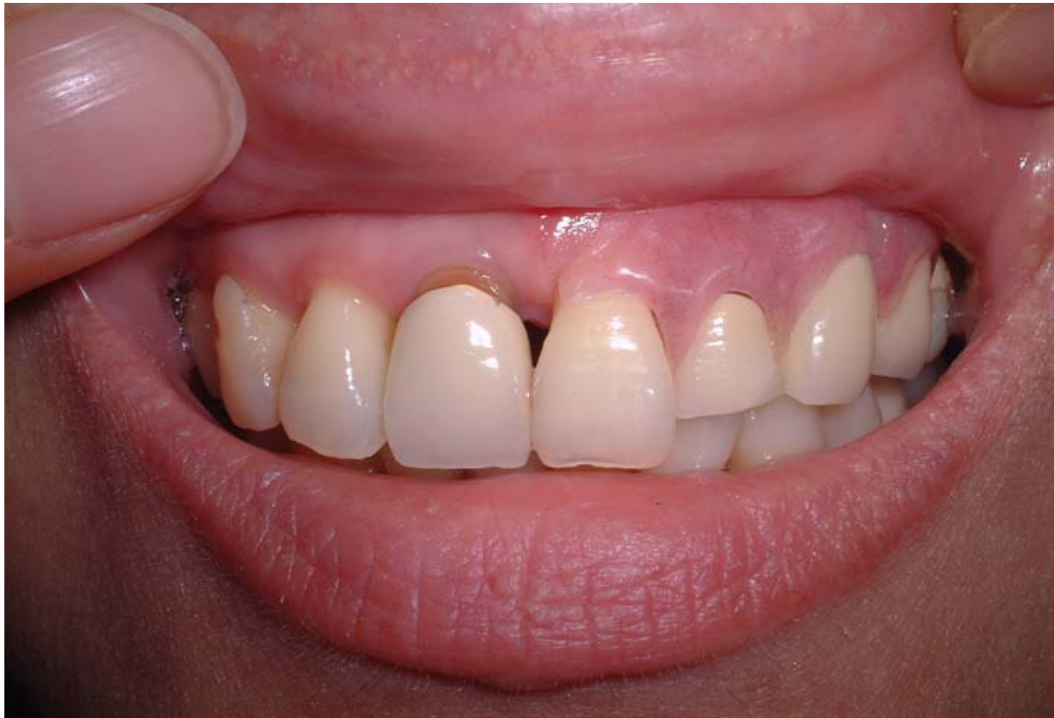©All rights are reserved by
Eiji Tomita December 2014

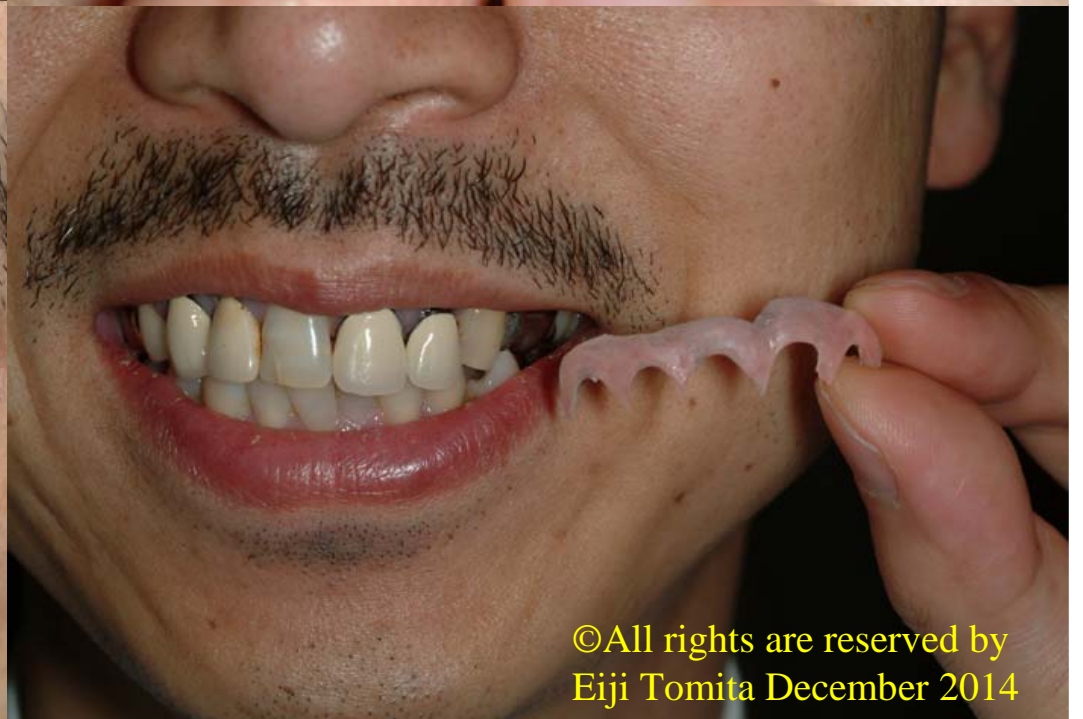
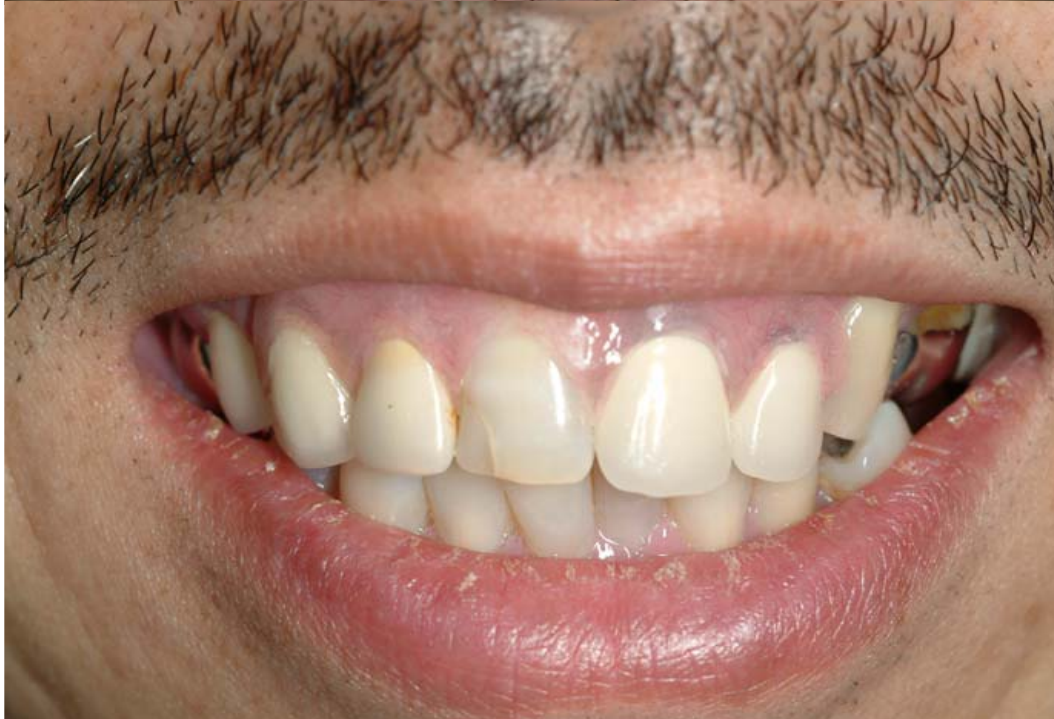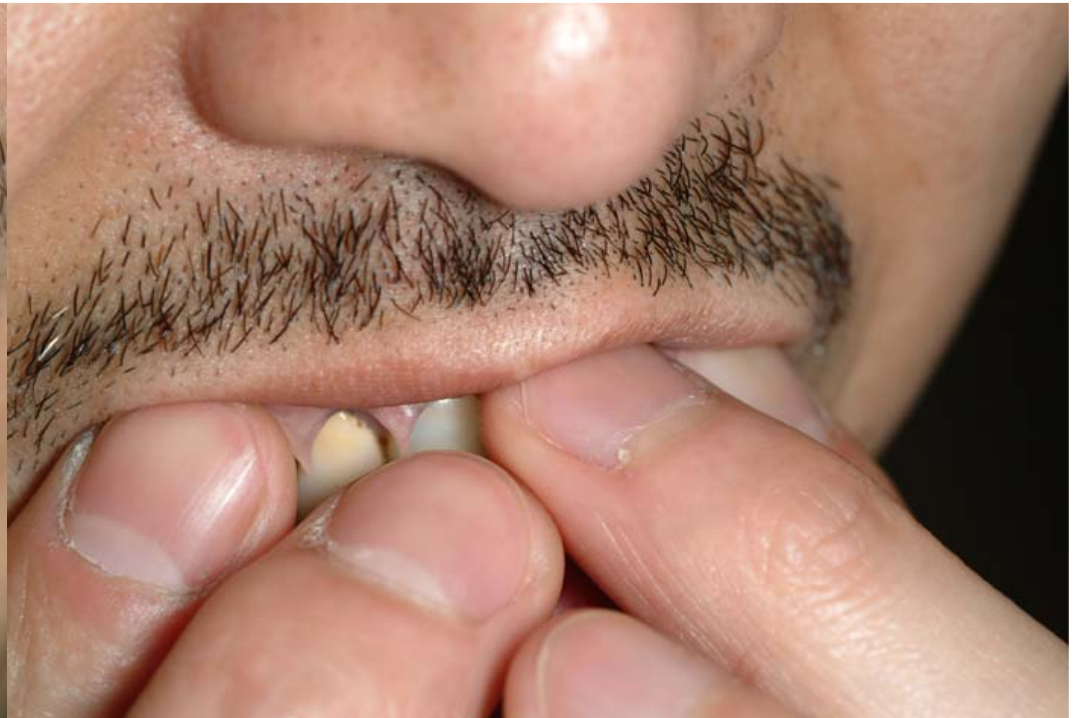

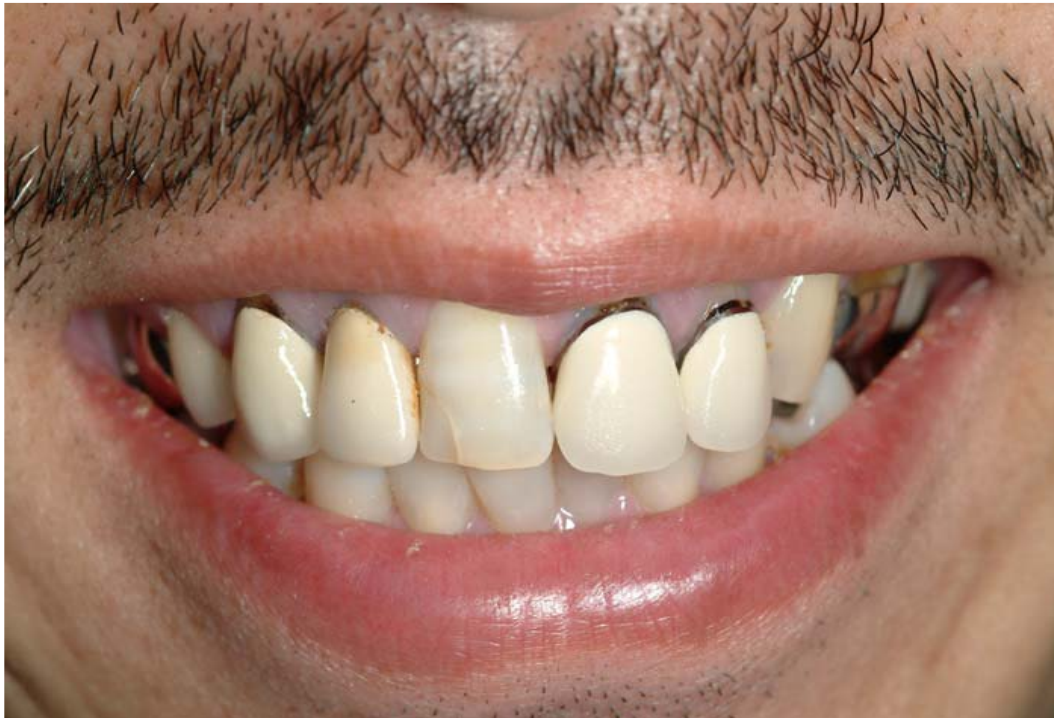
Removable labial gum

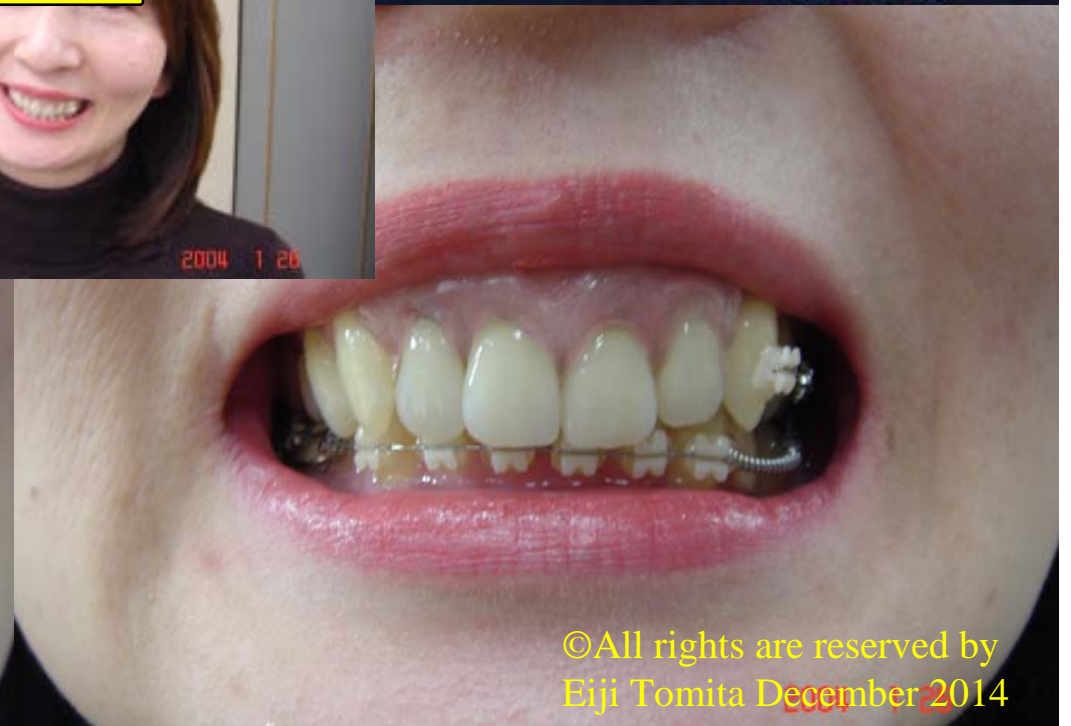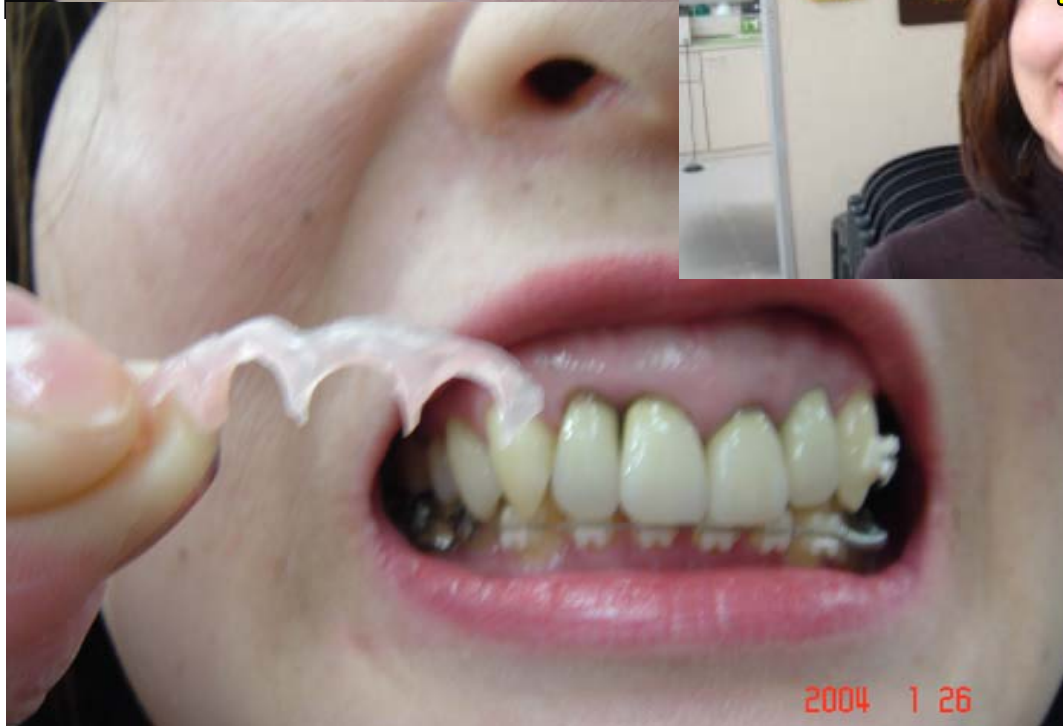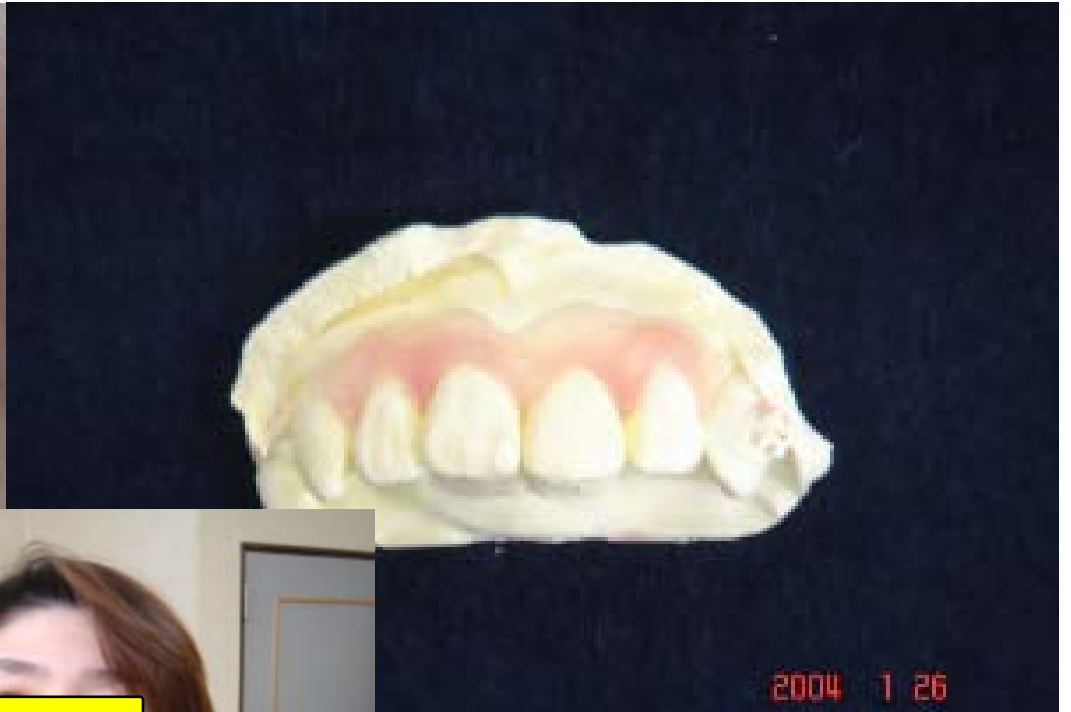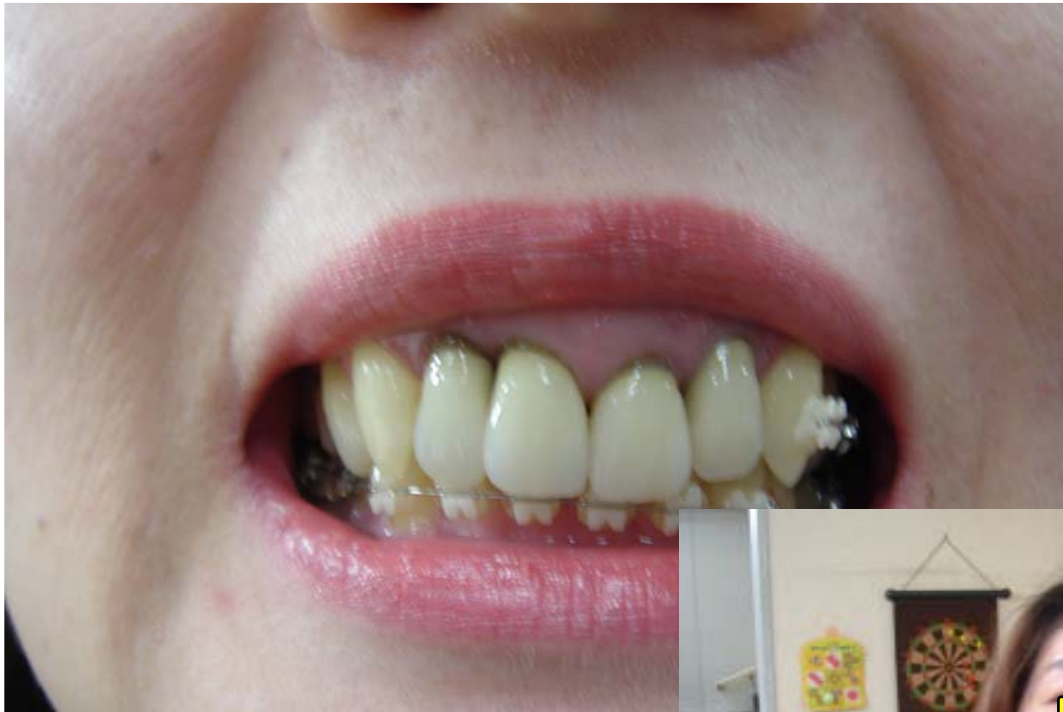©All rights are reserved by
Eiji Tomita December 2014



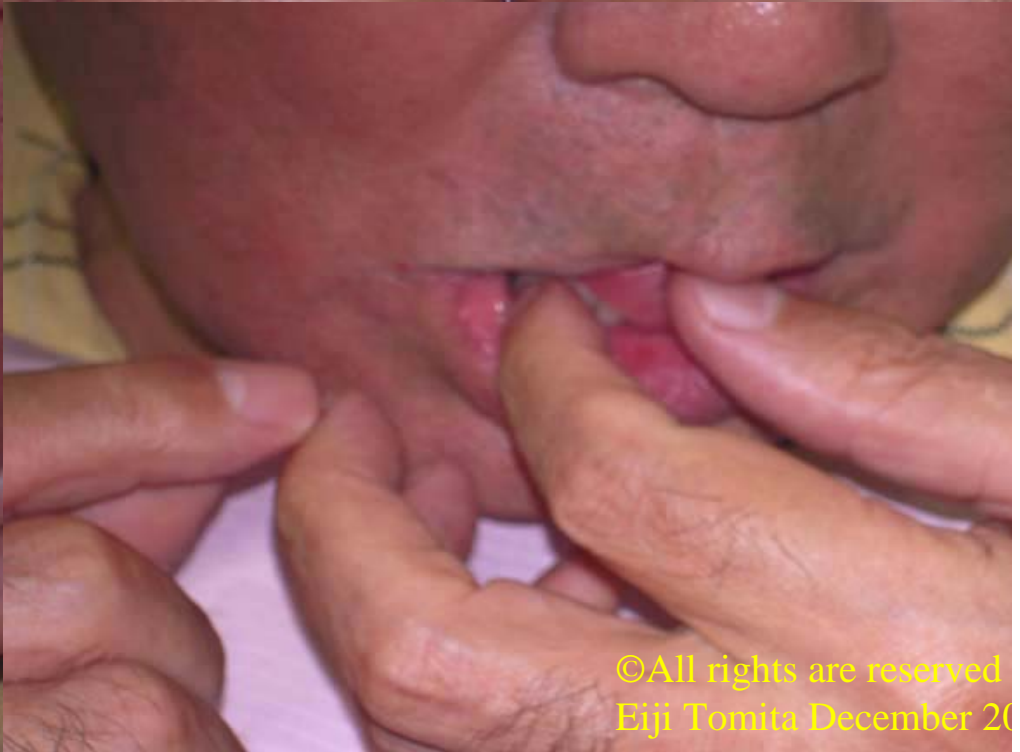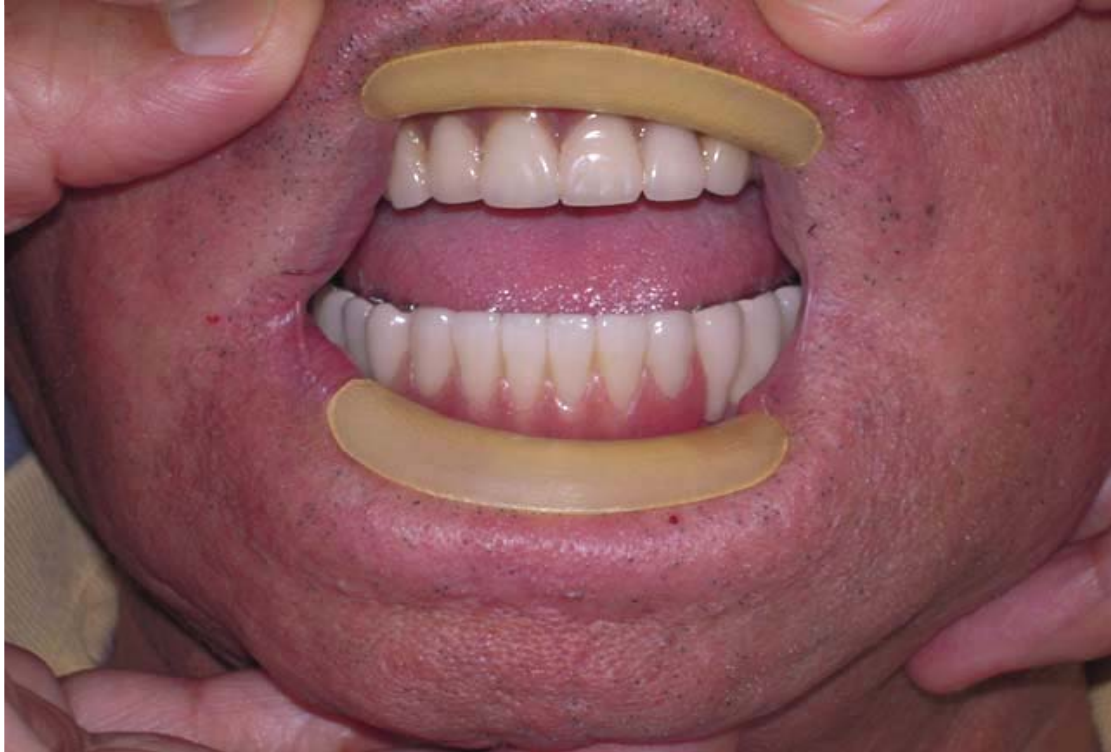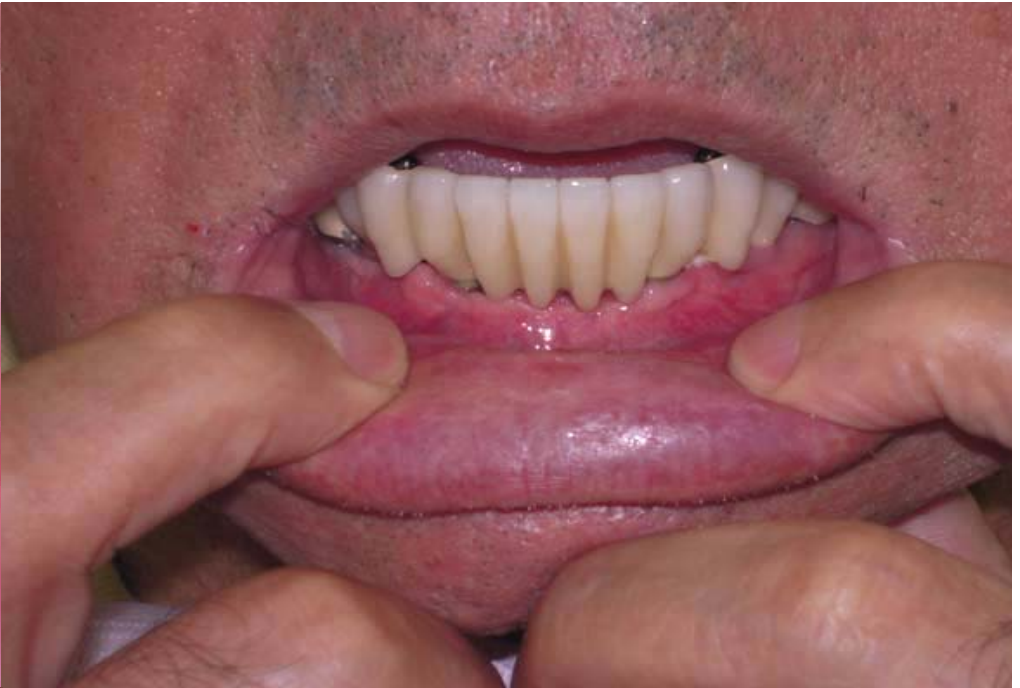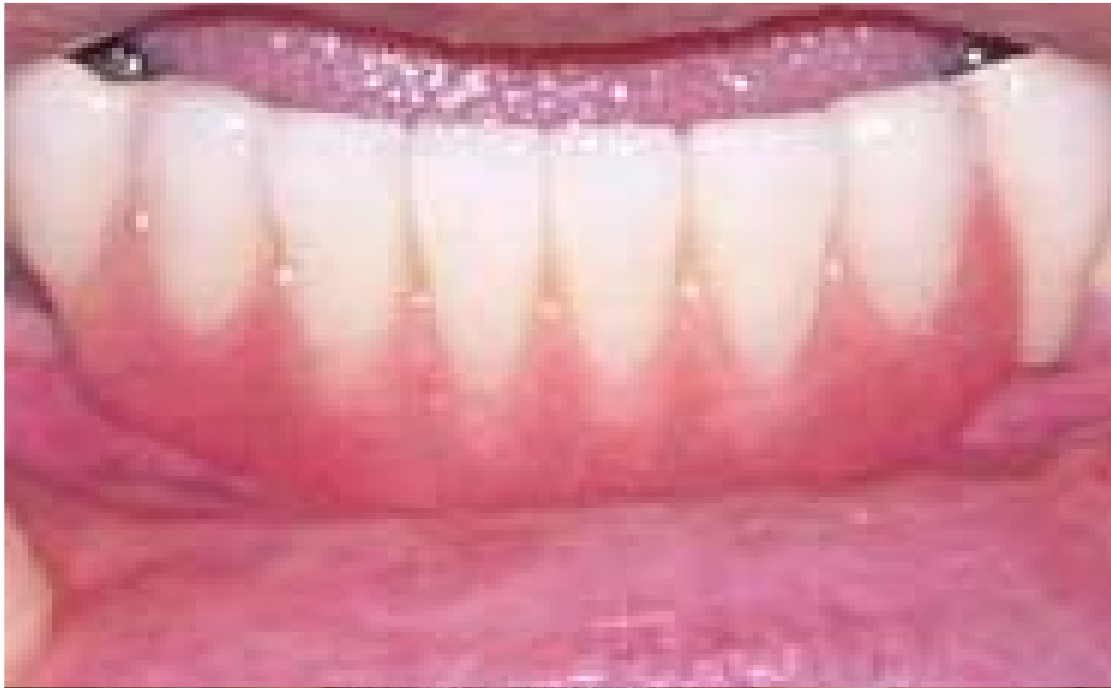©All rights are reserved by
Eiji Tomita December 2014

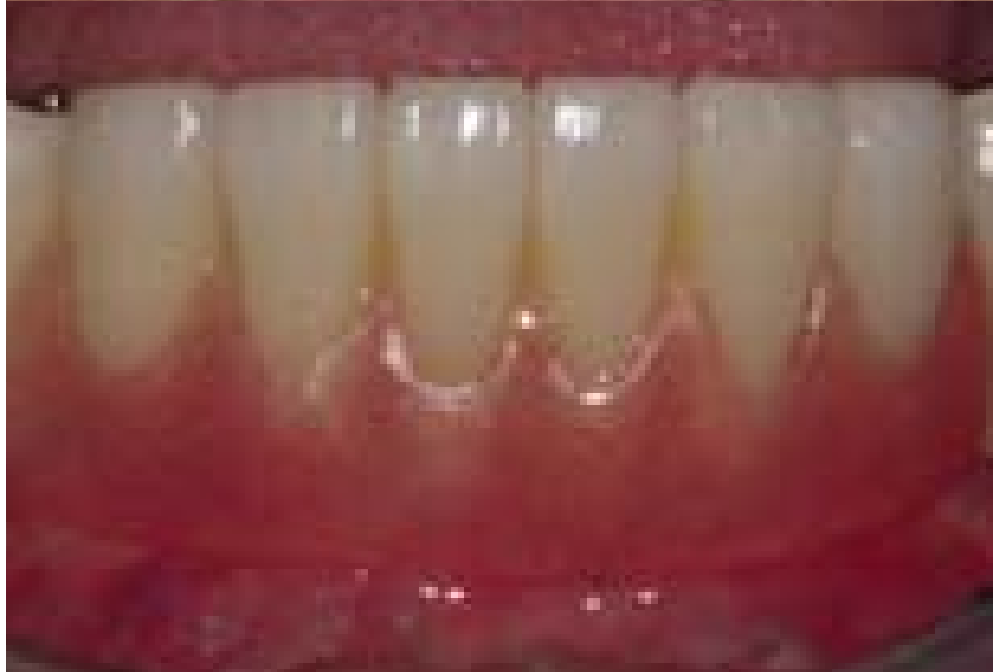
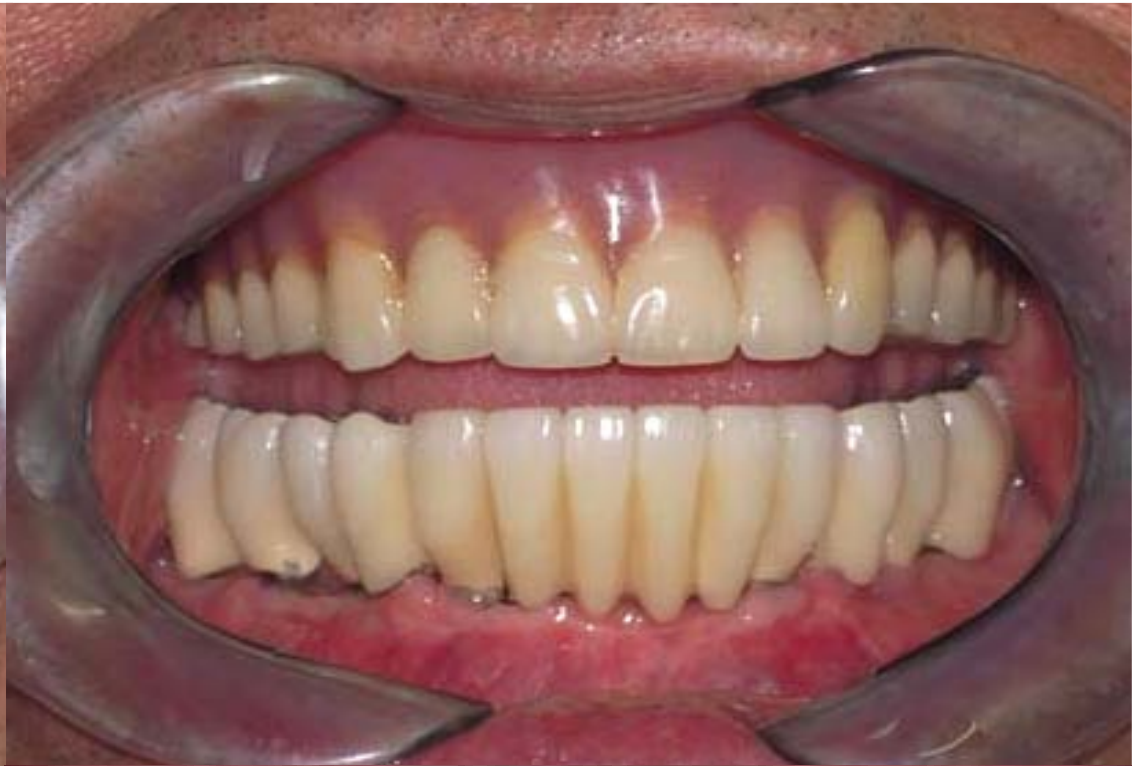
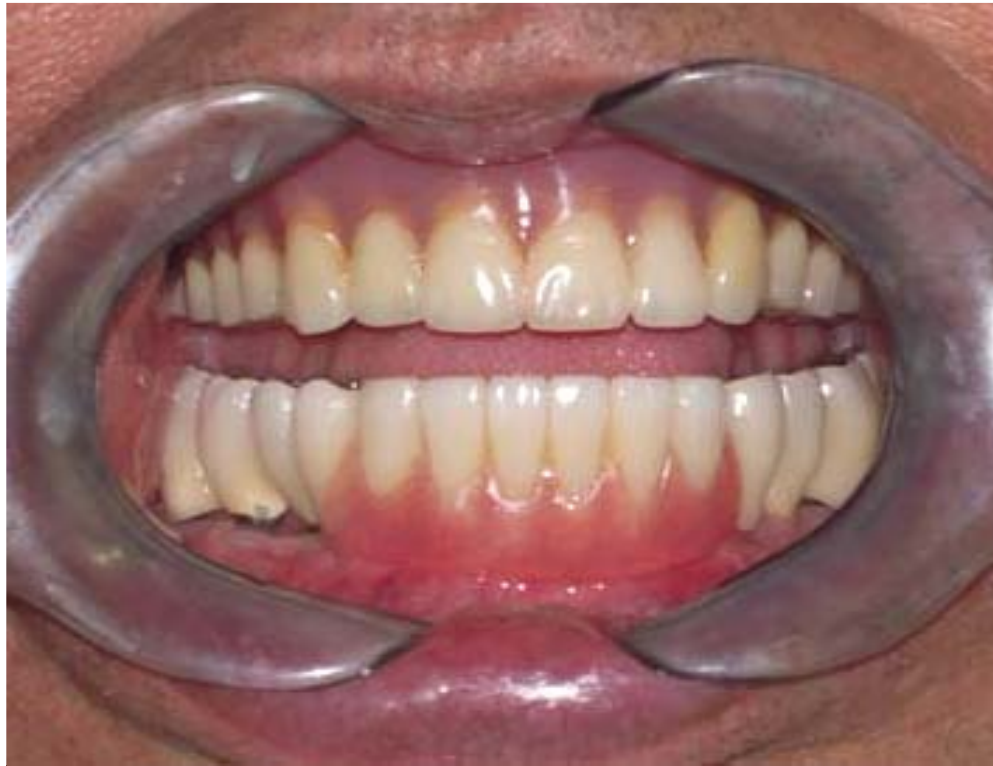©All rights are reserved by
Eiji Tomita December 2014

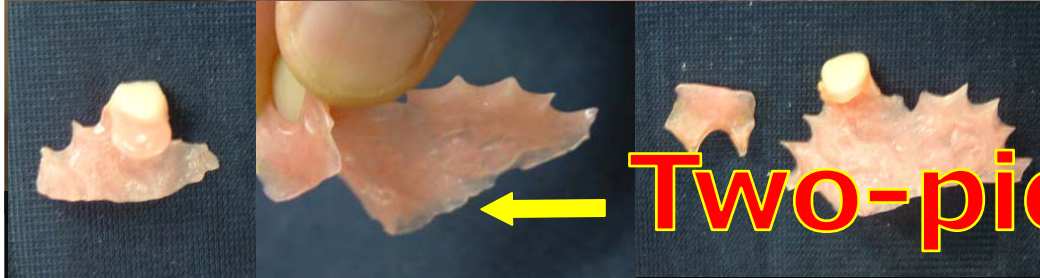
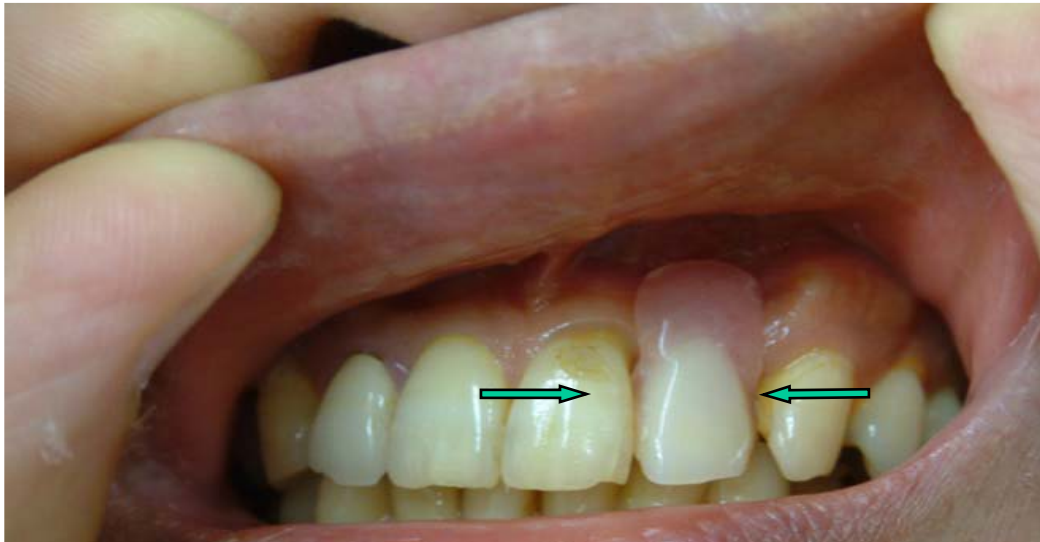


©All rights are reserved by
Eiji Tomita December 2014

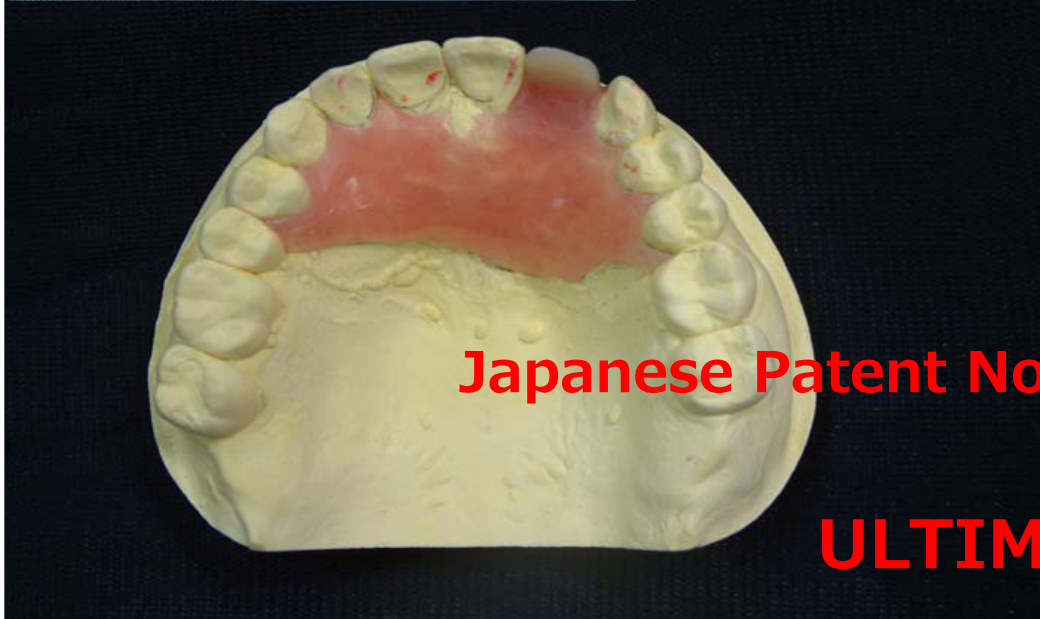



©All rights are reserved by
Eiji Tomita December 2014

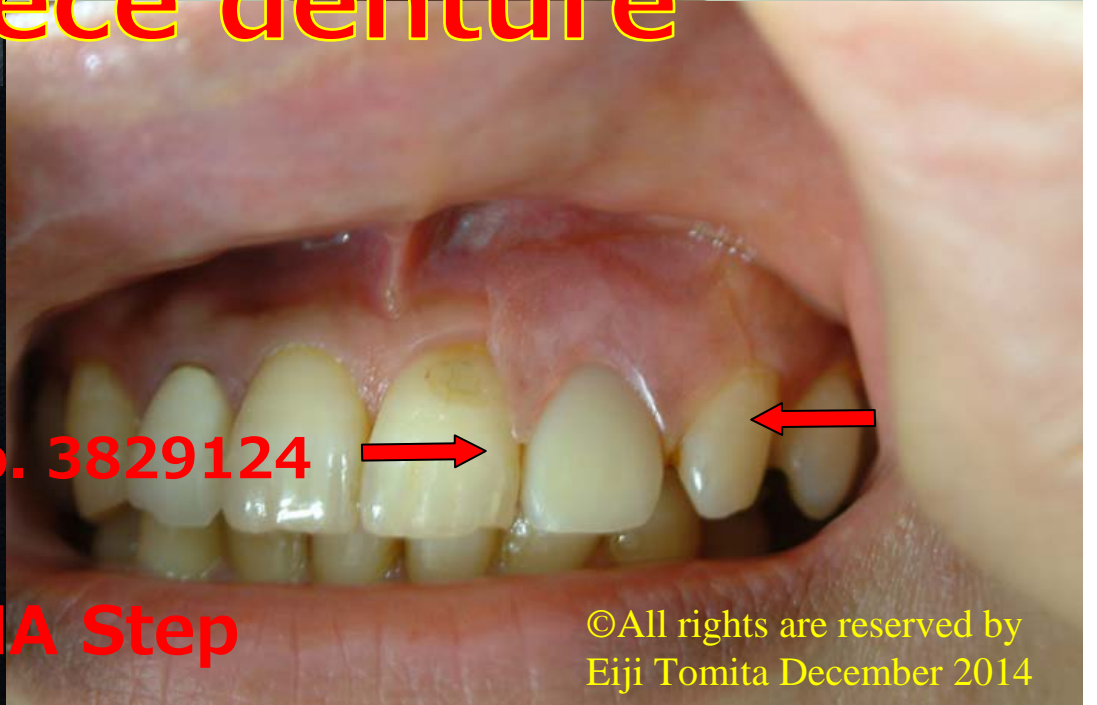

Two-piece denture

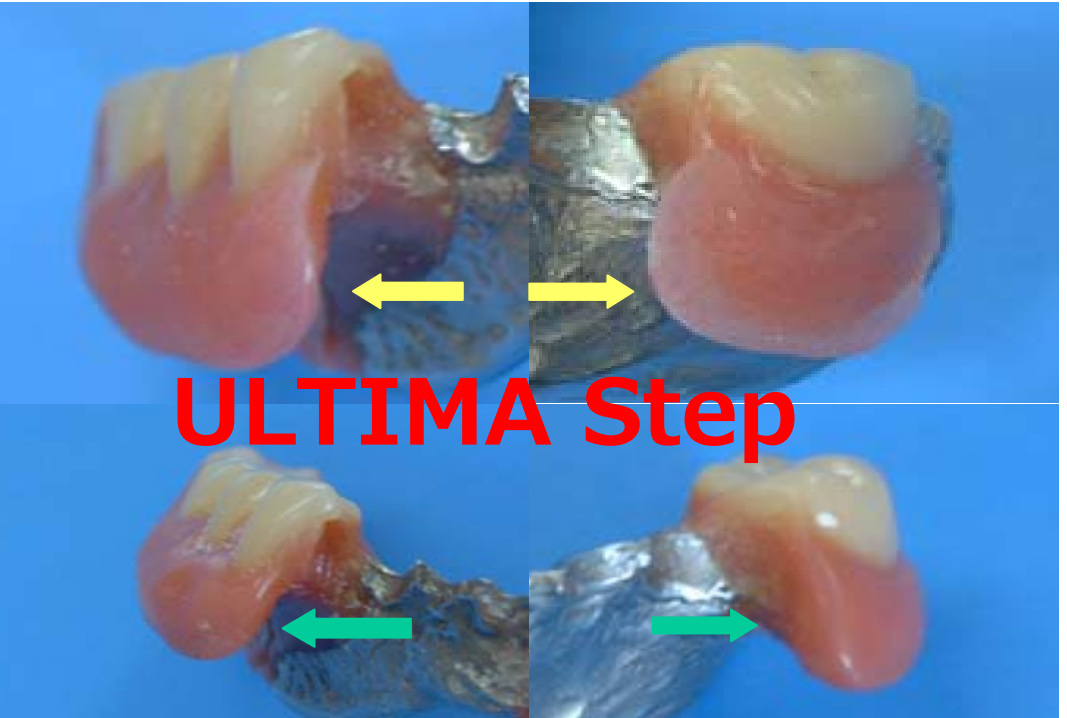
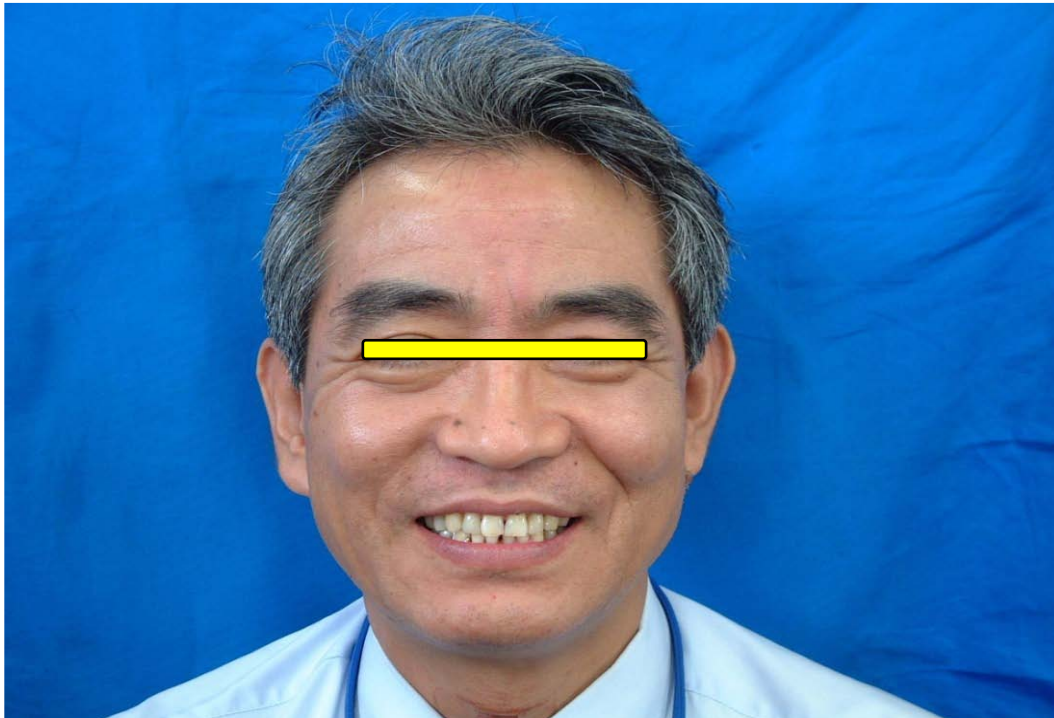


Japanese Patent No. 3829124

ULTIMA Step

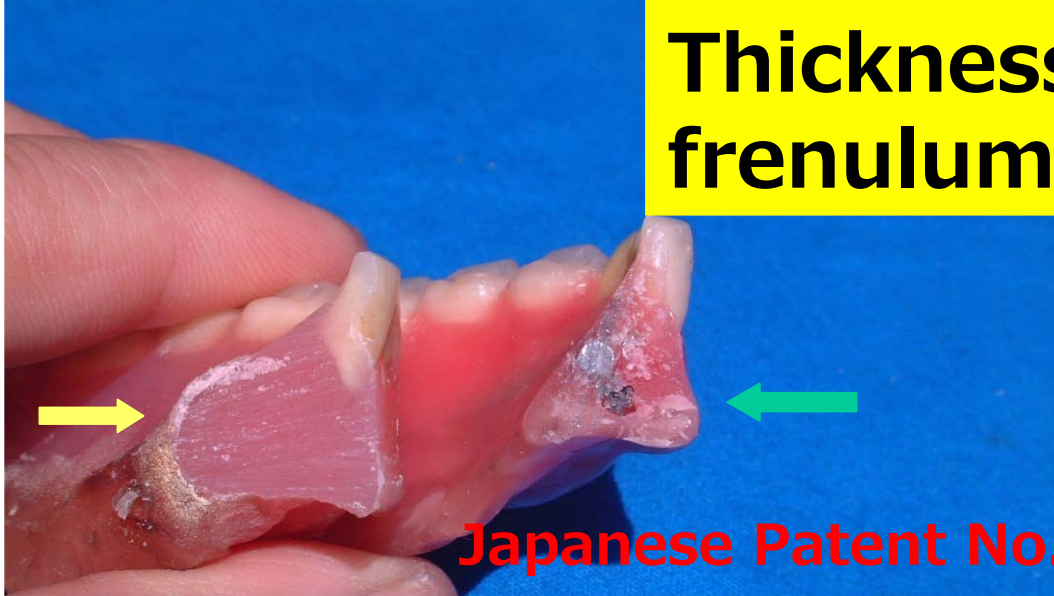

©All rights are reserved by Eiji Tomita December 2014



ULTIMA Step

Thickness of frenulum linguae

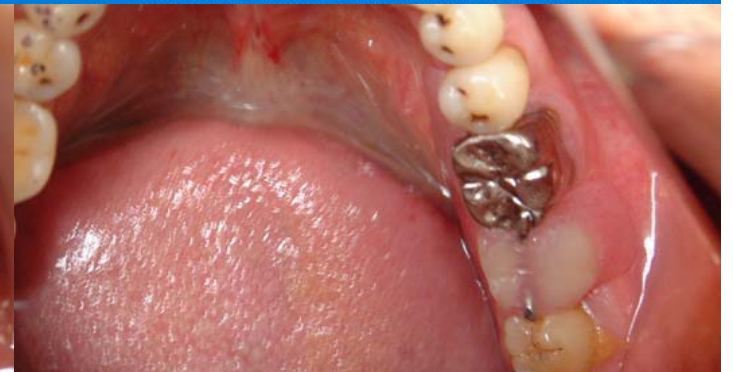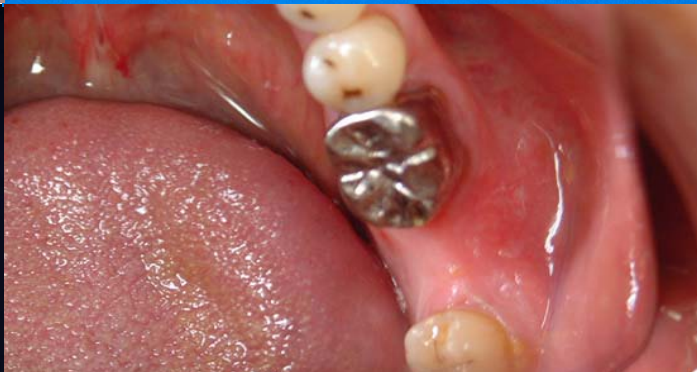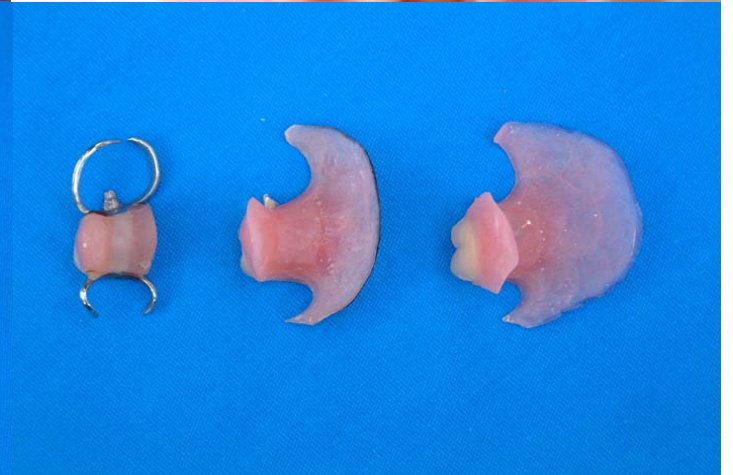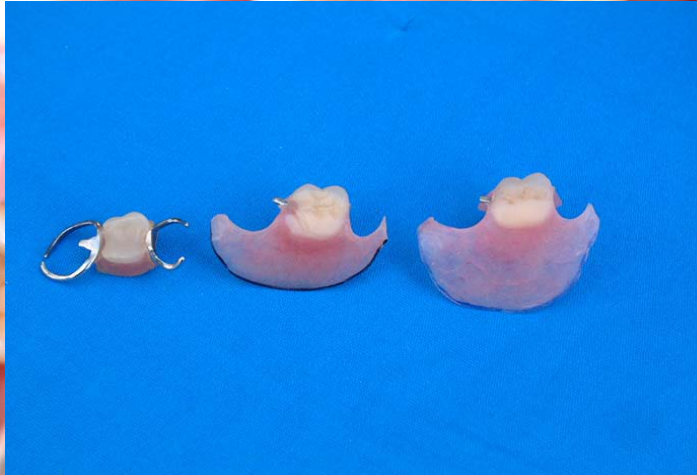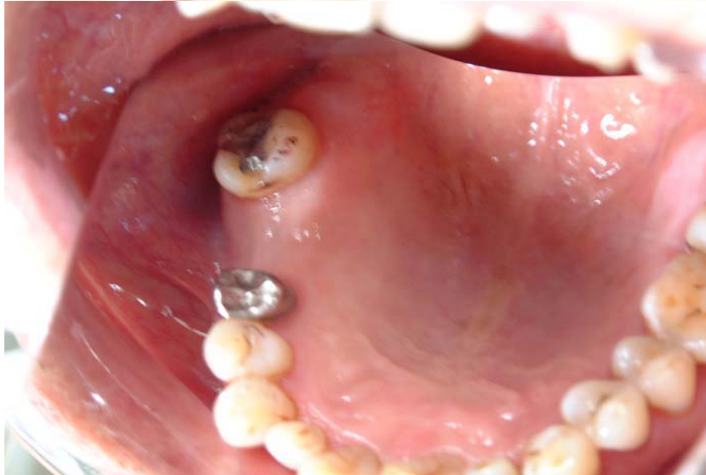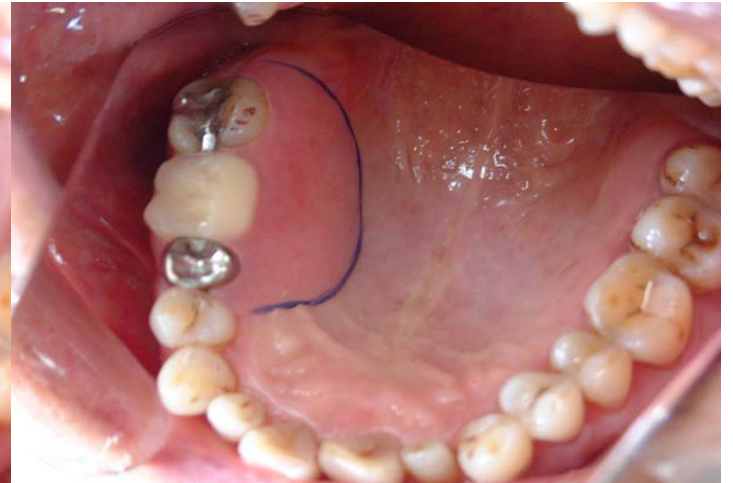


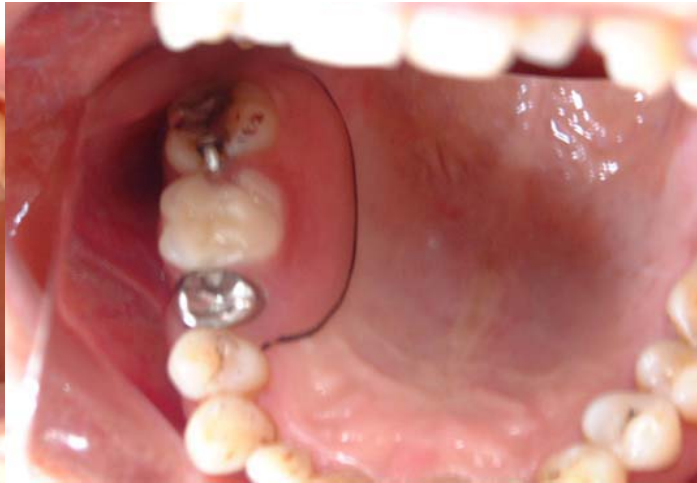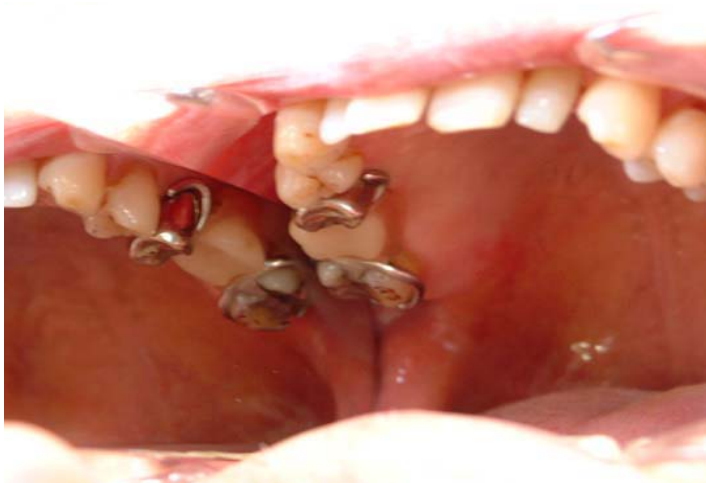Japanese Patent No. 3829124



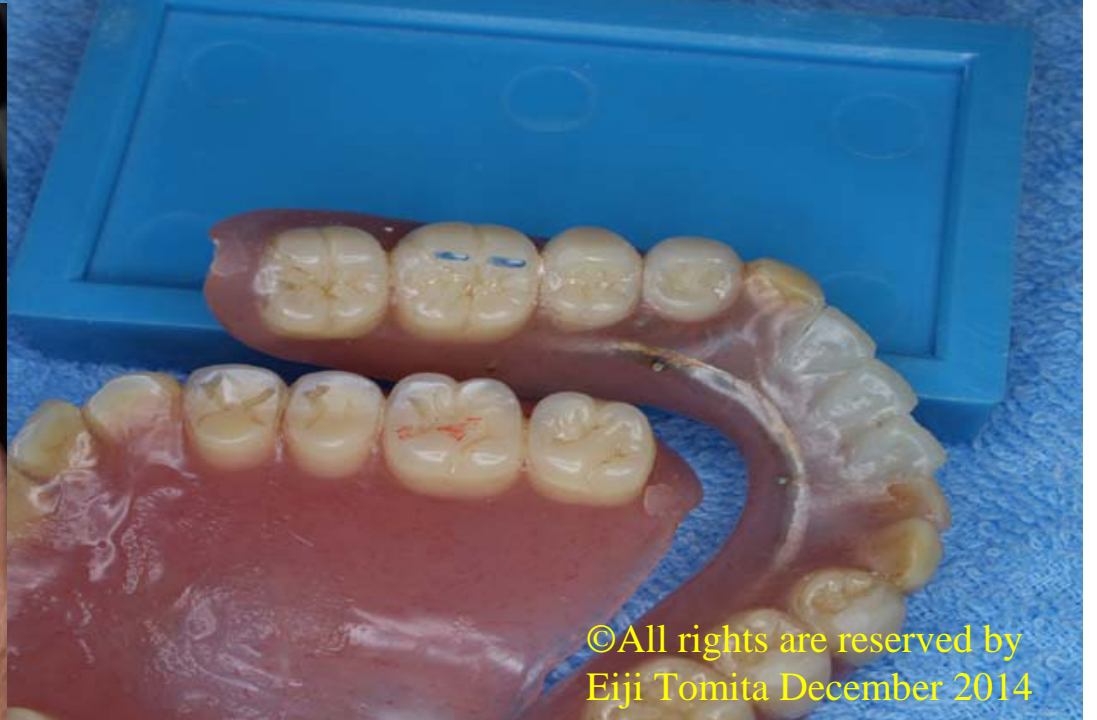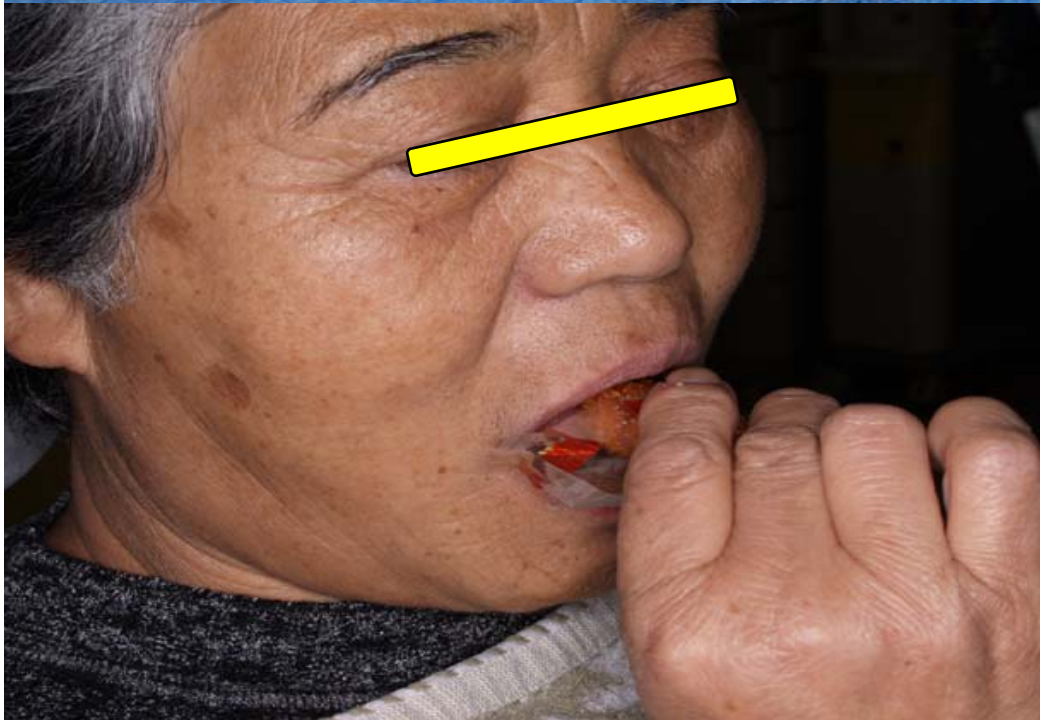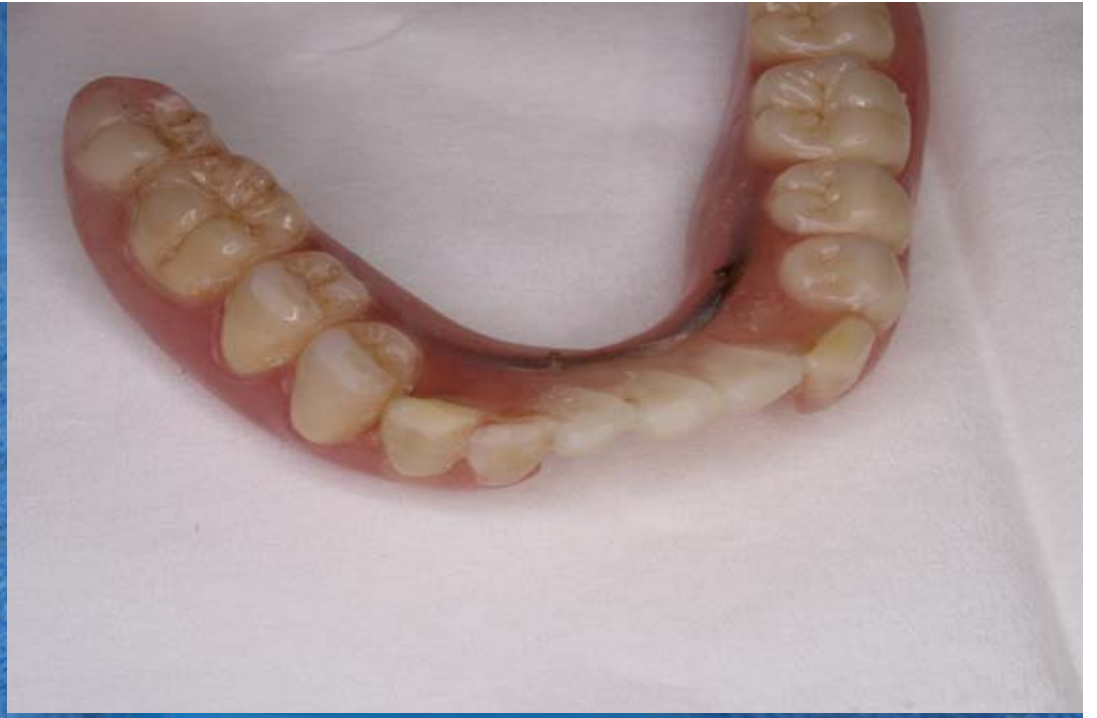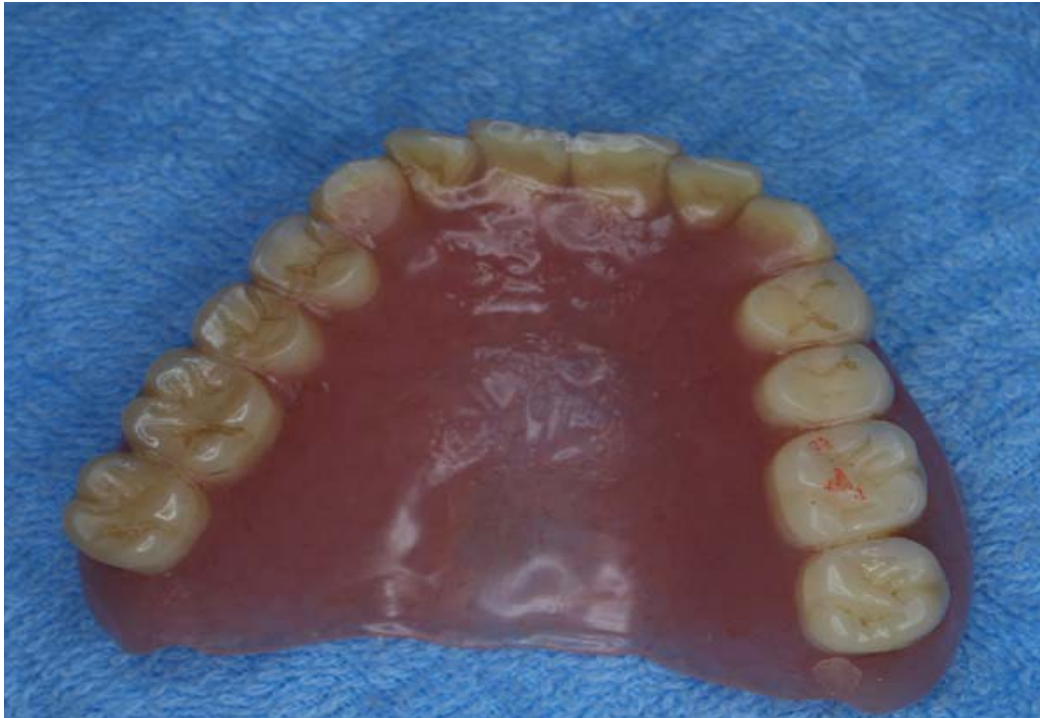Shape of frenulum linguae

©All rights are reserved by Eiji Tomita December 2014

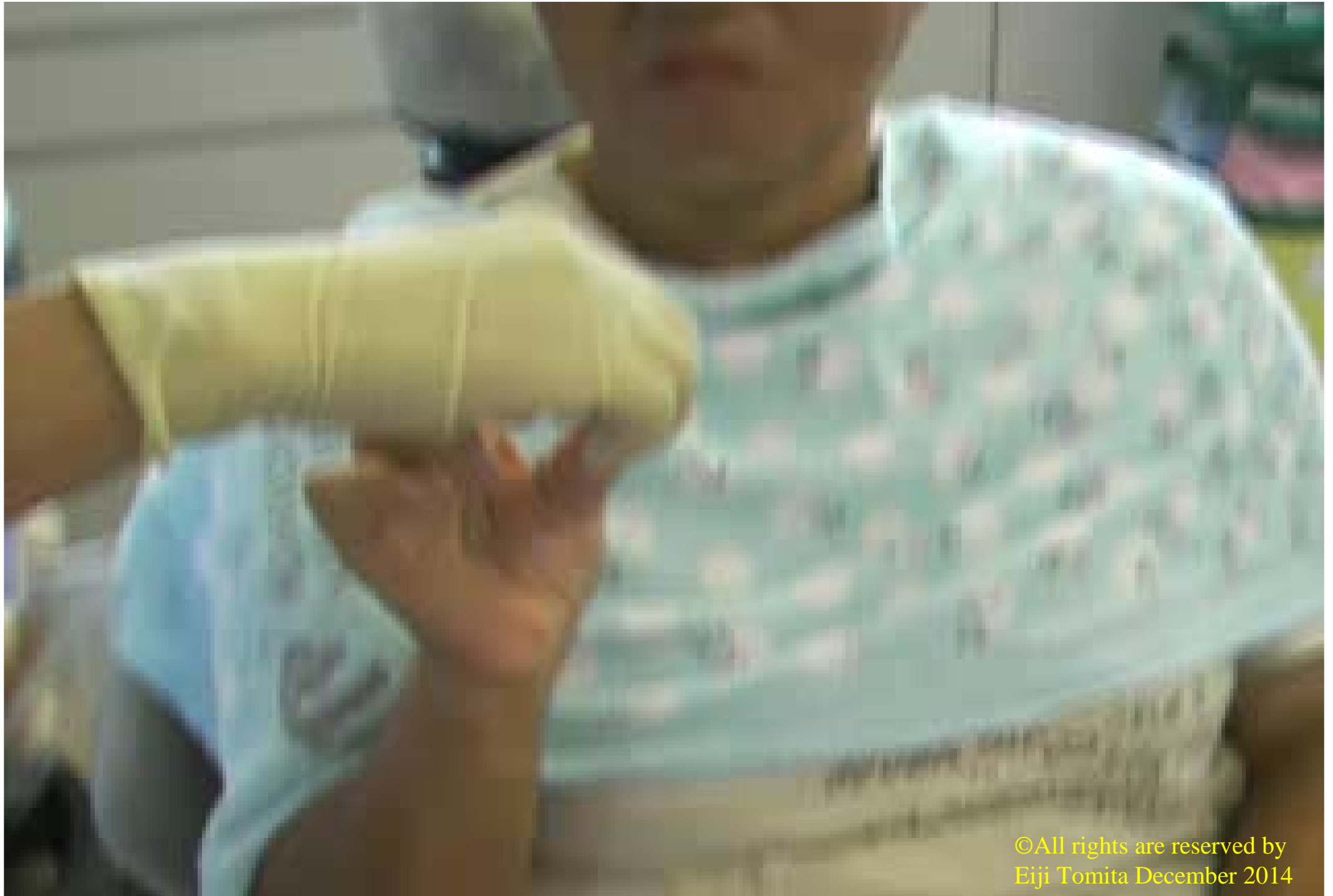

Easy to eat without clasp

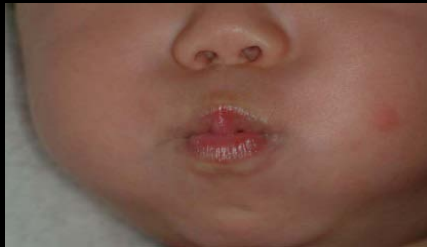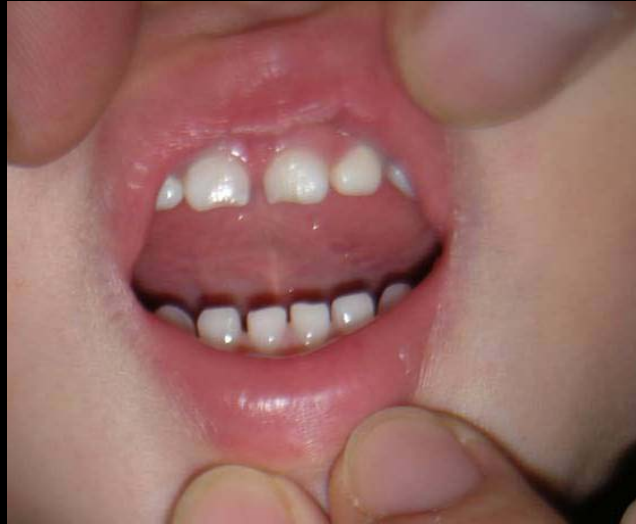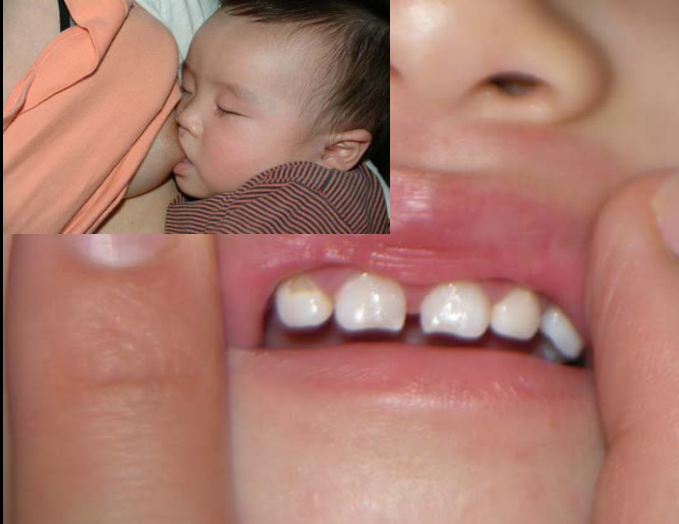©All rights are reserved by Eiji Tomita December 2014



©All rights are reserved by Eiji Tomita December 2014



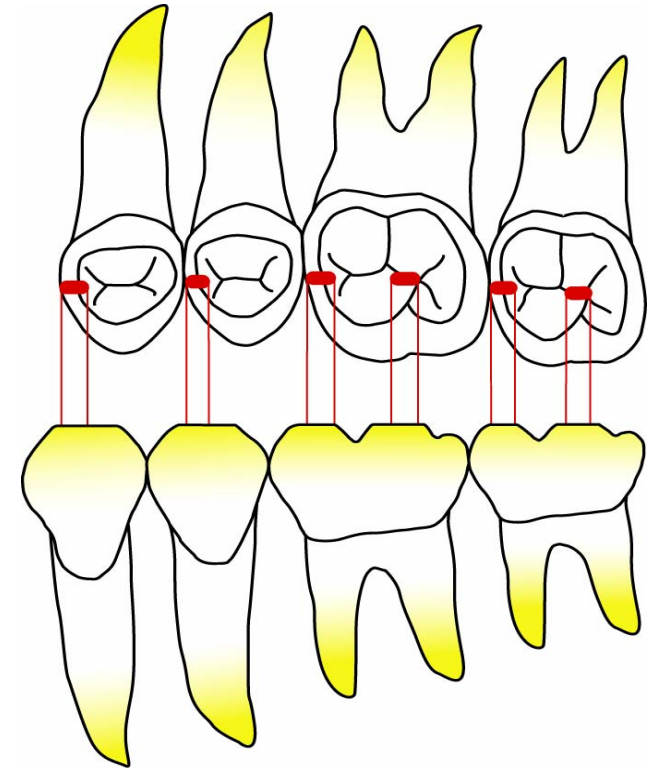
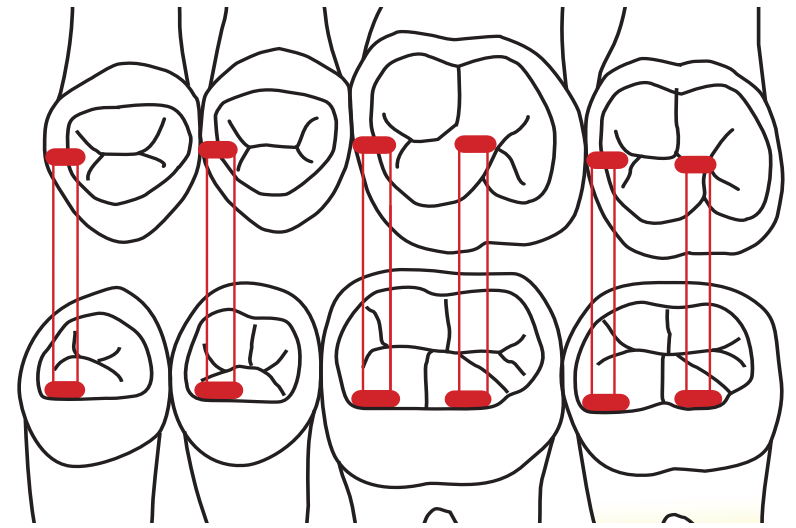
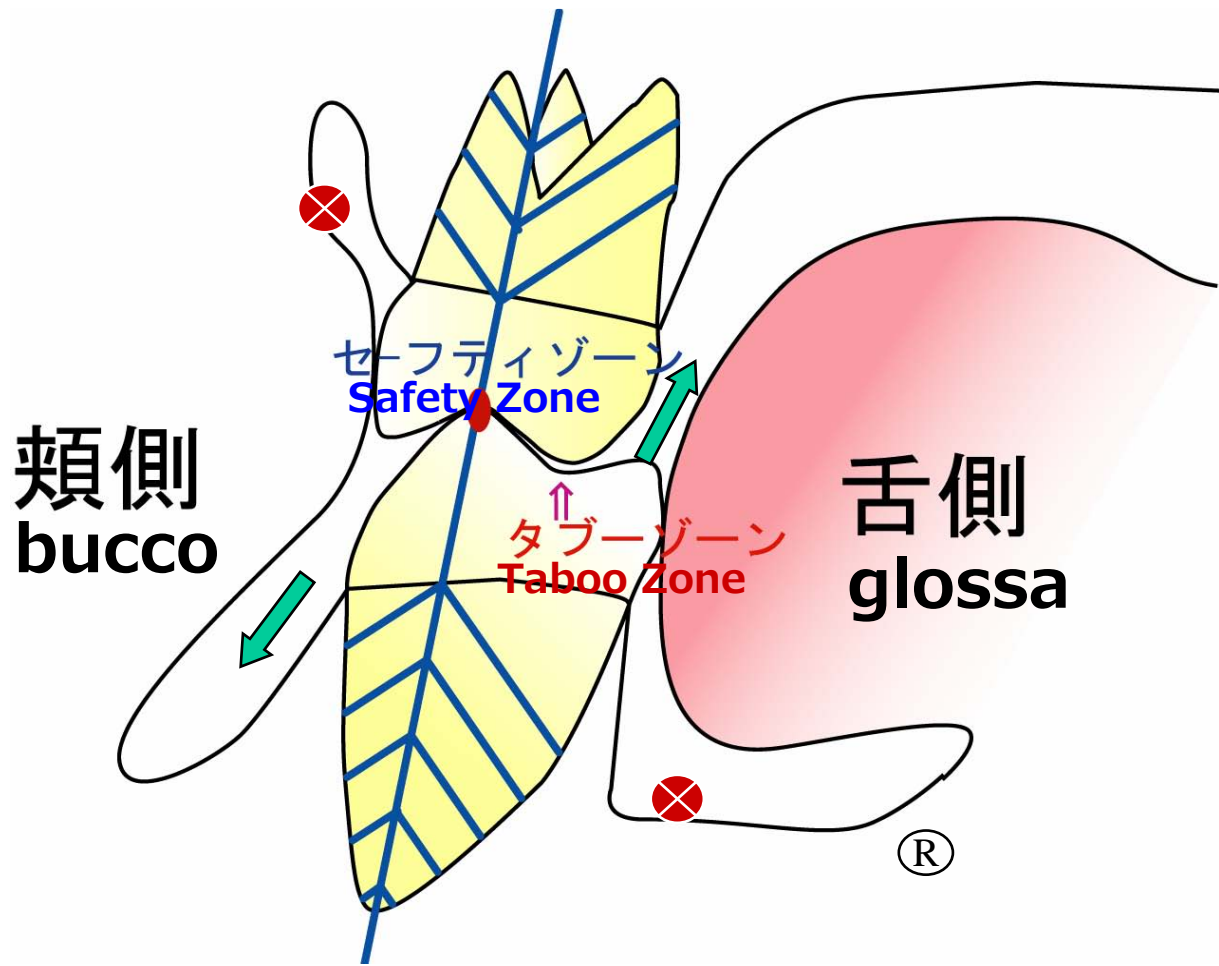
©All rights are reserved by
Eiji Tomita December 2014



©All rights are reserved by
Eiji Tomita December 2014

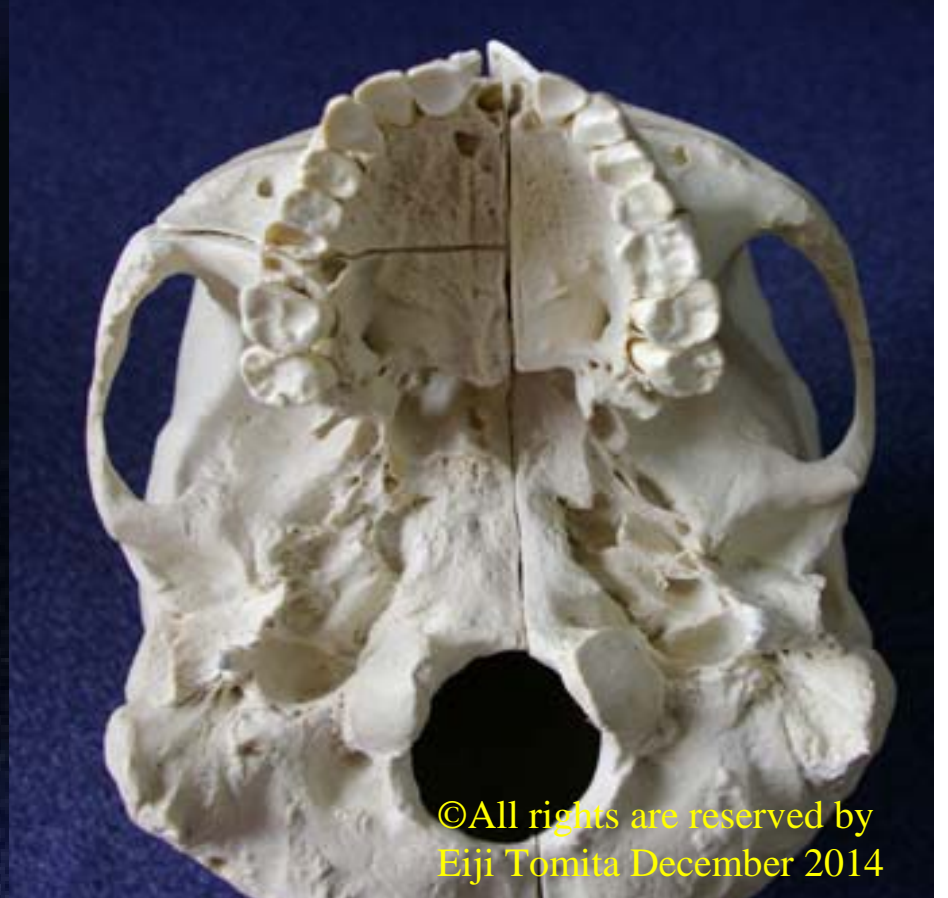
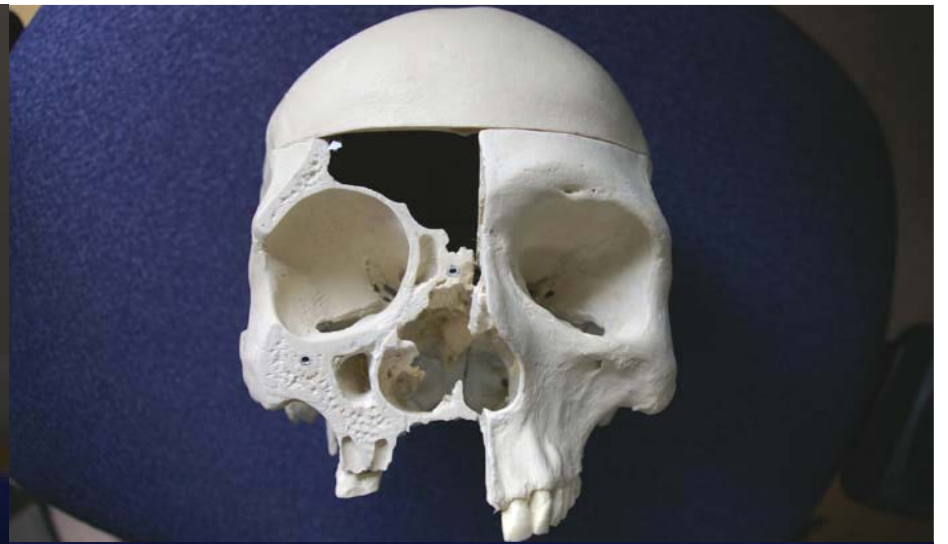
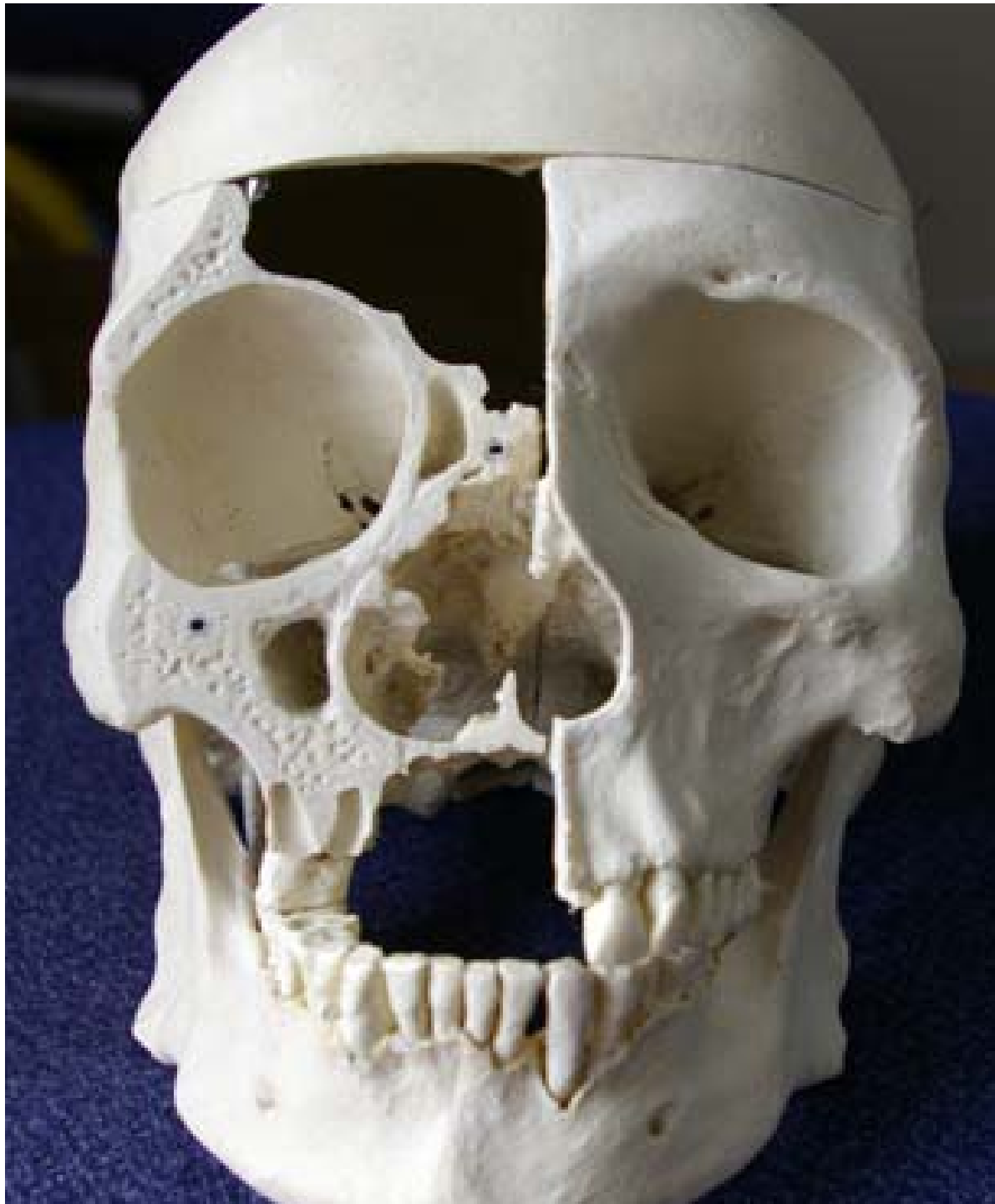**Occlusion
Brings
Miracles!**

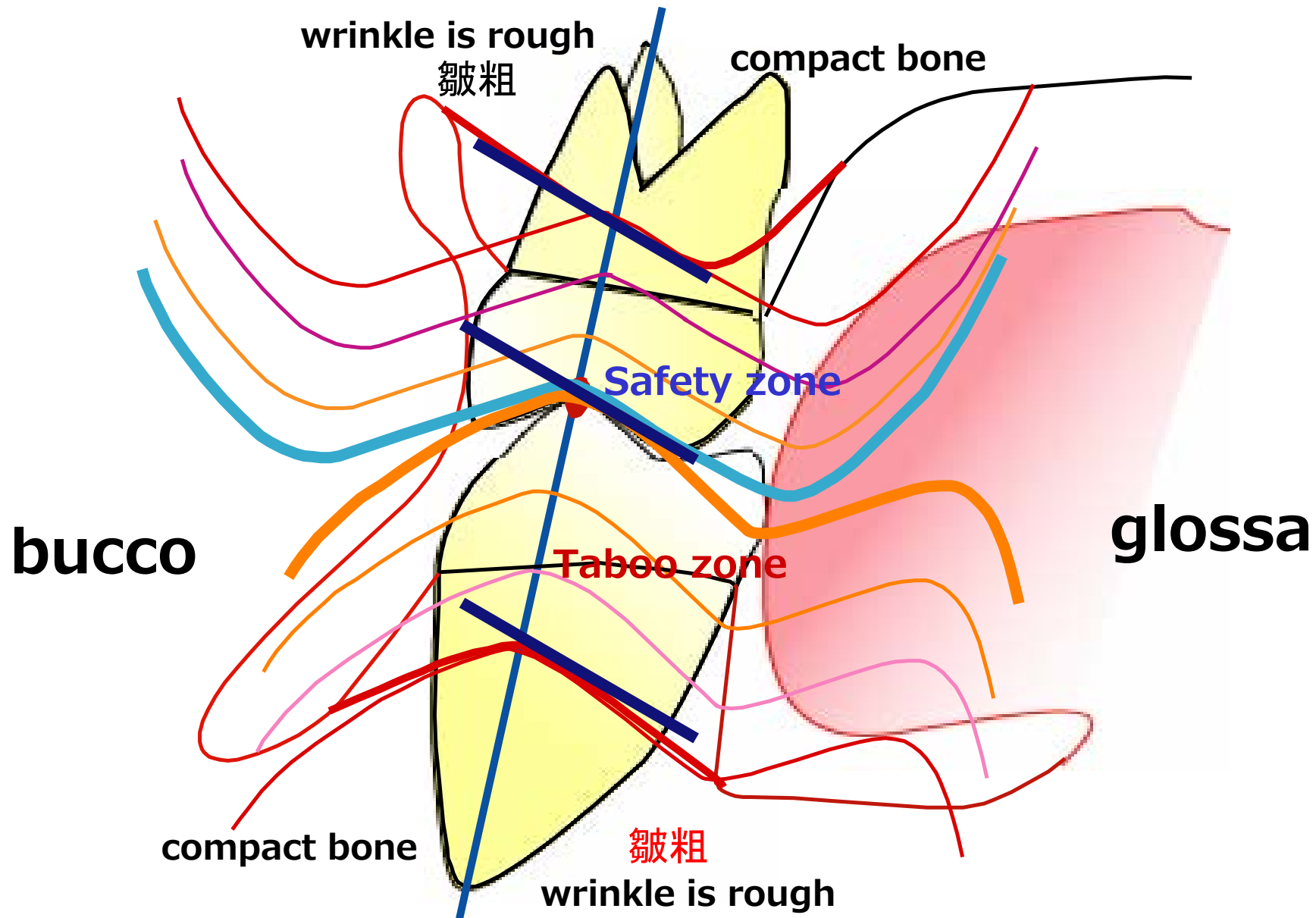


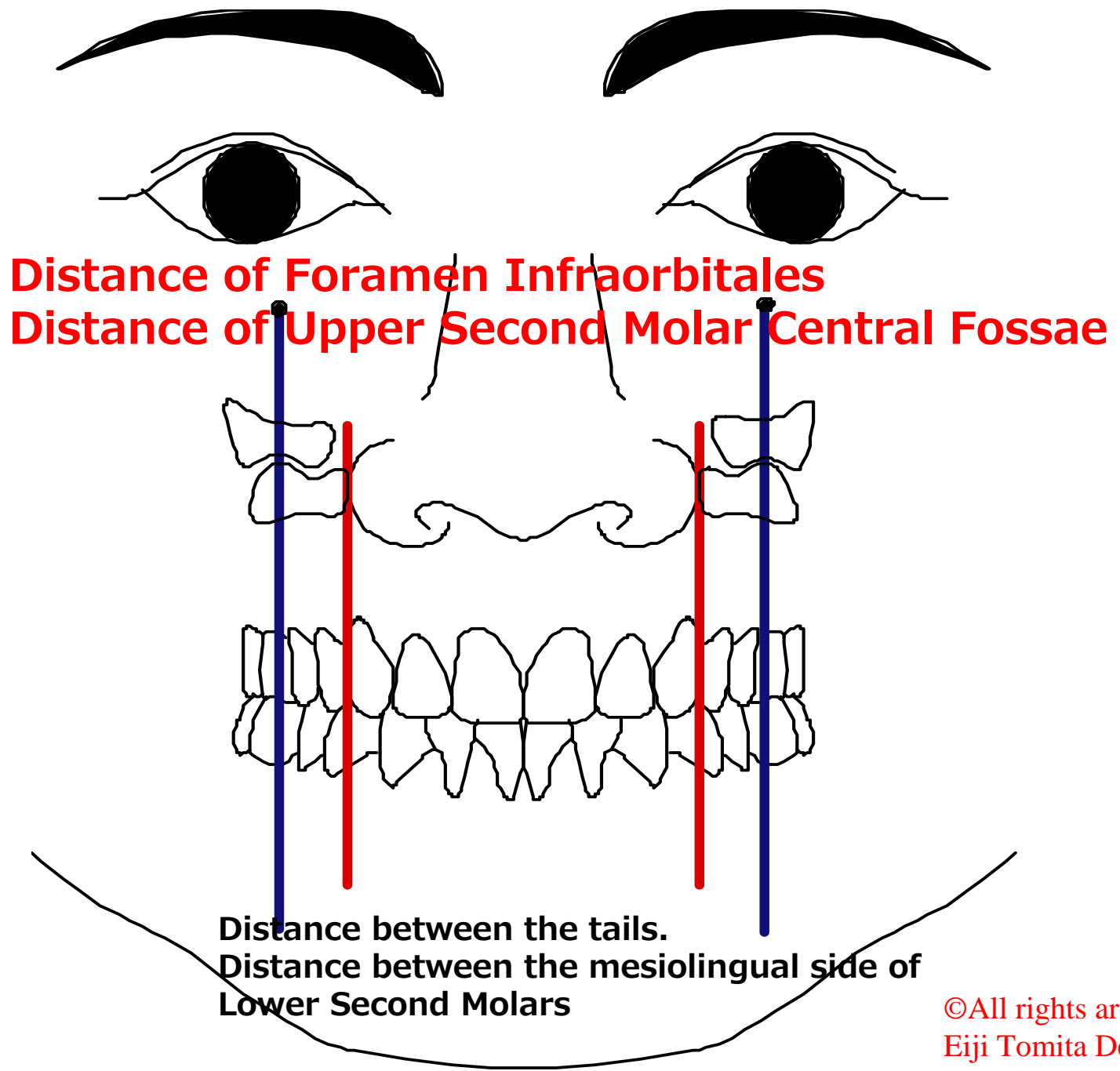
Safety Zone ...occlusion point

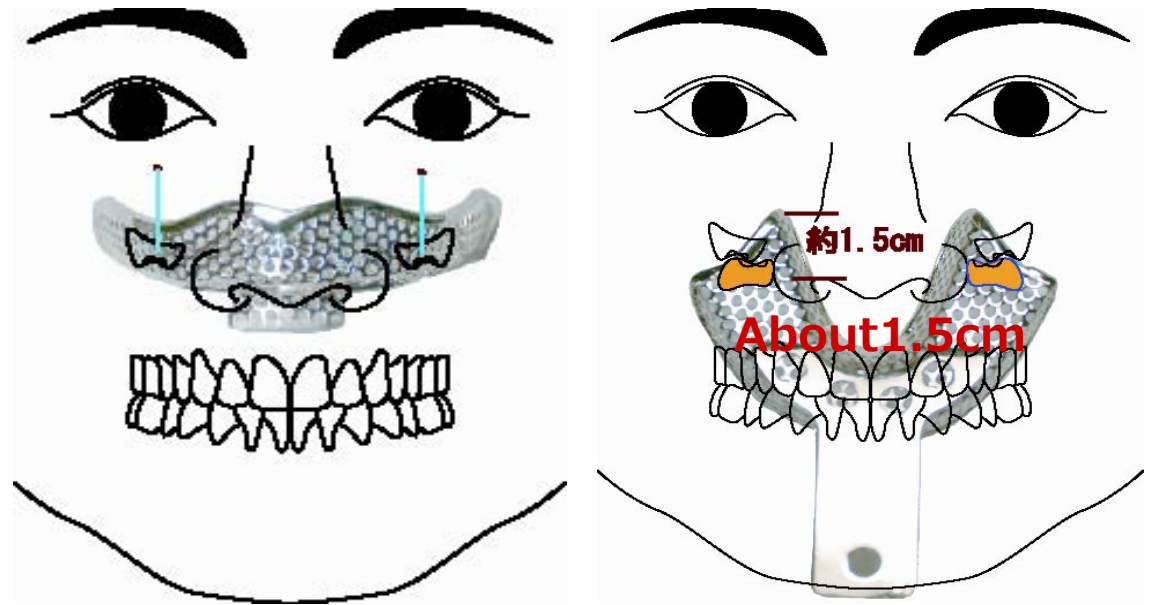
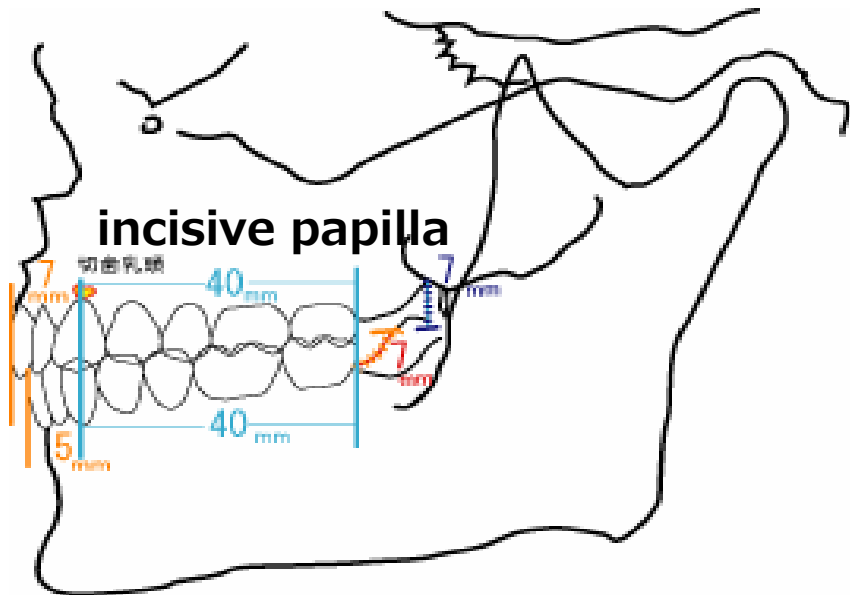
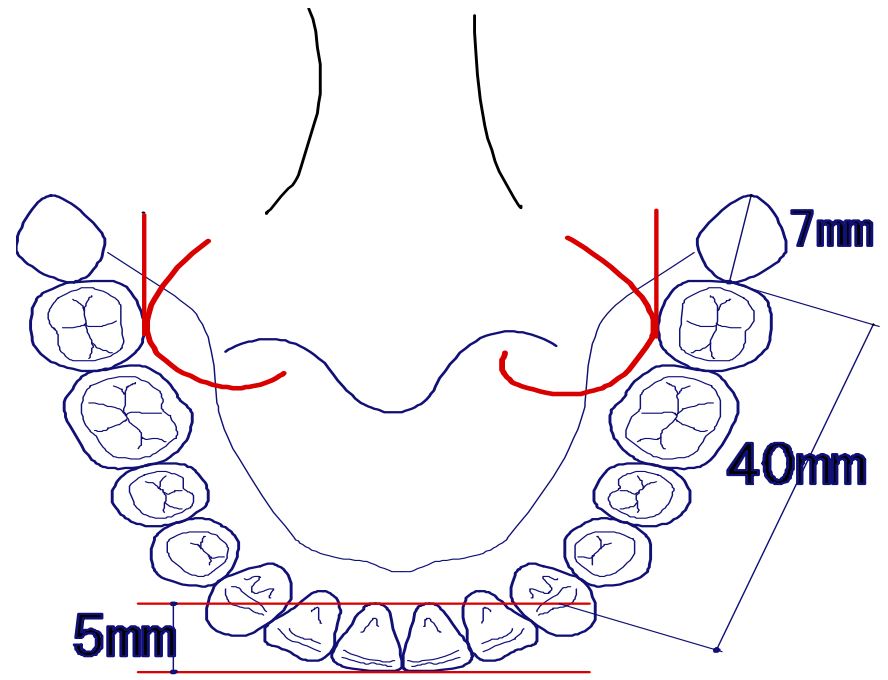
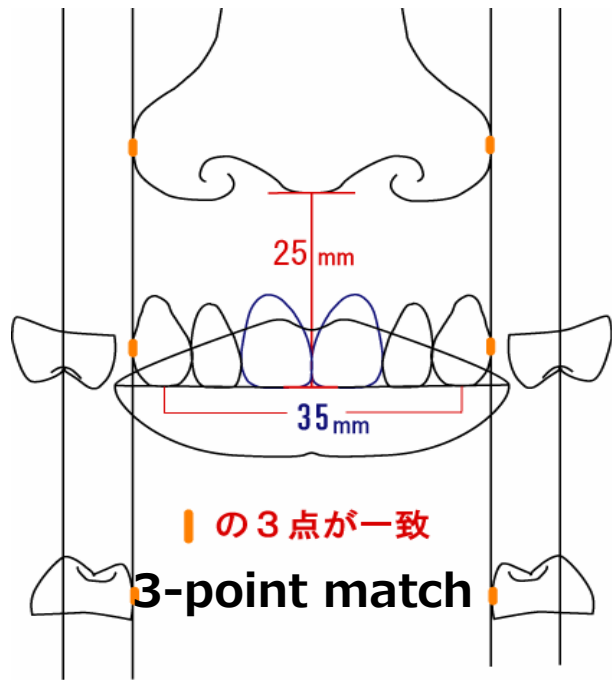
Taboo Zone...non-occlusion point

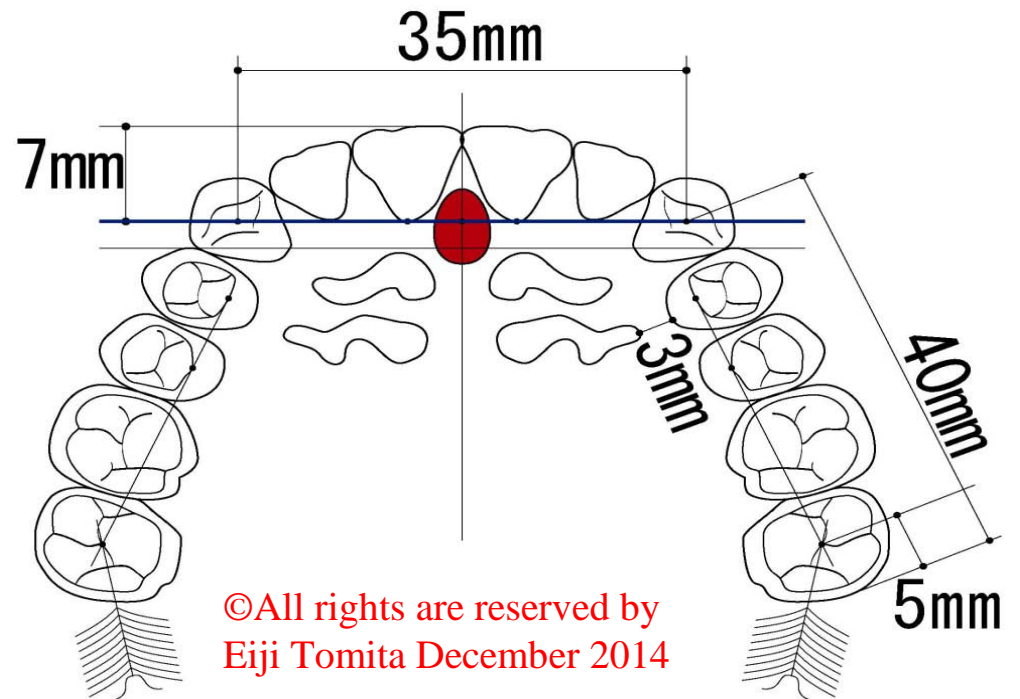
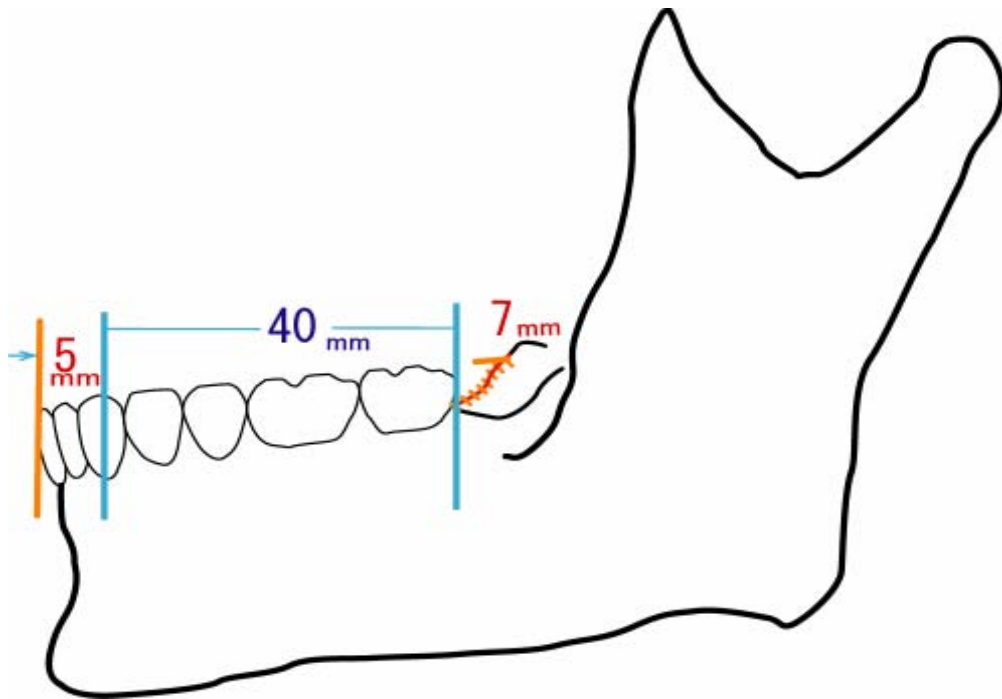
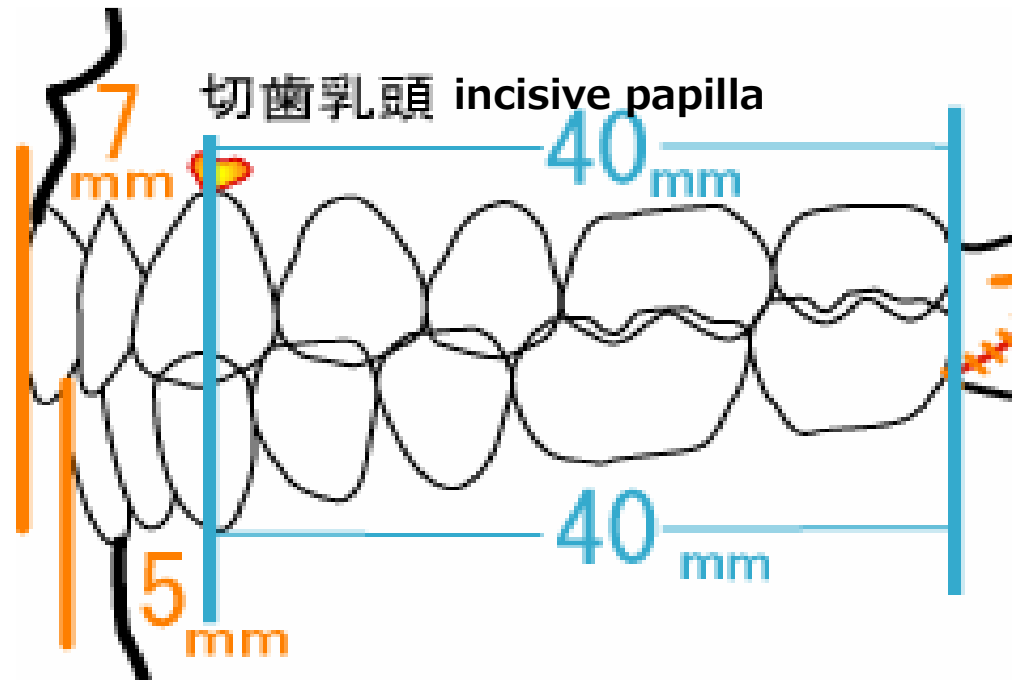
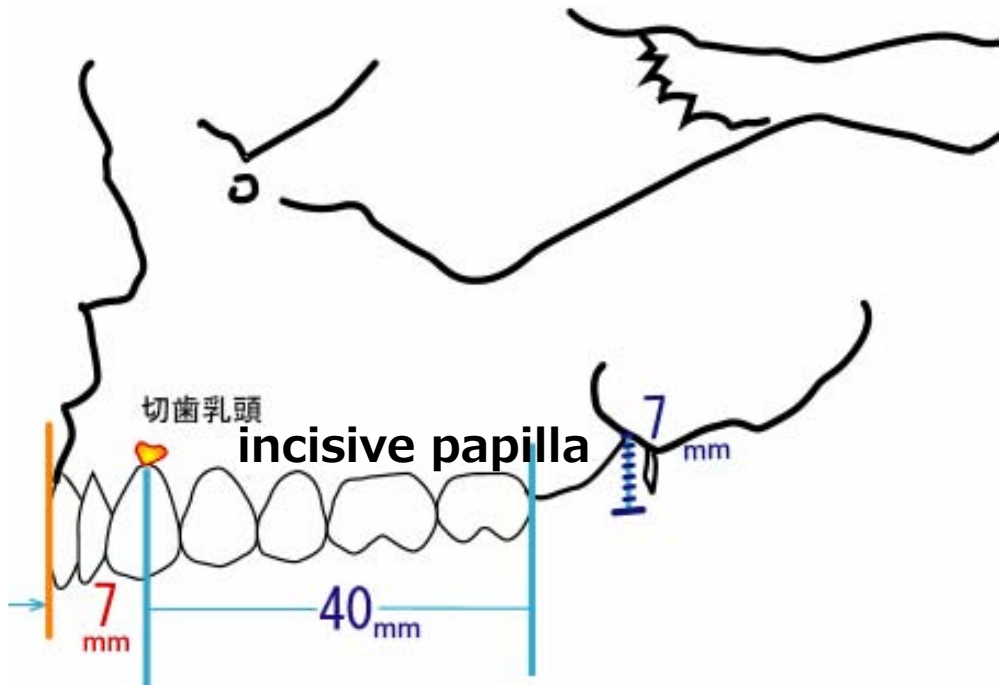


©All rights are reserved by
Eiji Tomita December 2014



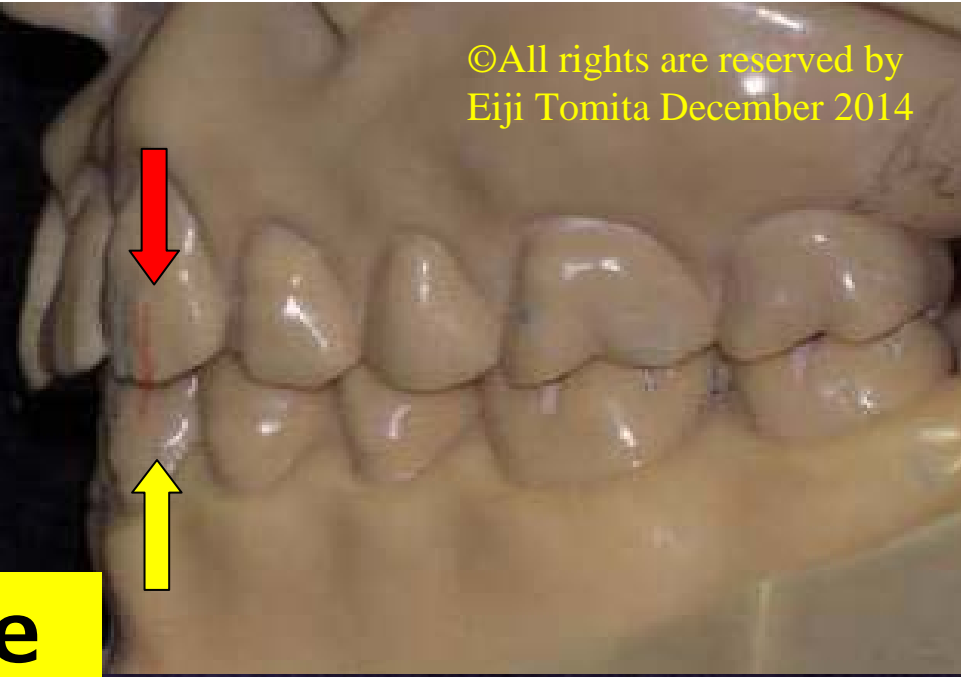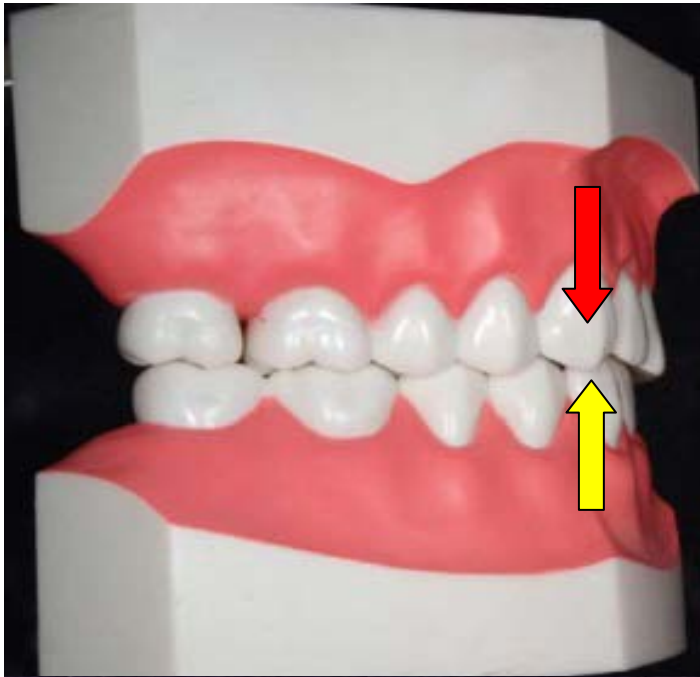




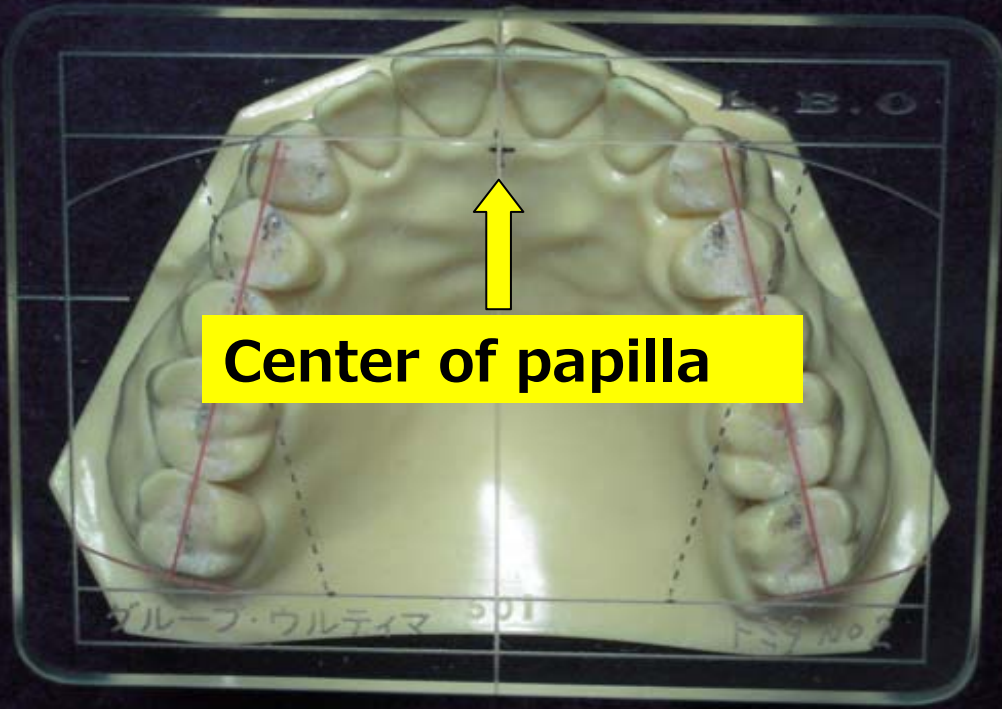


©All rights are reserved by Eiji Tomita December 2014

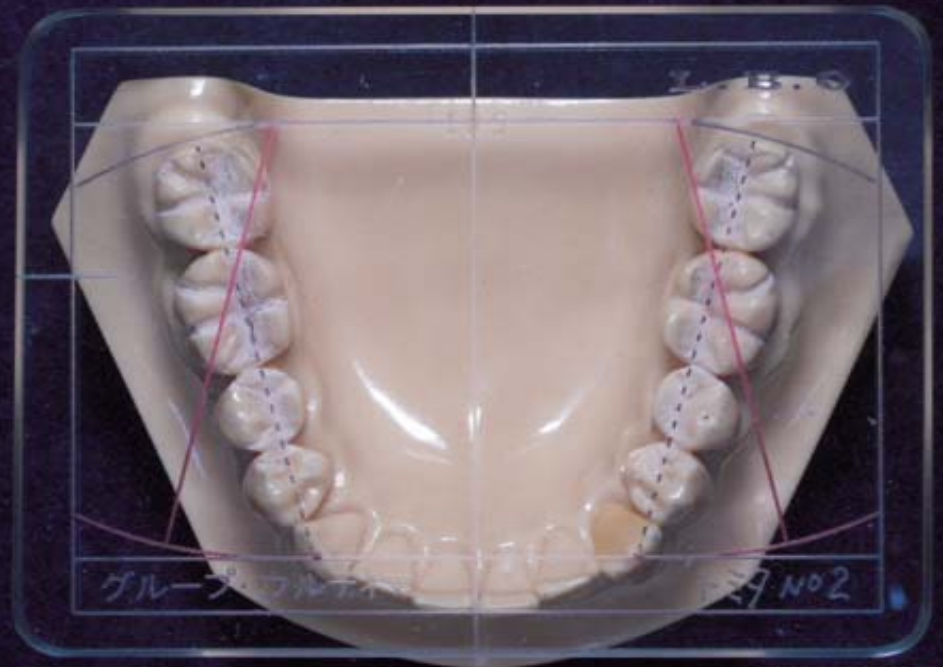©All rights are reserved by
Eiji Tomita December 2014



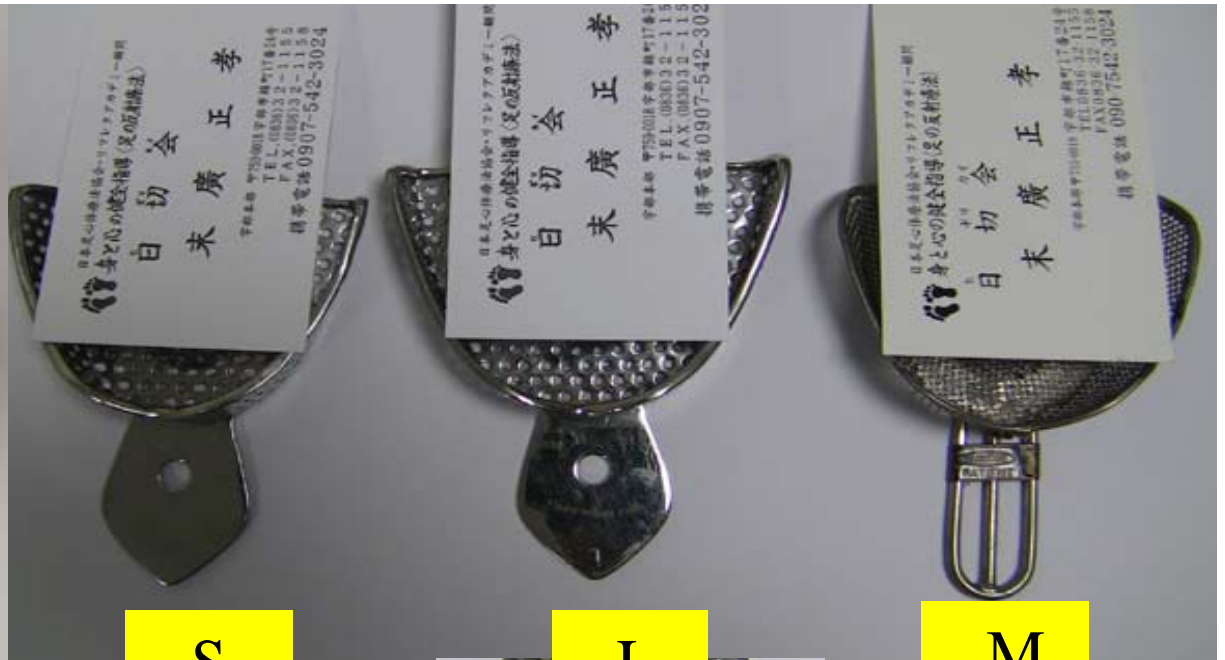Sideline



Center of papilla



©All rights are reserved by Eiji Tomita December 2014



S

L

M




Small size from other maker

Size 11 (Large) of COE



The handle and the part up to canine tooth



**Unidentified
complaint data**



Hagiwara Dentist



©All rights are reserved by
Eiji Tomita December 2014

経歴調査書

項目	内容
出生年月	
出生地	
学歴	
職業	
家族	
既往歴	
手術歴	
アレルギー	
現在病状	
検査結果	
治療経過	
予後	

福岡市博多区東区下道18-13
 扶原歯科医院
 扶原海蔵

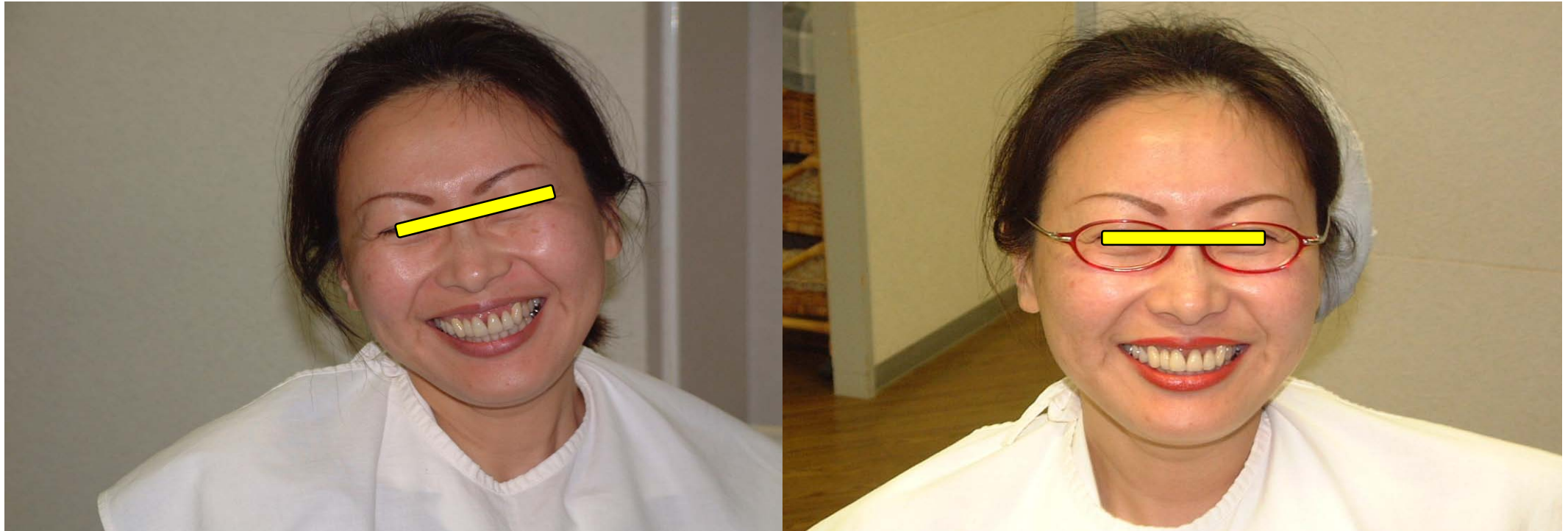一人の病状
 ①... 歯肉の腫れ...
 ②... 歯の痛み...
 ③... 歯の抜け...
 ④... 歯の着色...

歯肉病の診断

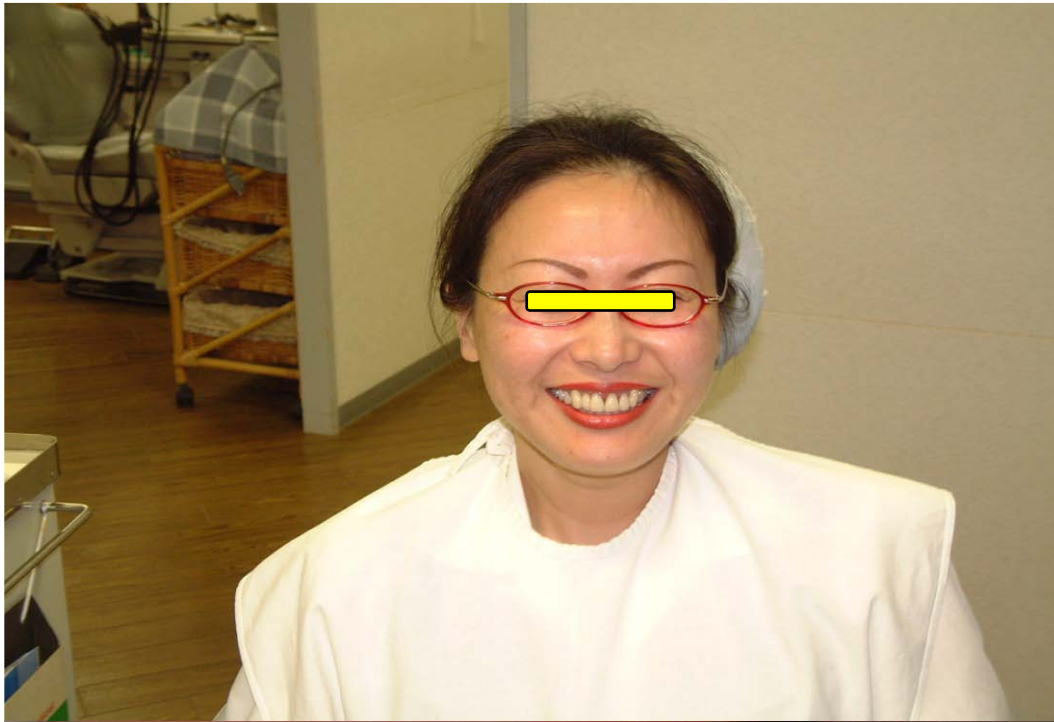
項目	程度	項目	程度
歯肉の腫れ	2/0	歯肉の退縮	0/0
歯肉の痛み	1/0	歯肉の出血	0/0
歯肉の色	2/0	歯肉の硬さ	0/0
歯肉の厚さ	2/0	歯肉の弾力	0/0
歯肉の形状	2/0	歯肉の位置	0/0
歯肉の質感	2/0	歯肉の色調	0/0
歯肉の温度	2/0	歯肉の湿度	0/0
歯肉の臭気	2/0	歯肉の味覚	0/0
歯肉の触覚	2/0	歯肉の痛覚	0/0
歯肉の知覚	2/0	歯肉の温度覚	0/0
歯肉の運動	2/0	歯肉の湿度覚	0/0
歯肉の反射	2/0	歯肉の痛覚覚	0/0
歯肉の調節	2/0	歯肉の温度覚覚	0/0
歯肉の維持	2/0	歯肉の湿度覚覚	0/0
歯肉の保護	2/0	歯肉の痛覚覚覚	0/0
歯肉の修復	2/0	歯肉の温度覚覚覚	0/0
歯肉の再生	2/0	歯肉の湿度覚覚覚	0/0
歯肉の老化	2/0	歯肉の痛覚覚覚覚	0/0
歯肉の死亡	2/0	歯肉の温度覚覚覚覚	0/0

福岡市博多区東区下道18-13
 扶原歯科医院
 扶原海蔵

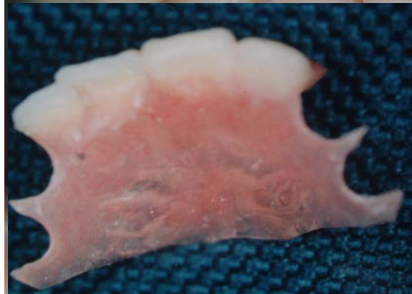
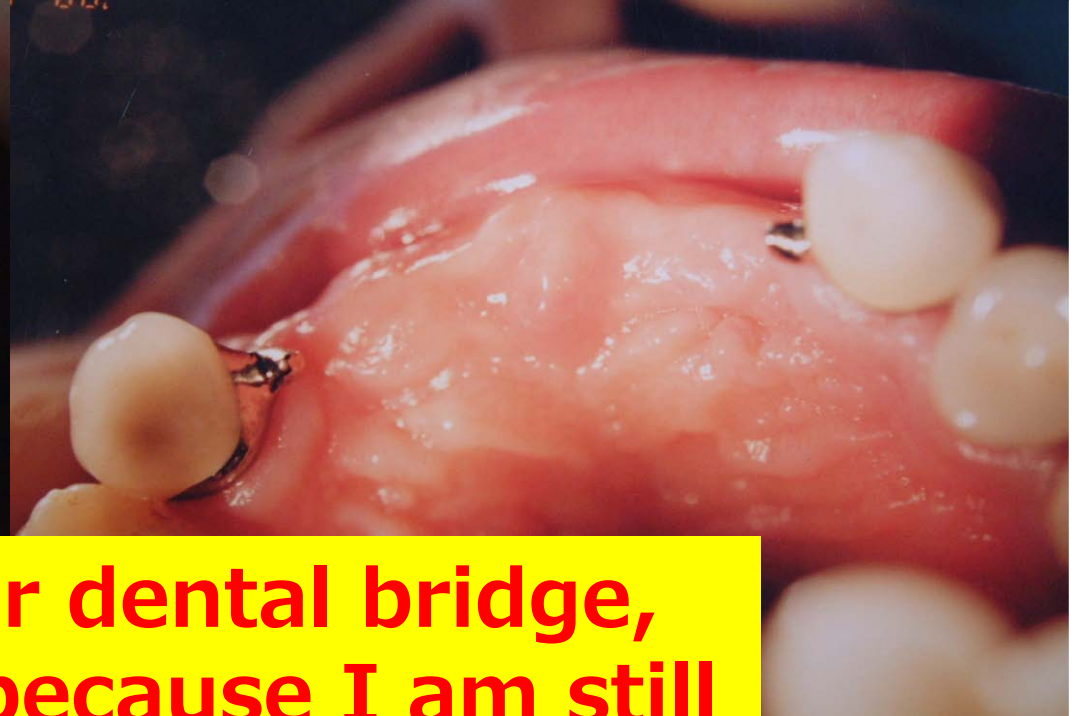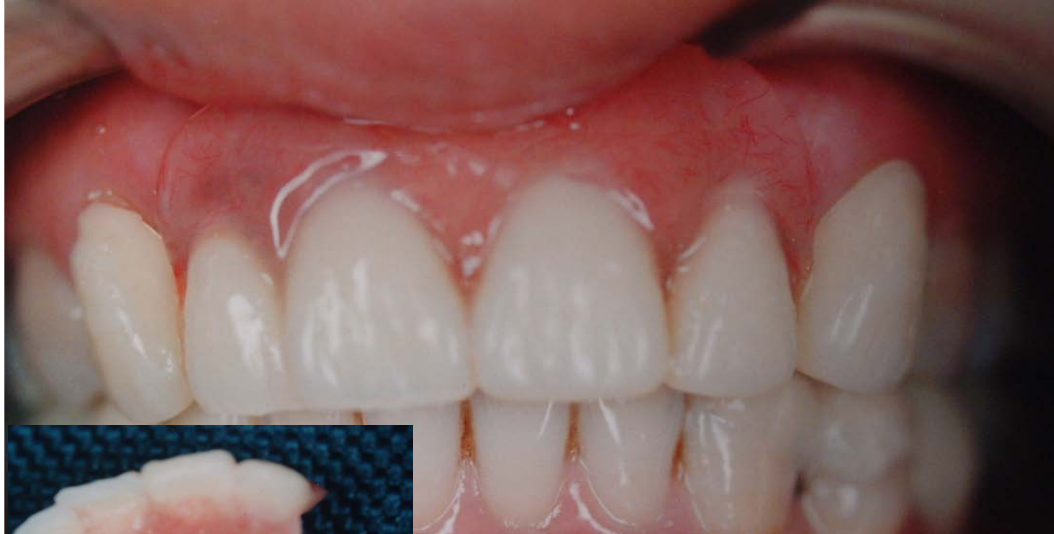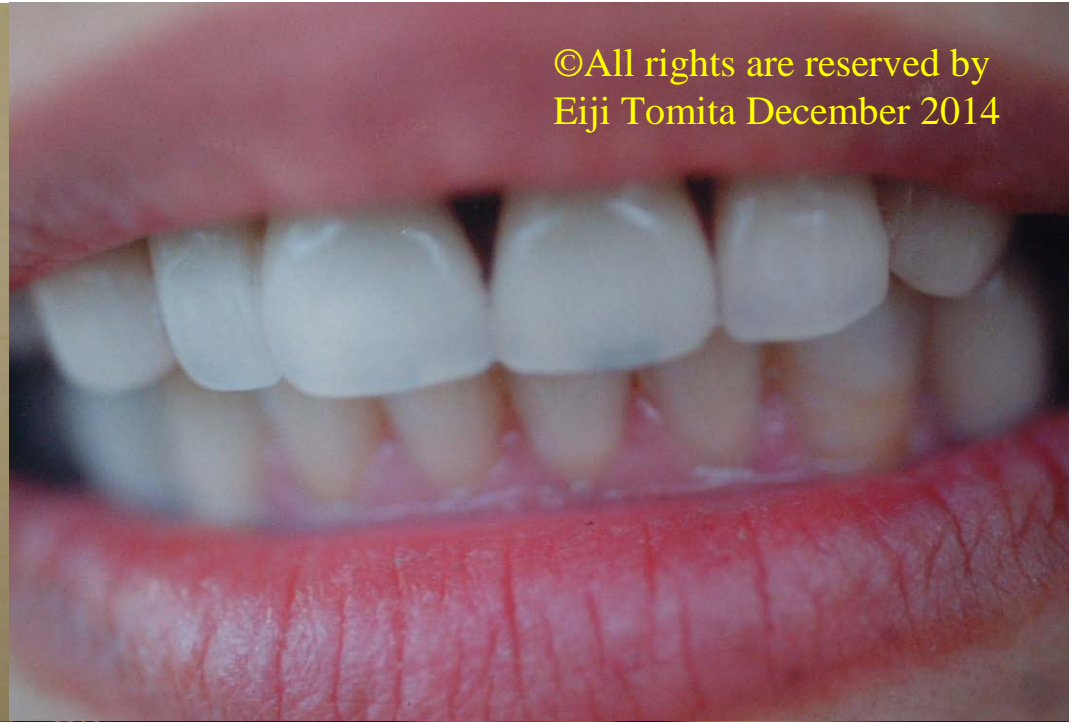©All rights are reserved by
 Eiji Tomita December 2014



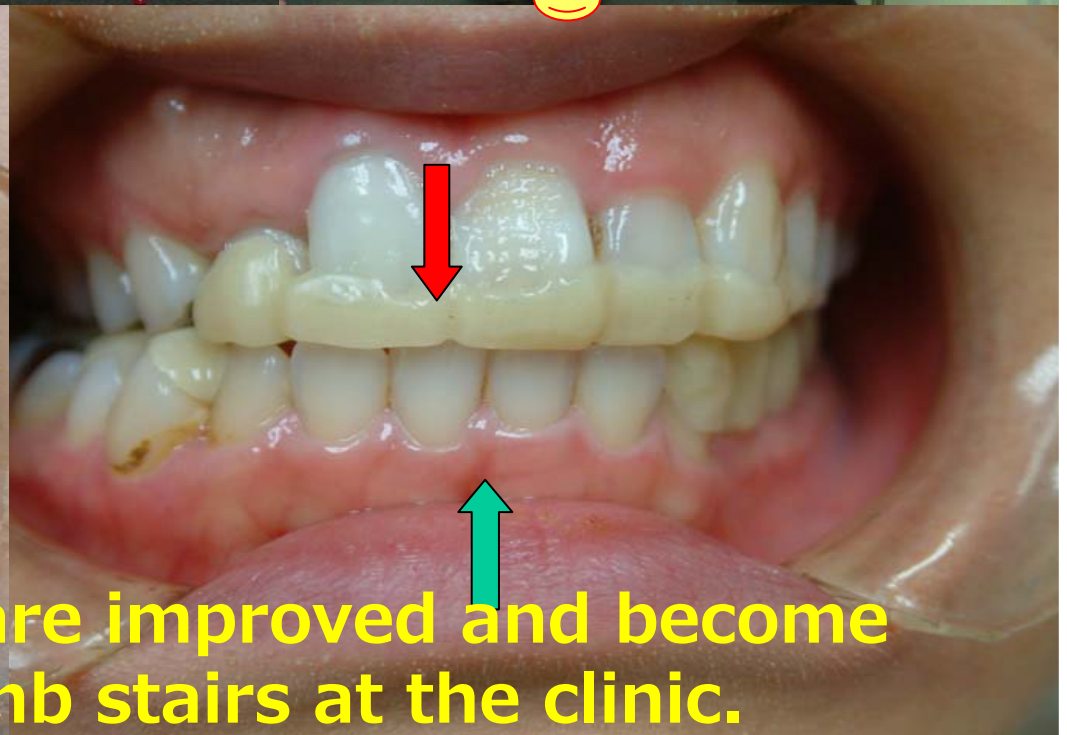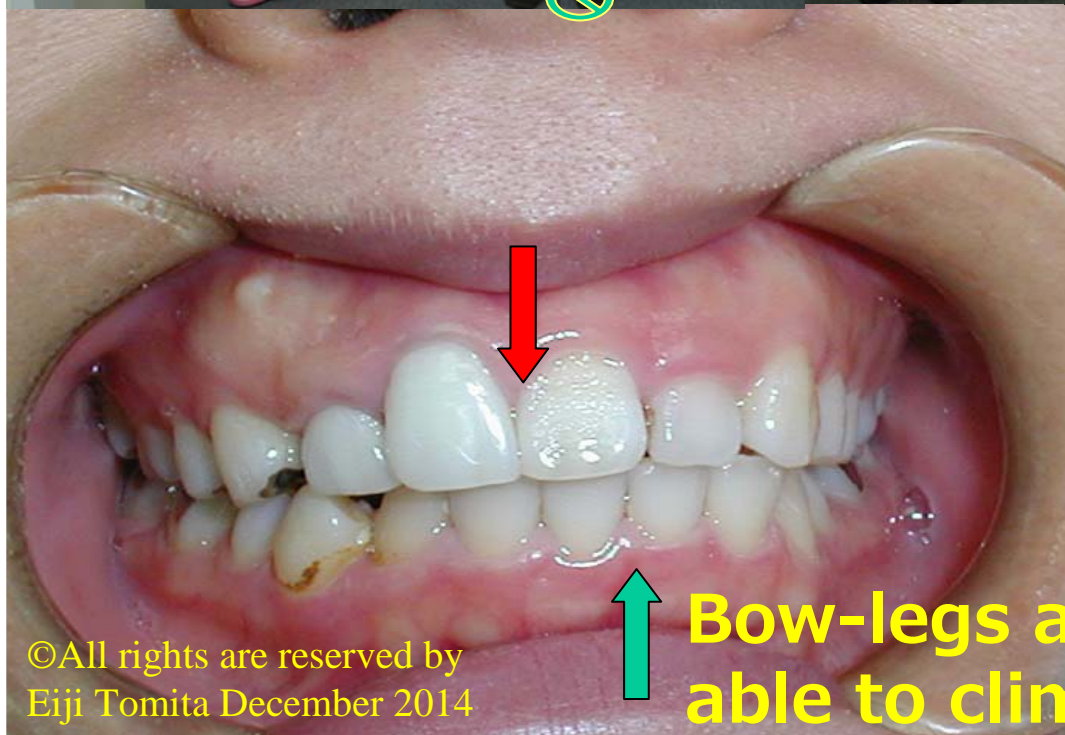
**Lockjaw (fixed in approx. 5 minutes),
insomnia, cramps, stiff shoulder,
backache, emotional instability,
reduced exercise capacity, tired
feeling from the morning**



©All rights are reserved by
Eiji Tomita December 2014

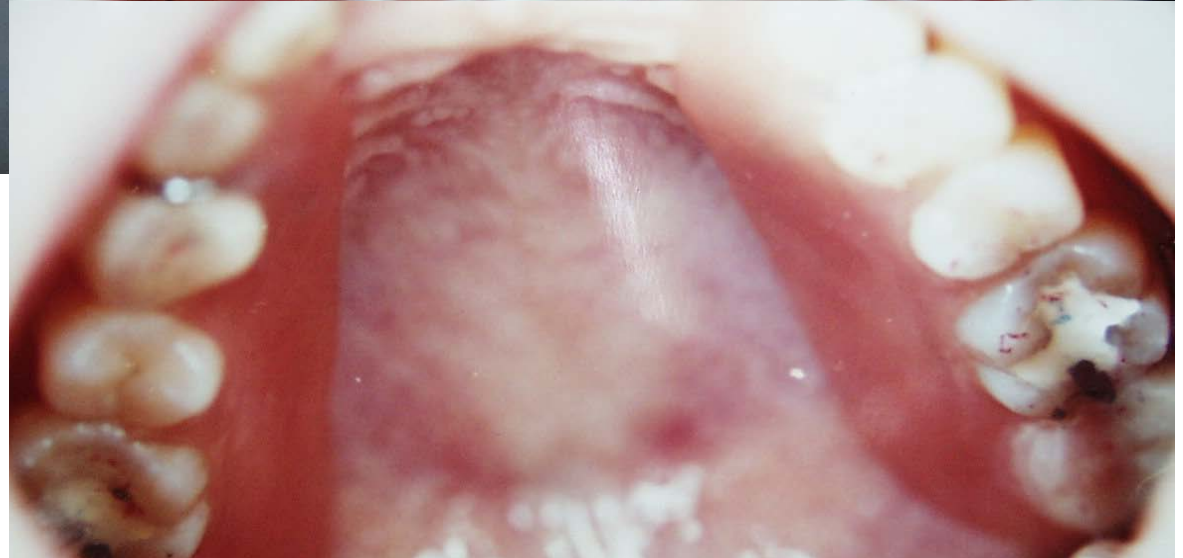
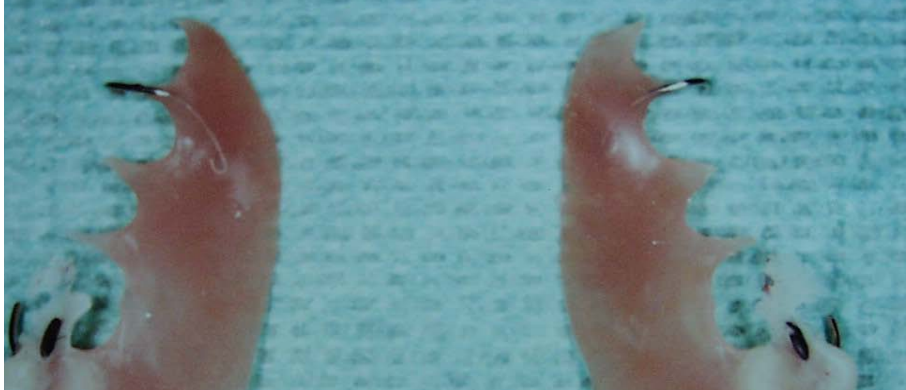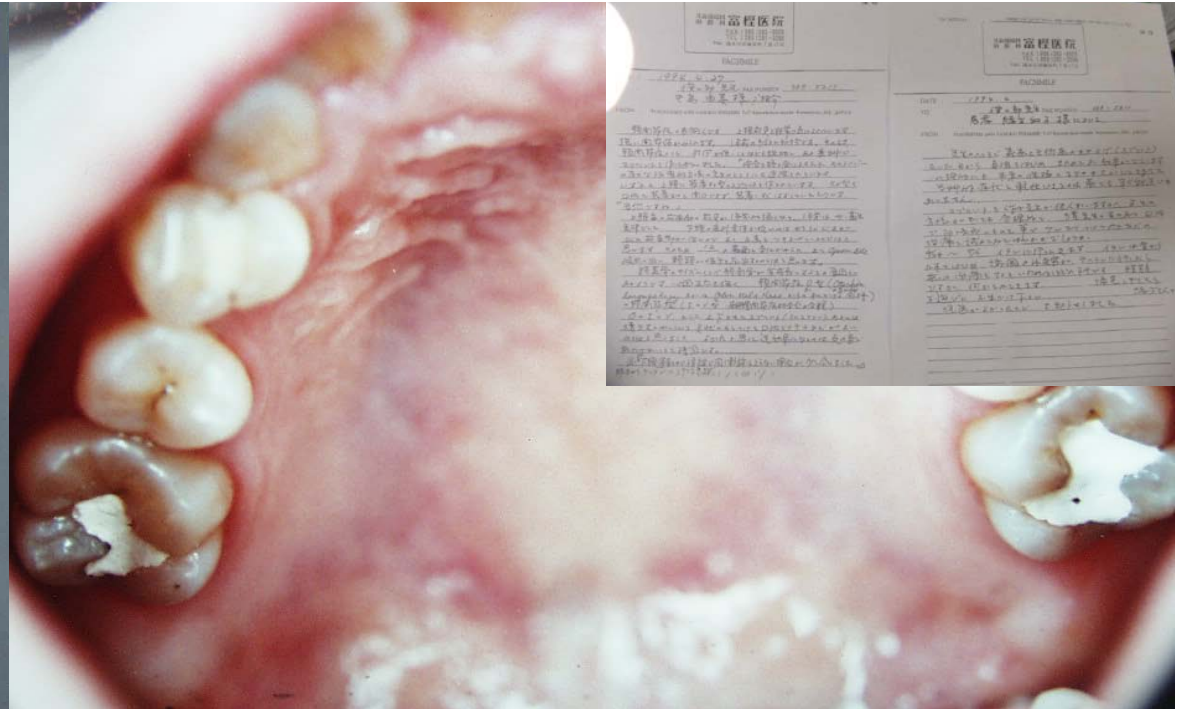

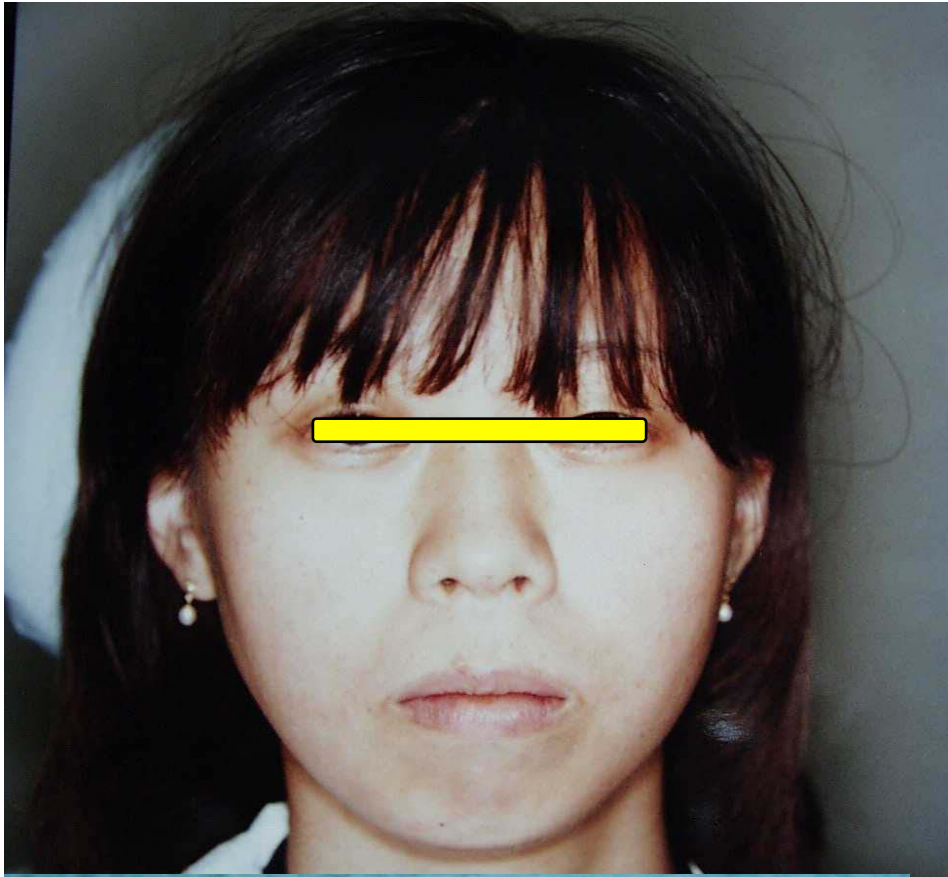
**I want to wear dental bridge,
not denture, because I am still**



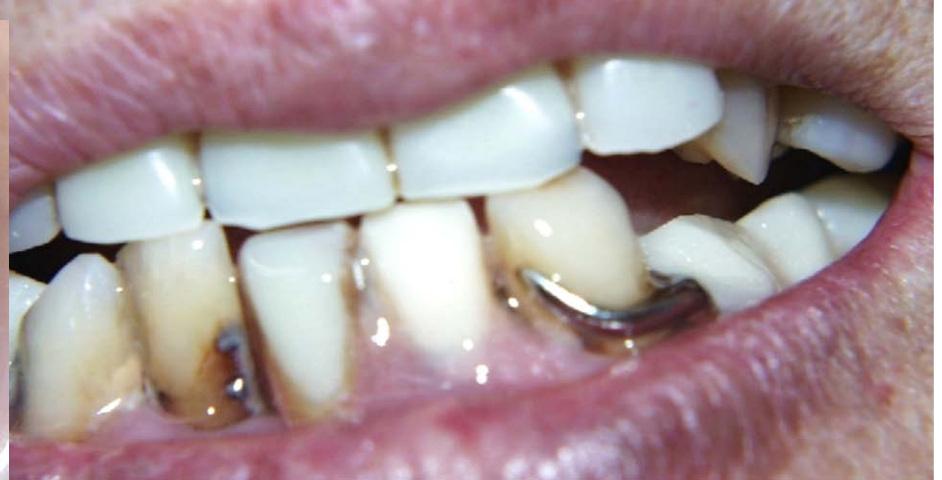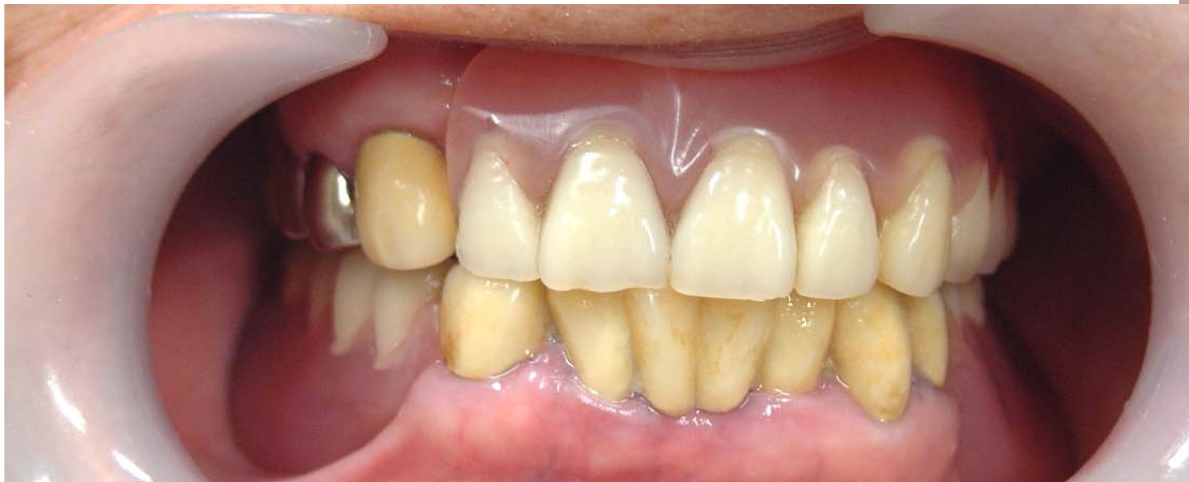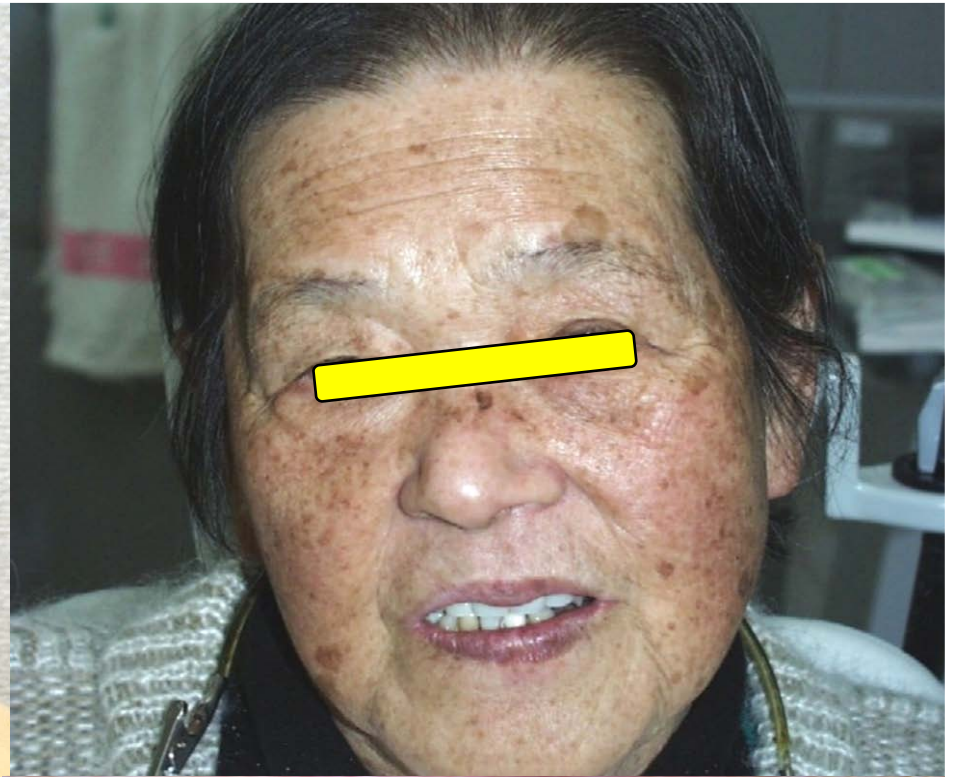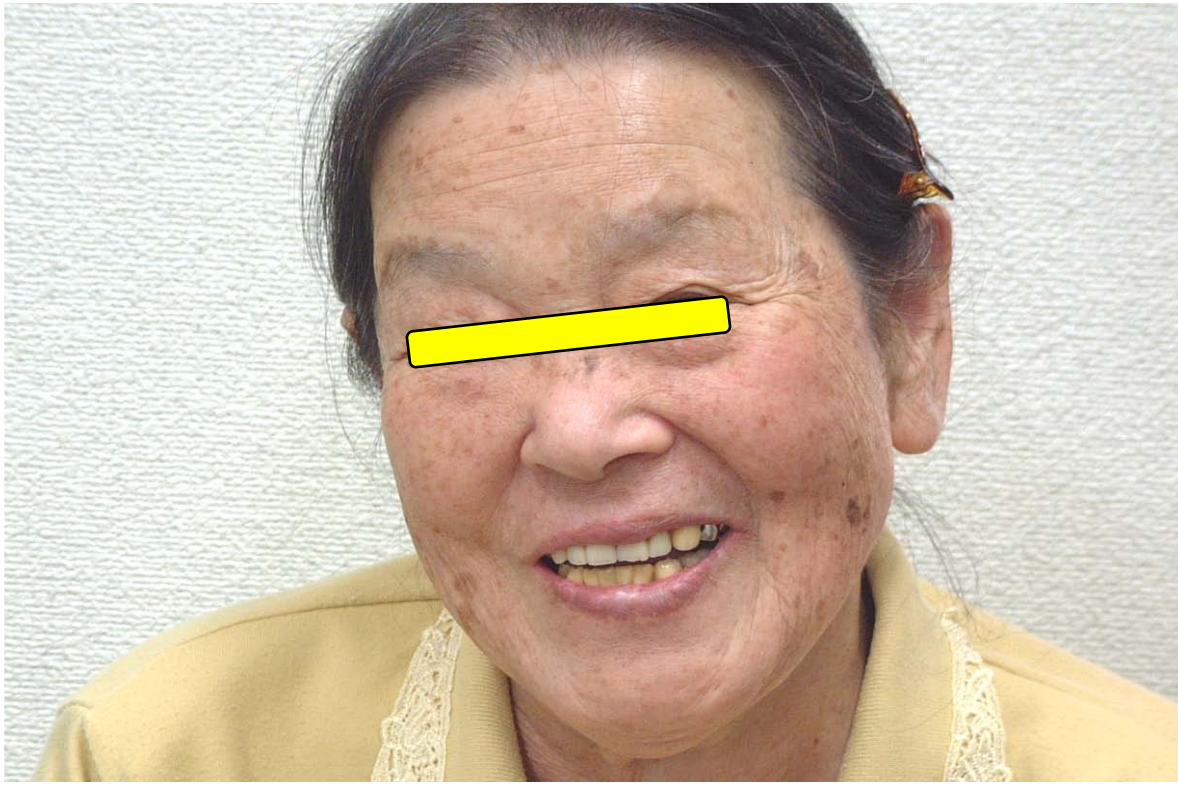
©All rights are reserved by
Eiji Tomita December 2014

**Bow-legs are improved and become
able to climb stairs at the clinic.**



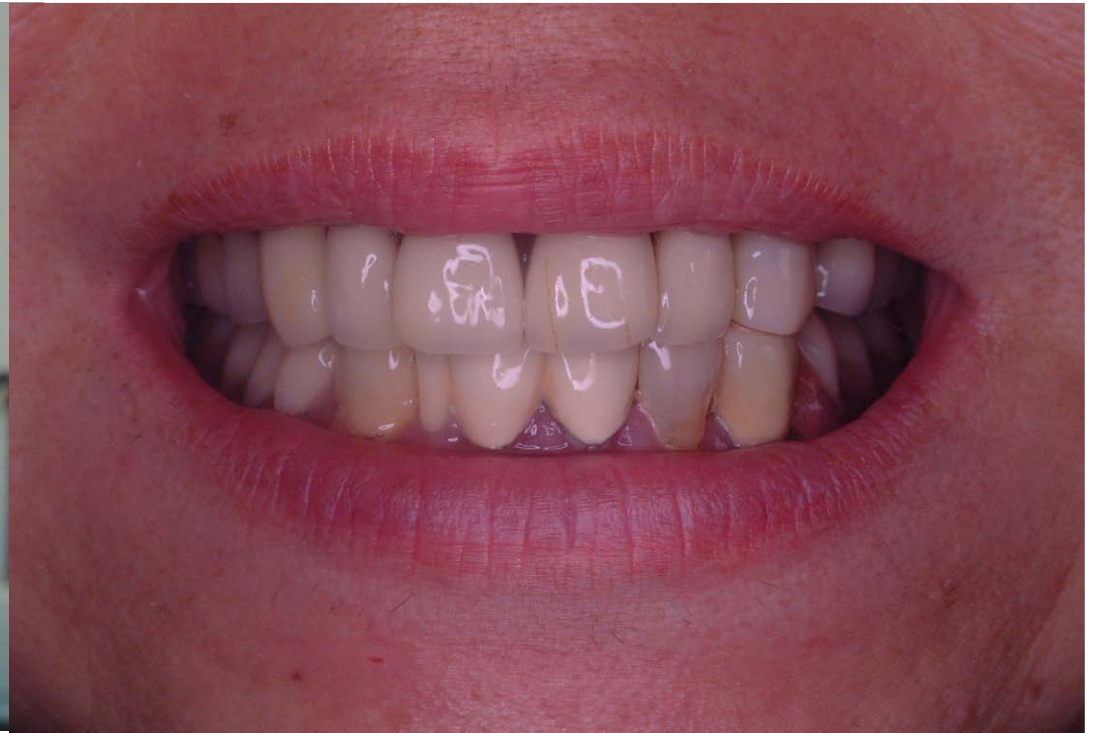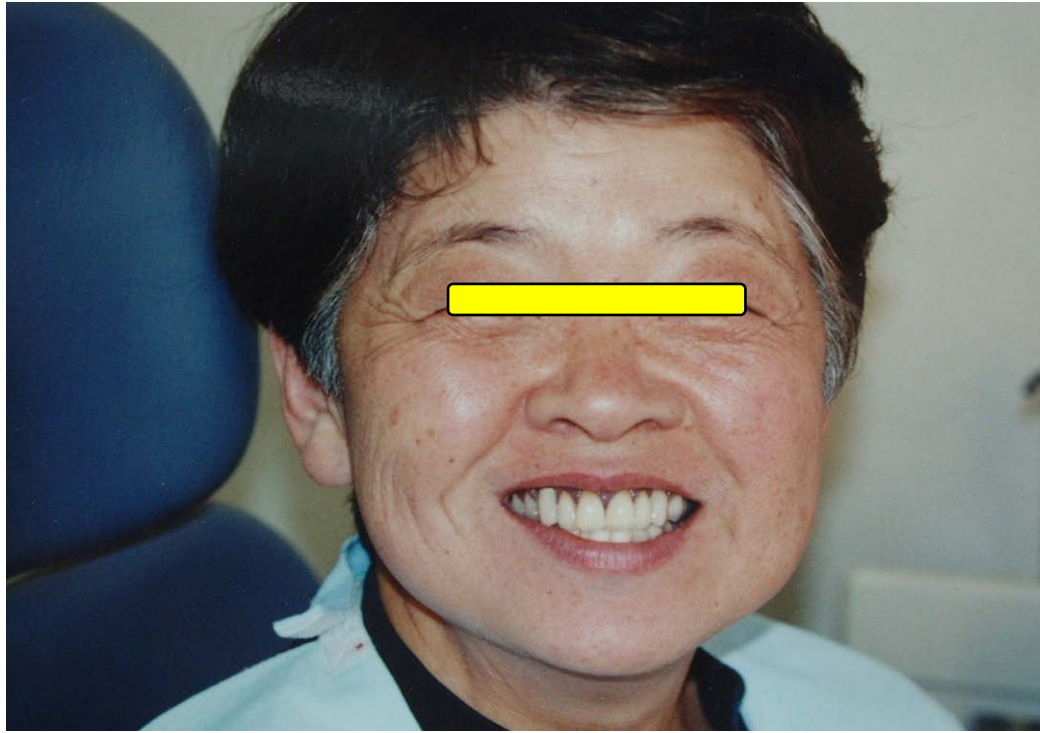
Removed seventh maxillary tooth and became sudden deafness.

©All rights are reserved by Eiji Tomita December 2014

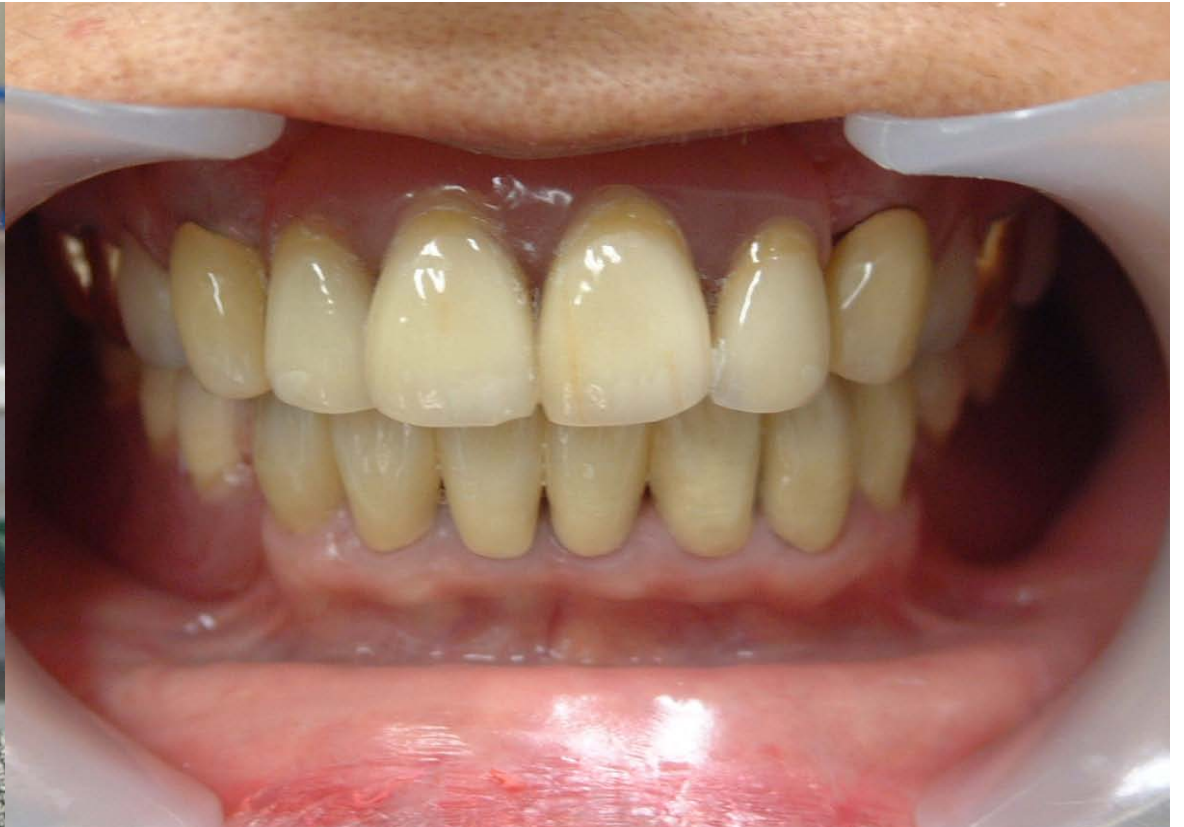
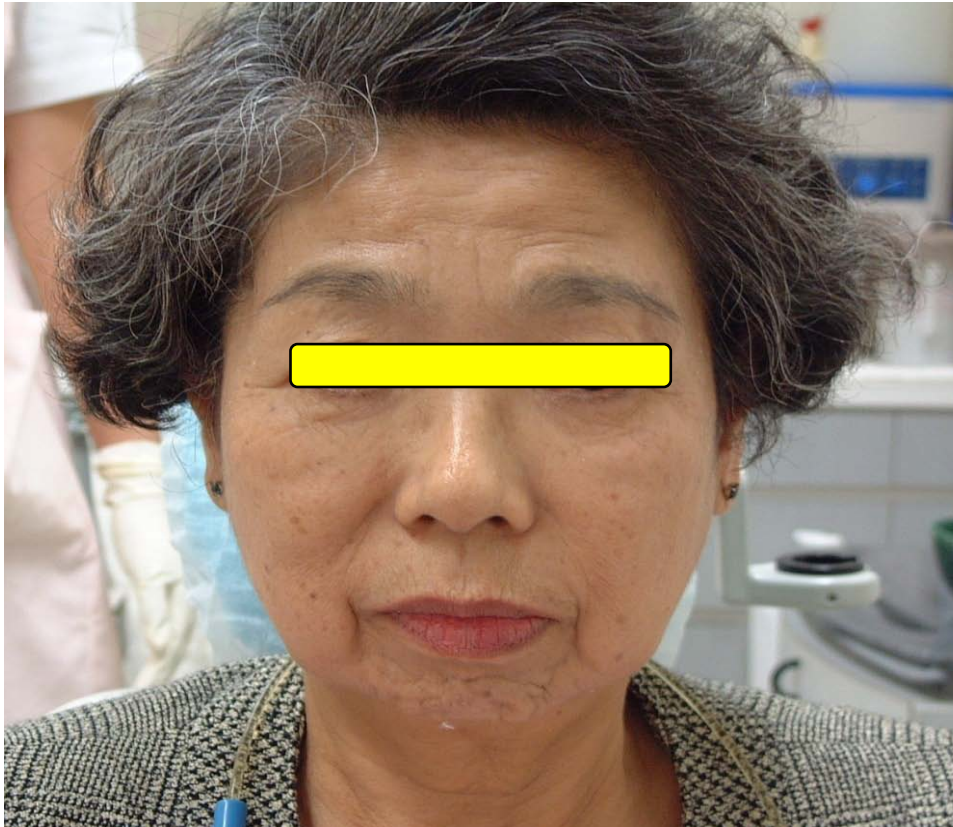
I was experiencing dementia

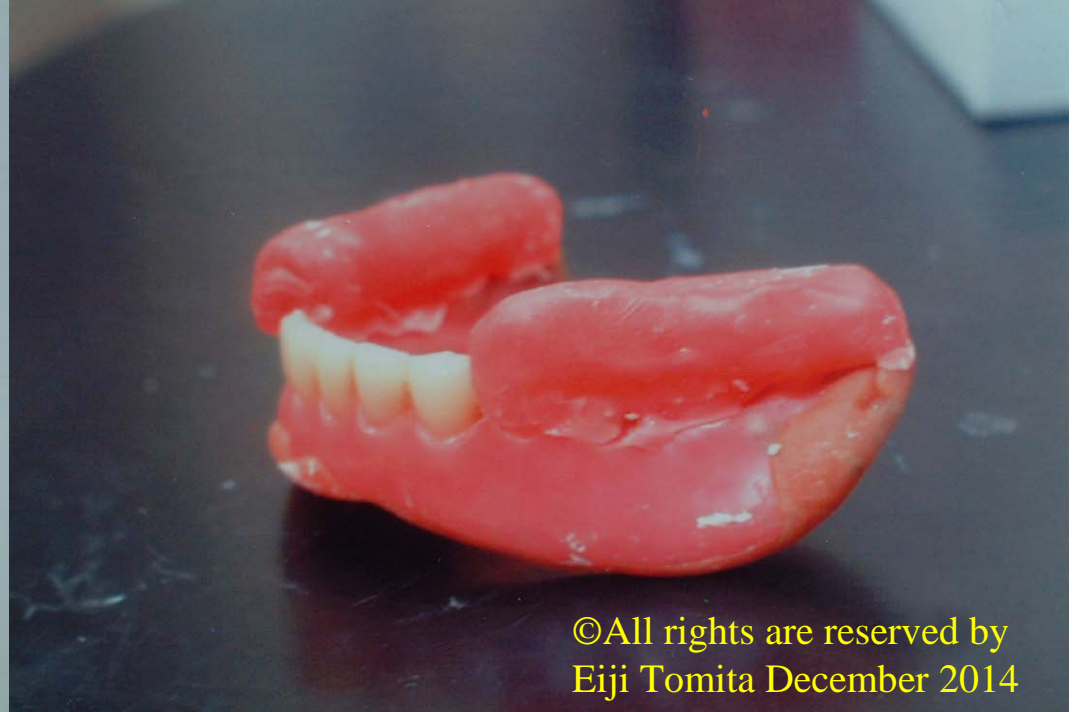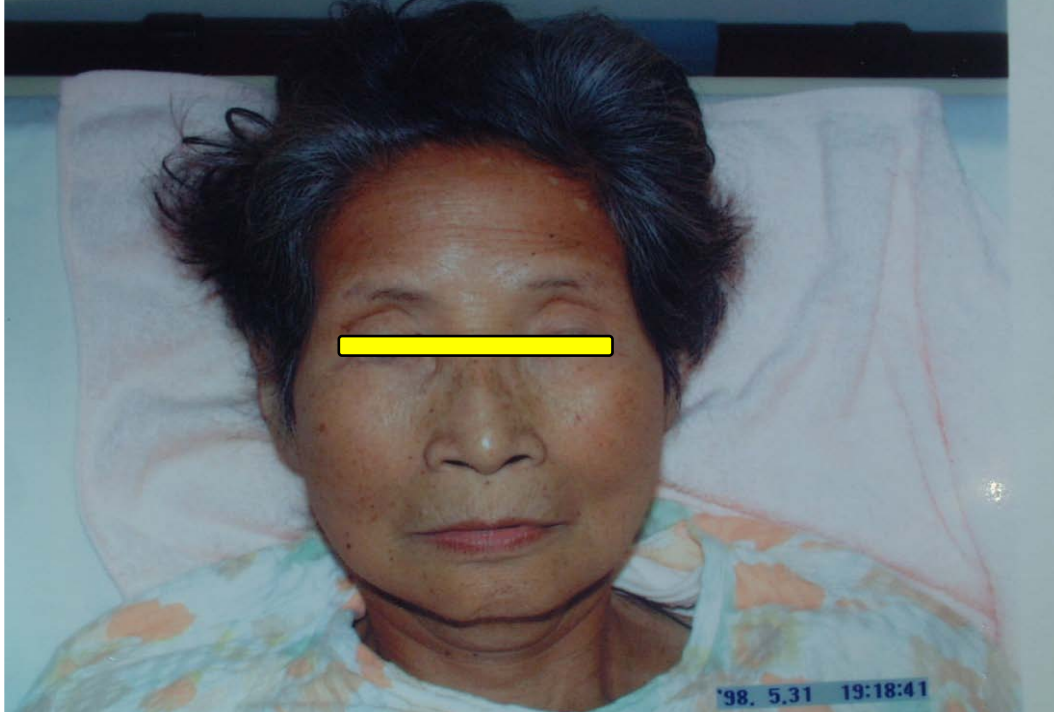
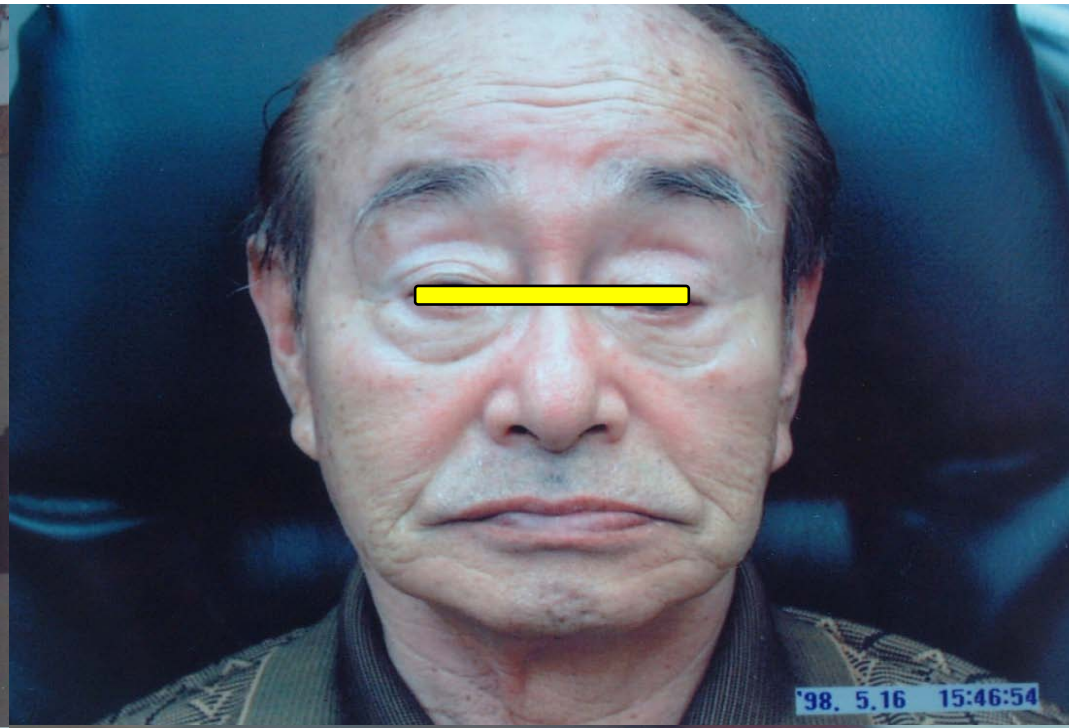
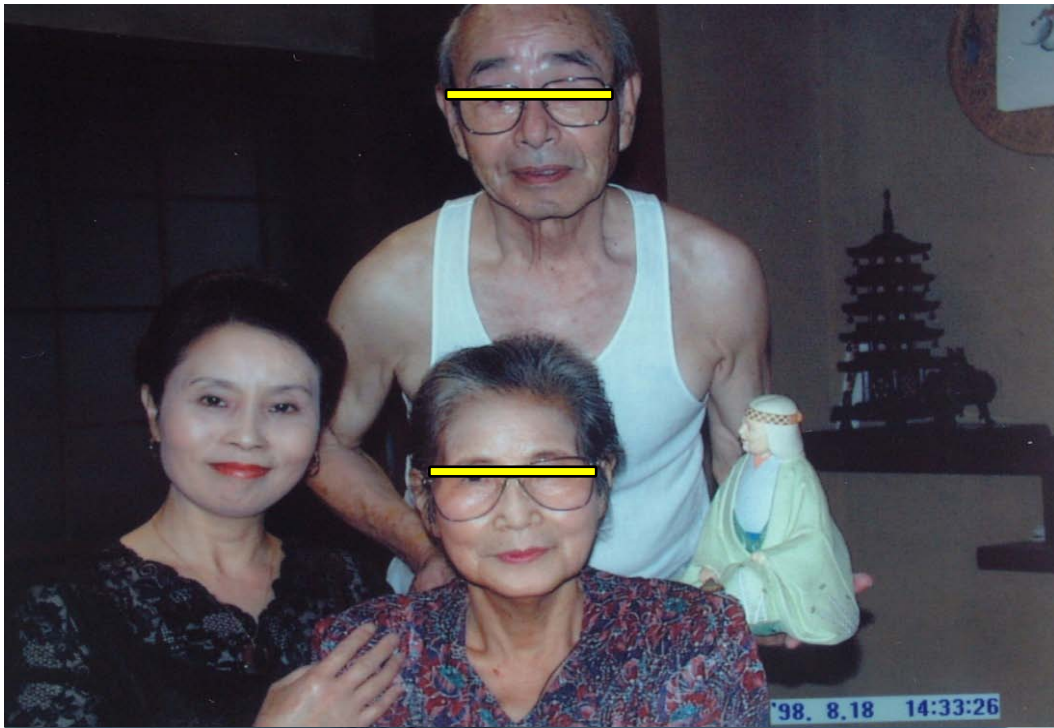
©All rights are reserved by
Eiji Tomita December 2014

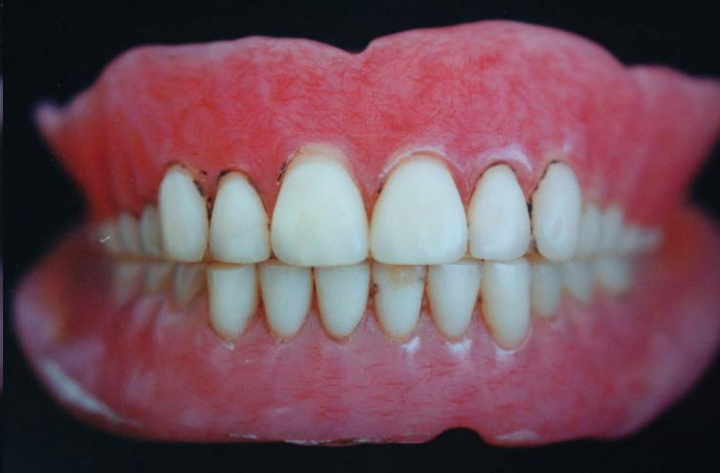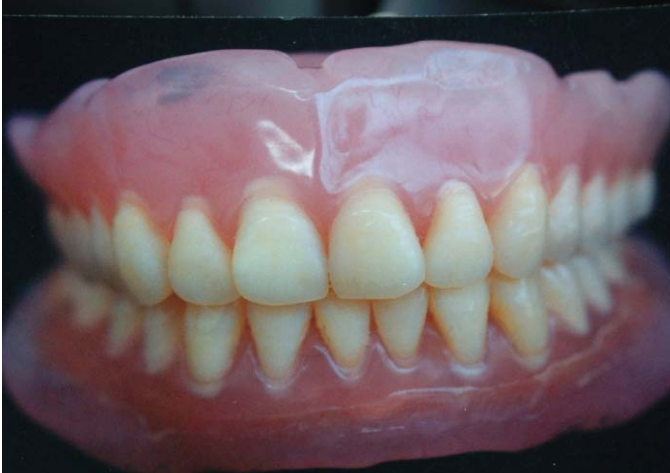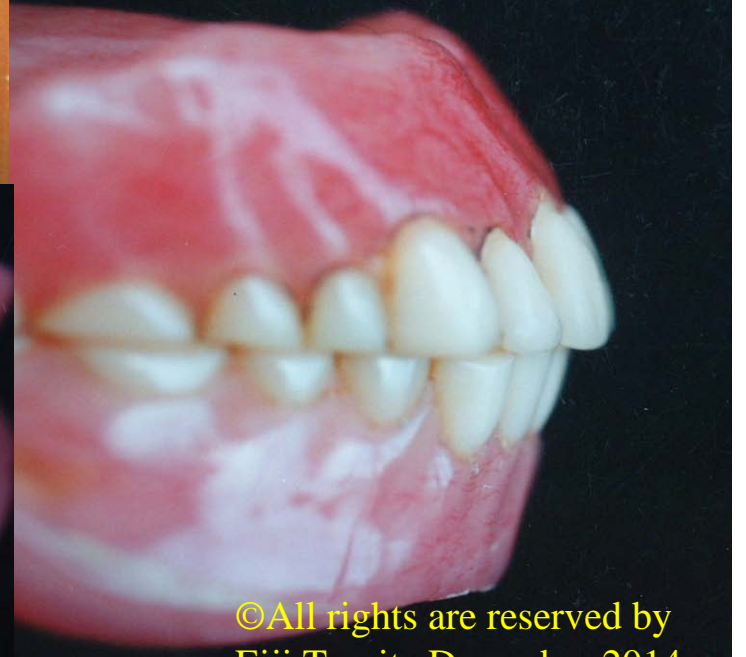


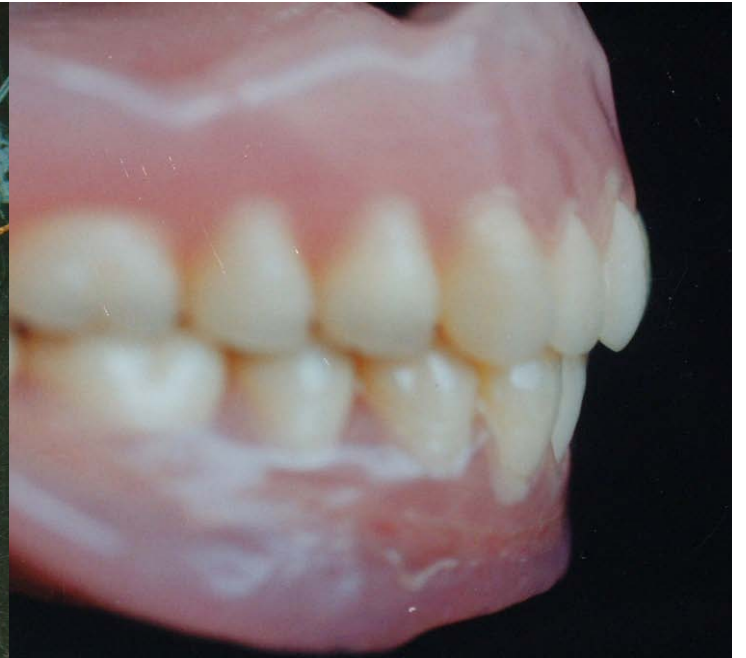
**I feel better and do not
fall over now**

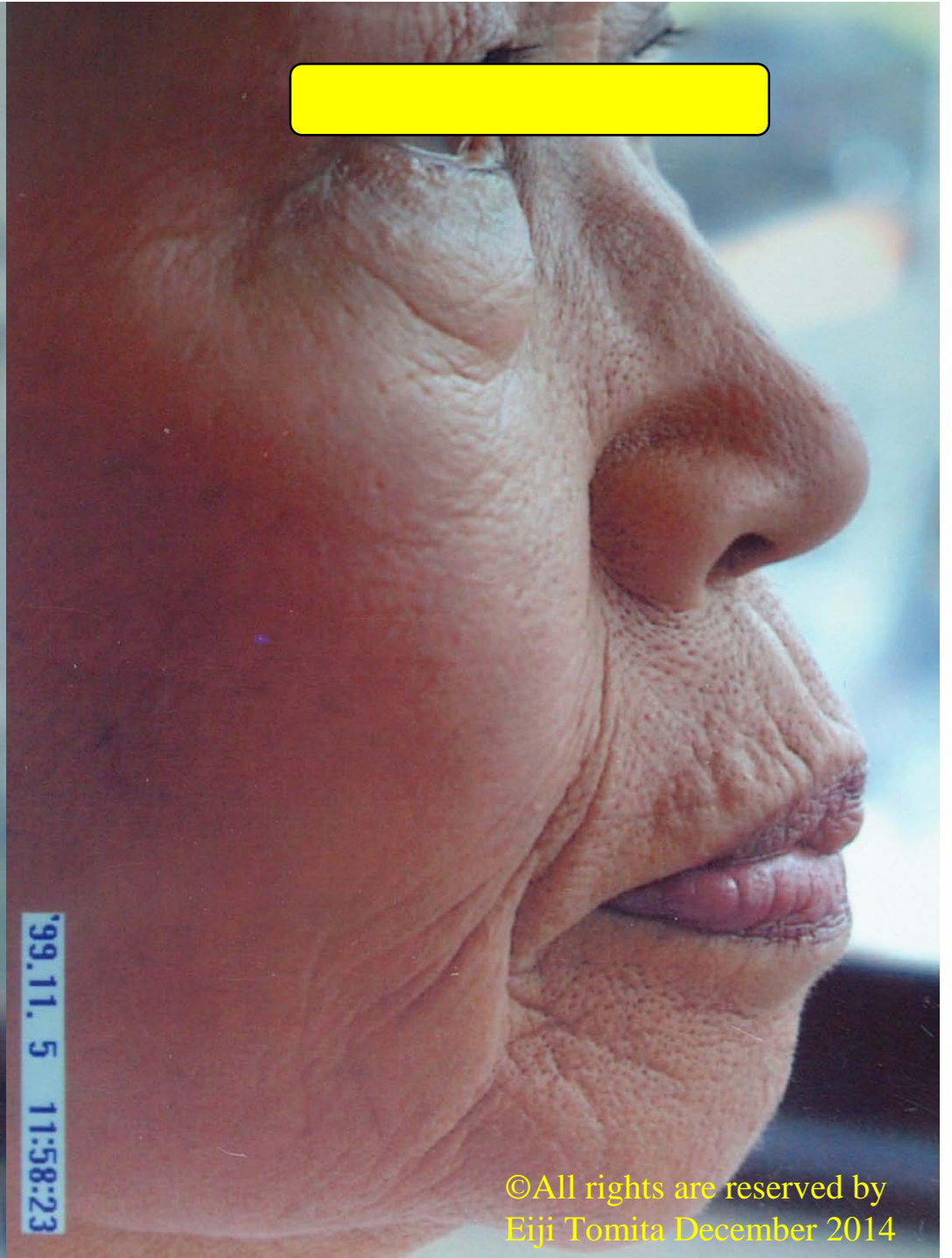
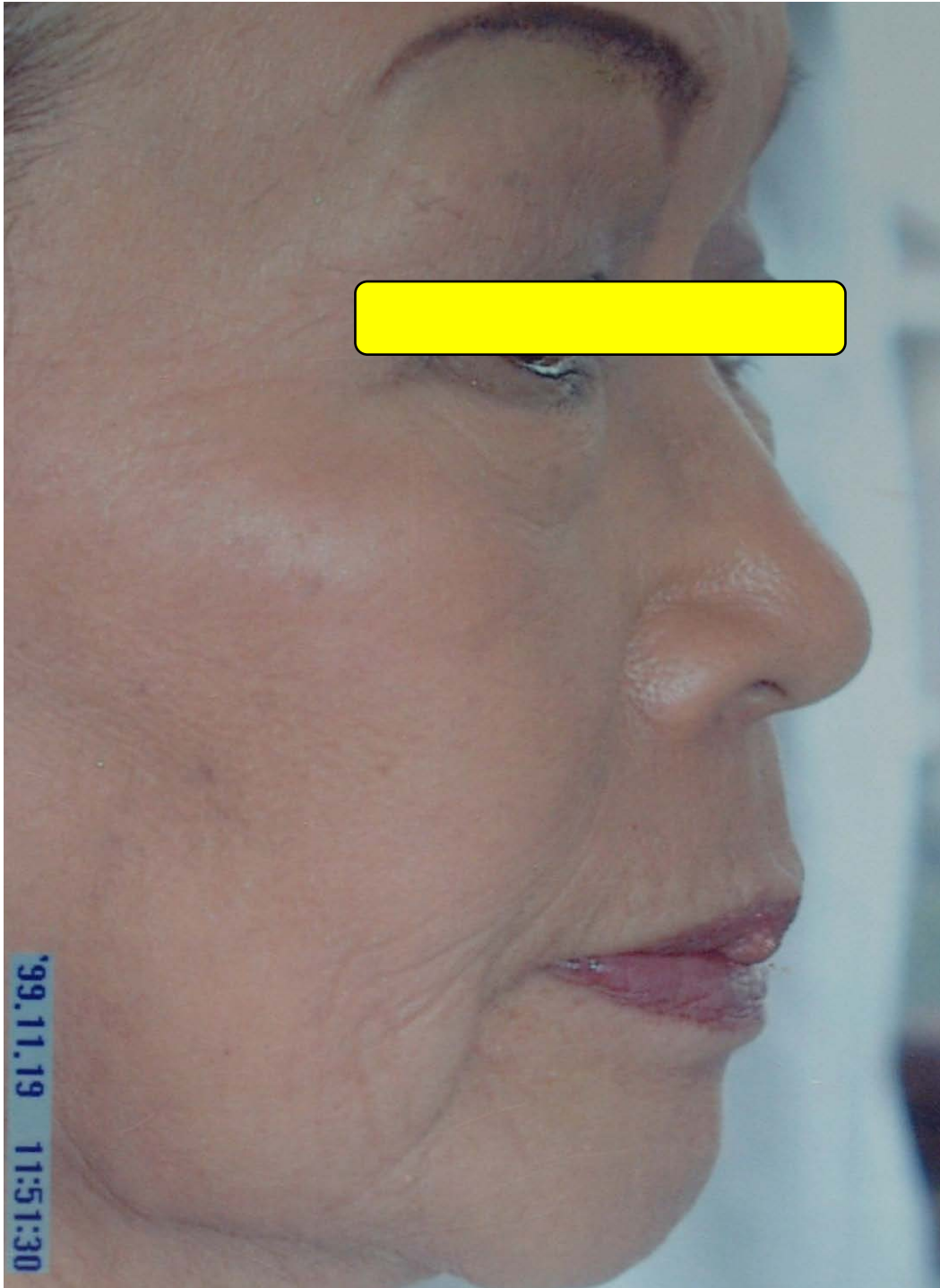
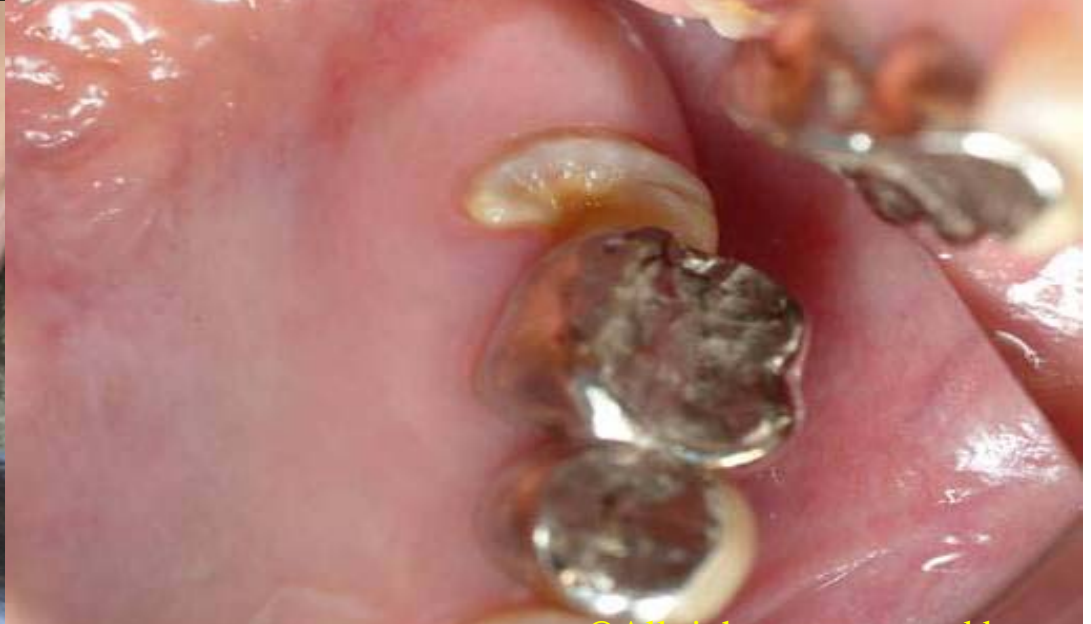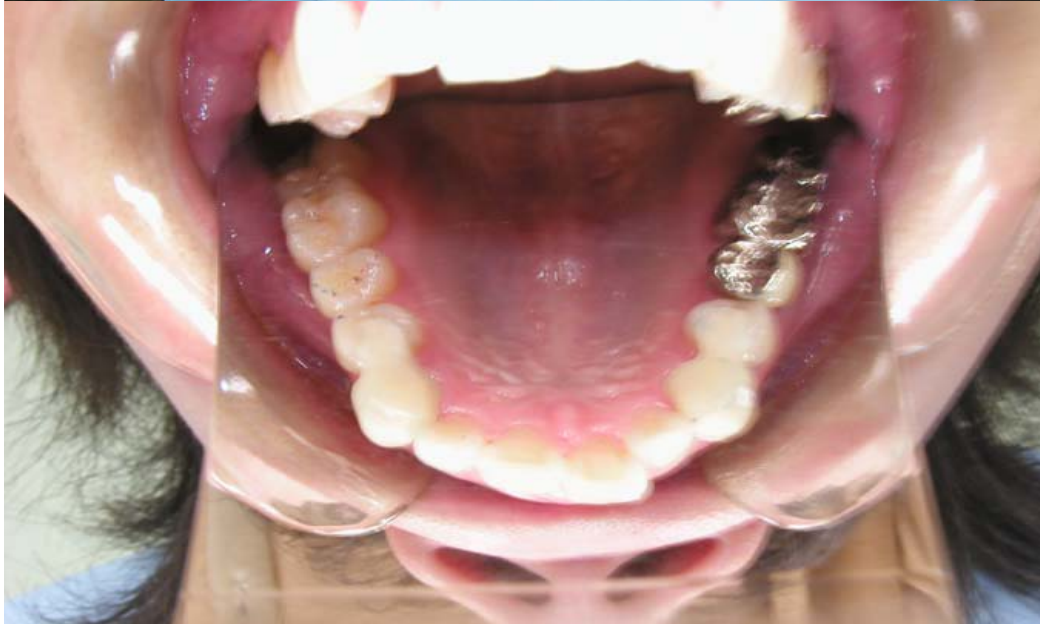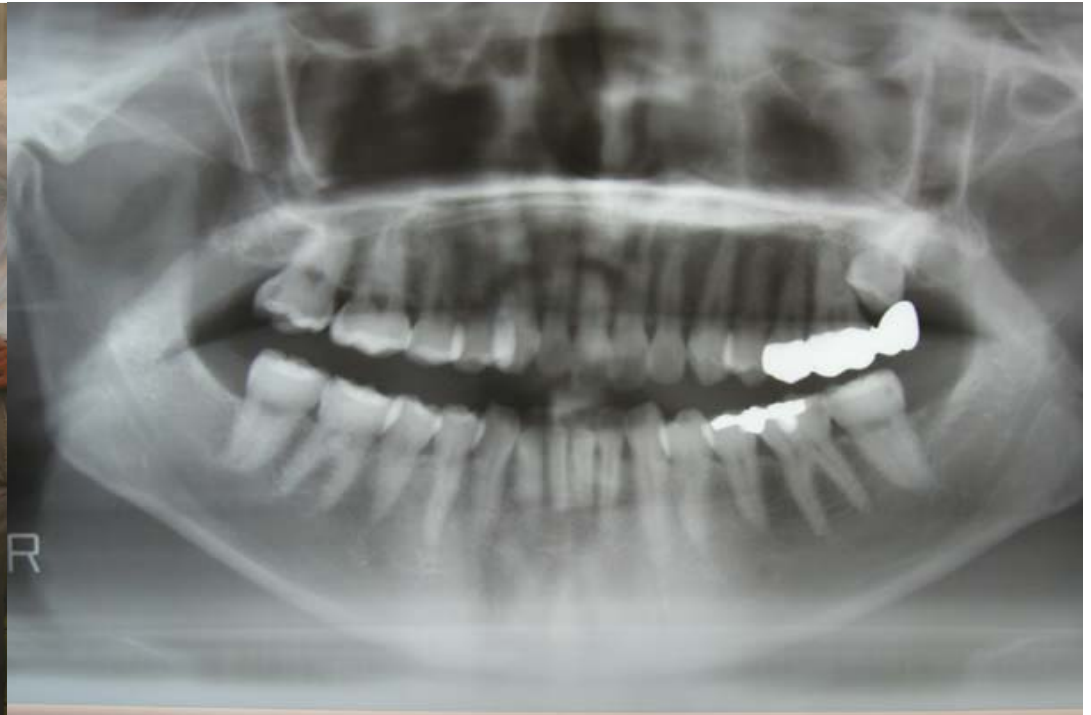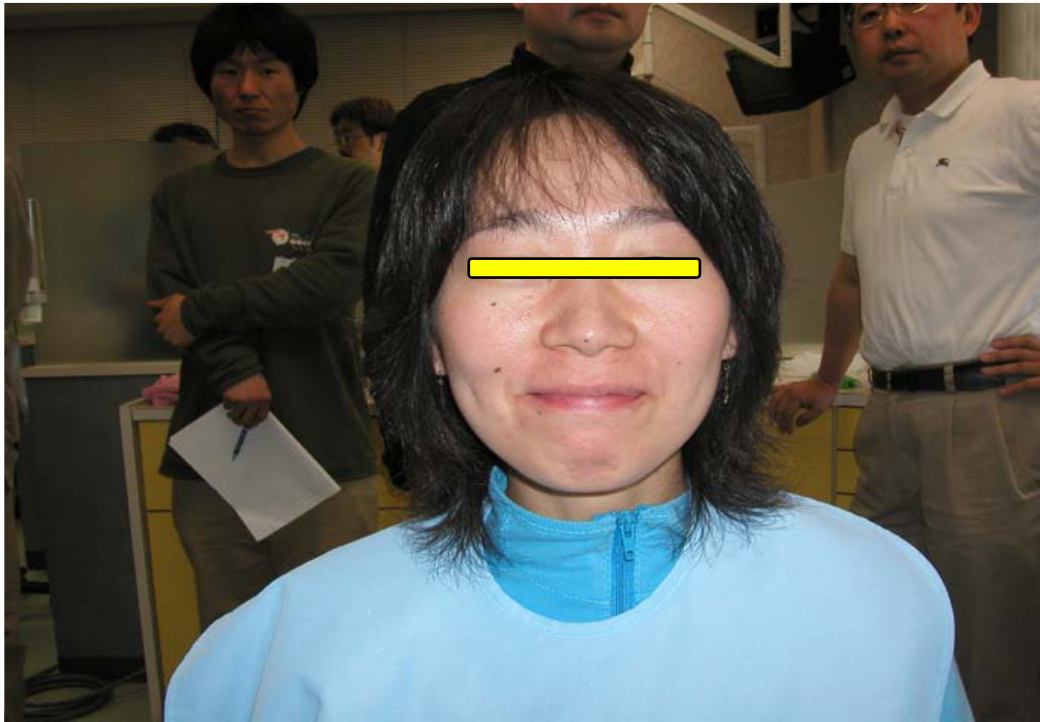
**I feel good and have my
jaw back**





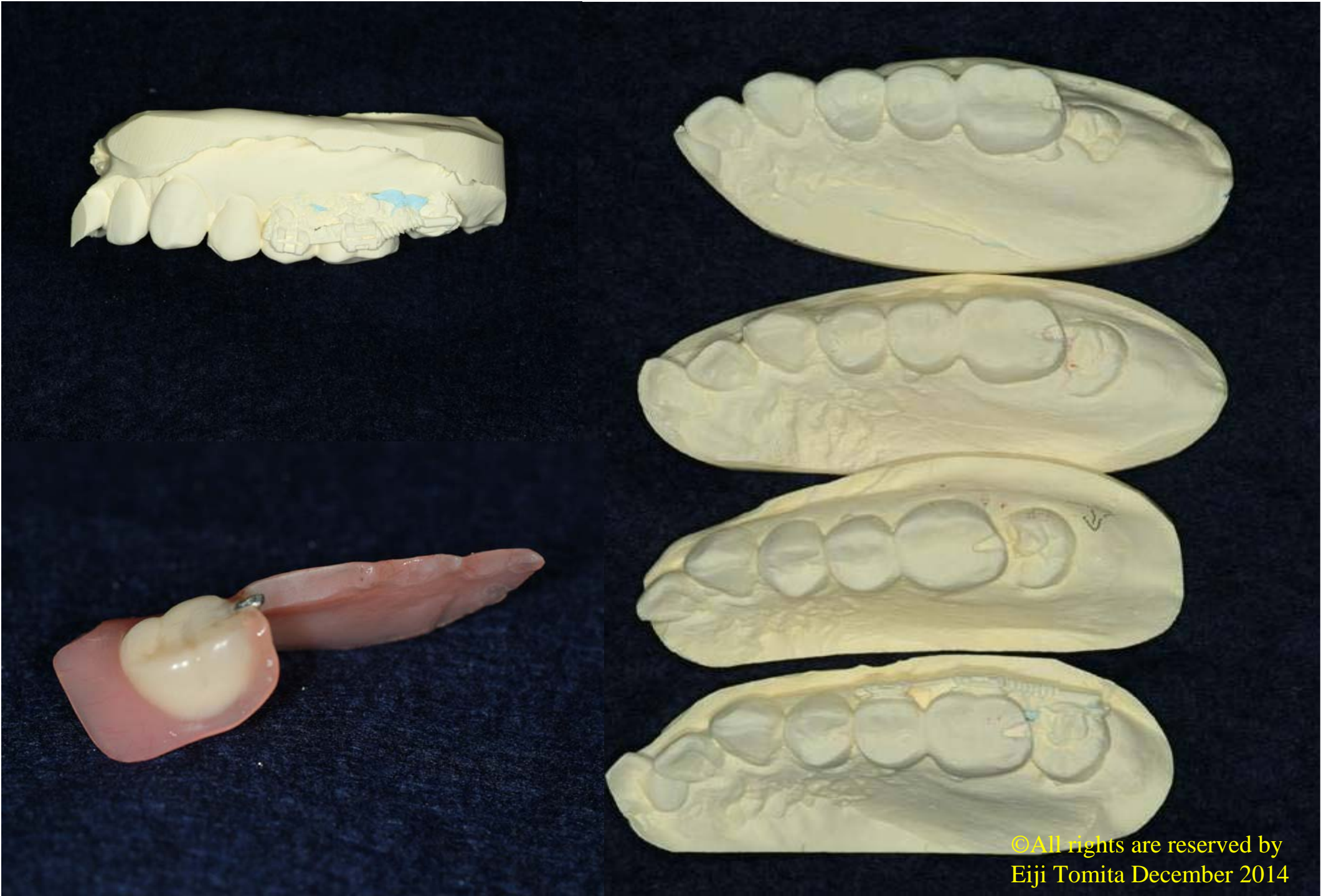©All rights are reserved by
Eiji Tomita December 2014





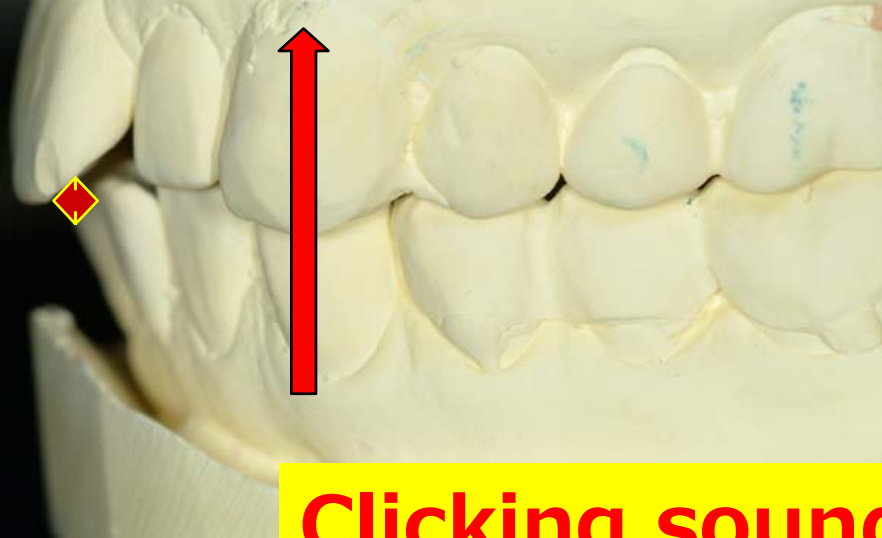Clicking sound disappears immediately

©All rights are reserved by
Eiji Tomita December 2014

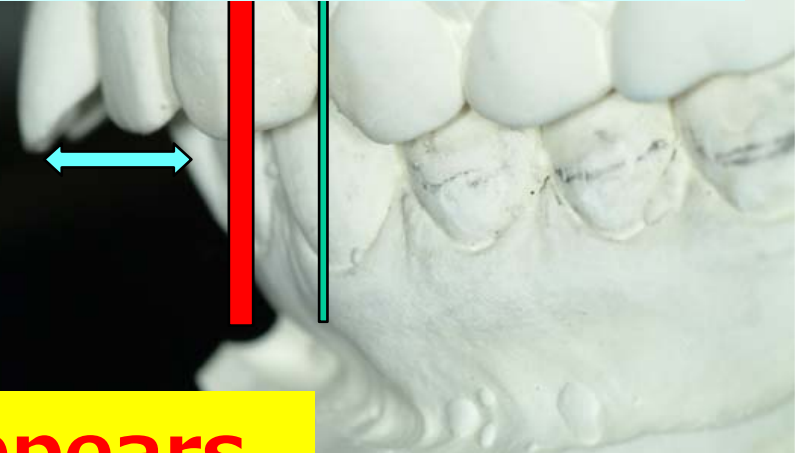


©All rights are reserved by
Eiji Tomita December 2014

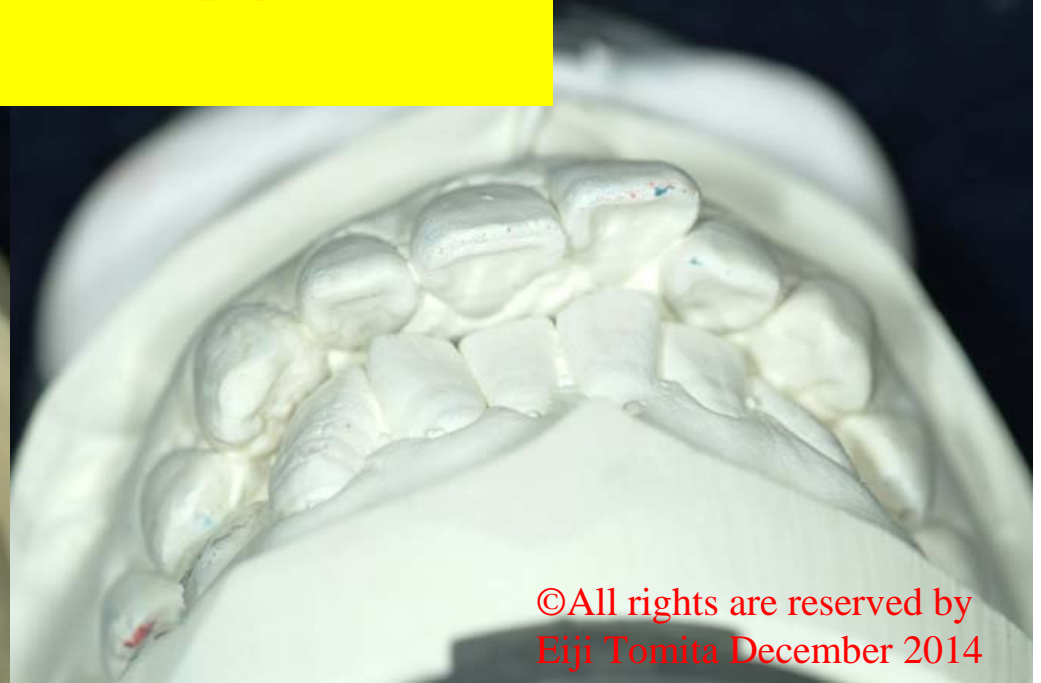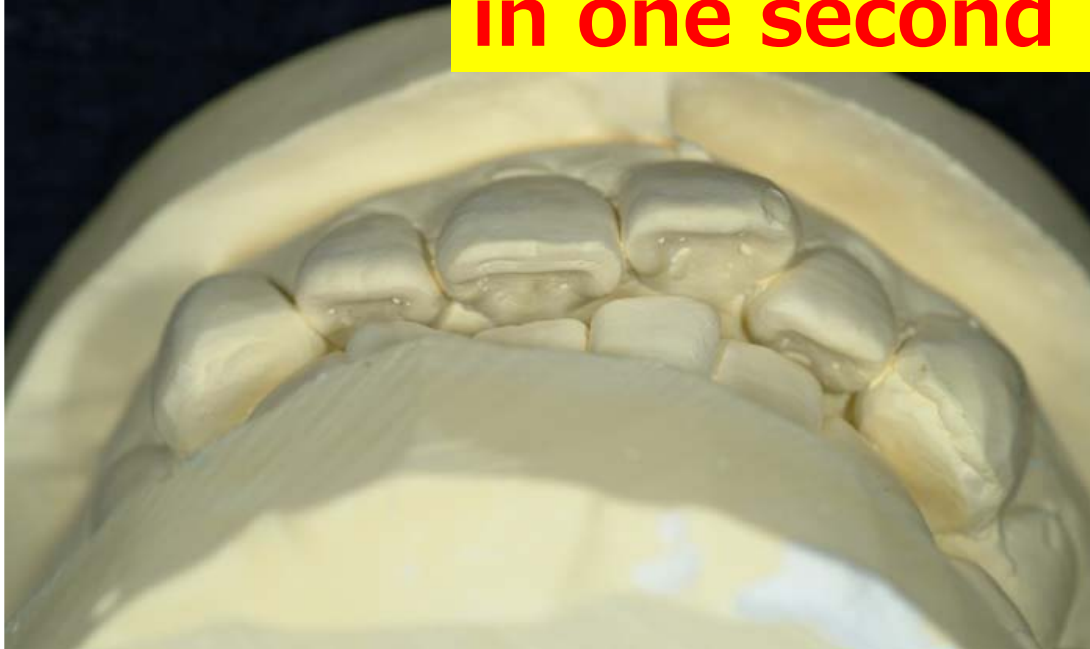Sideline aligned.

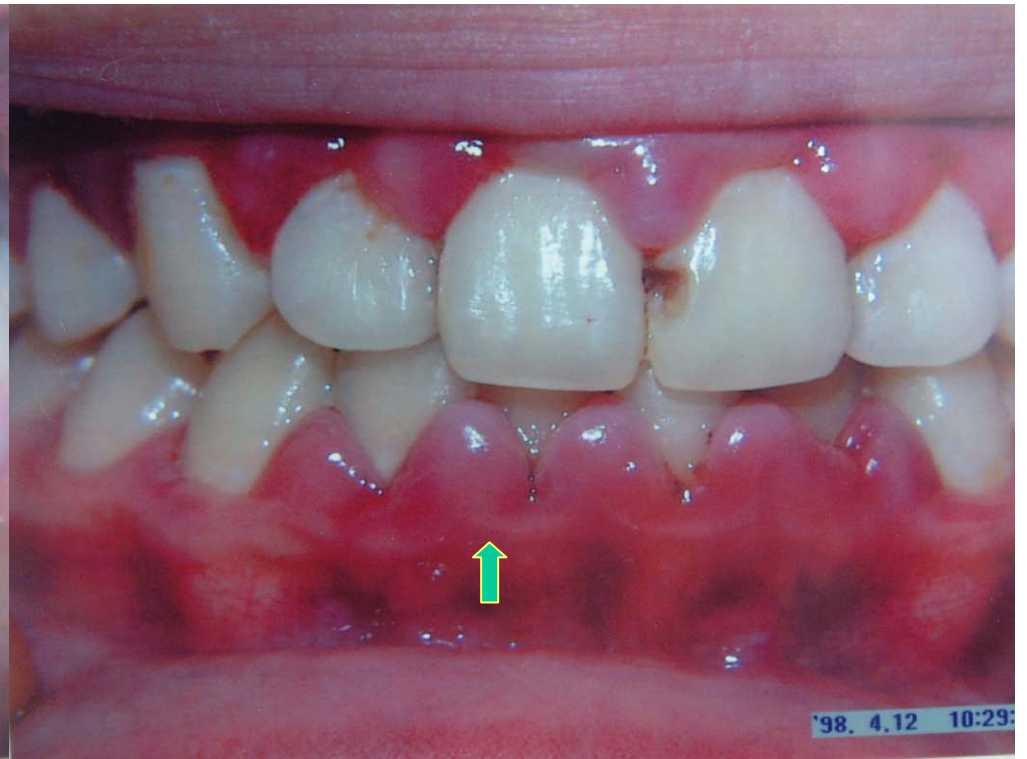
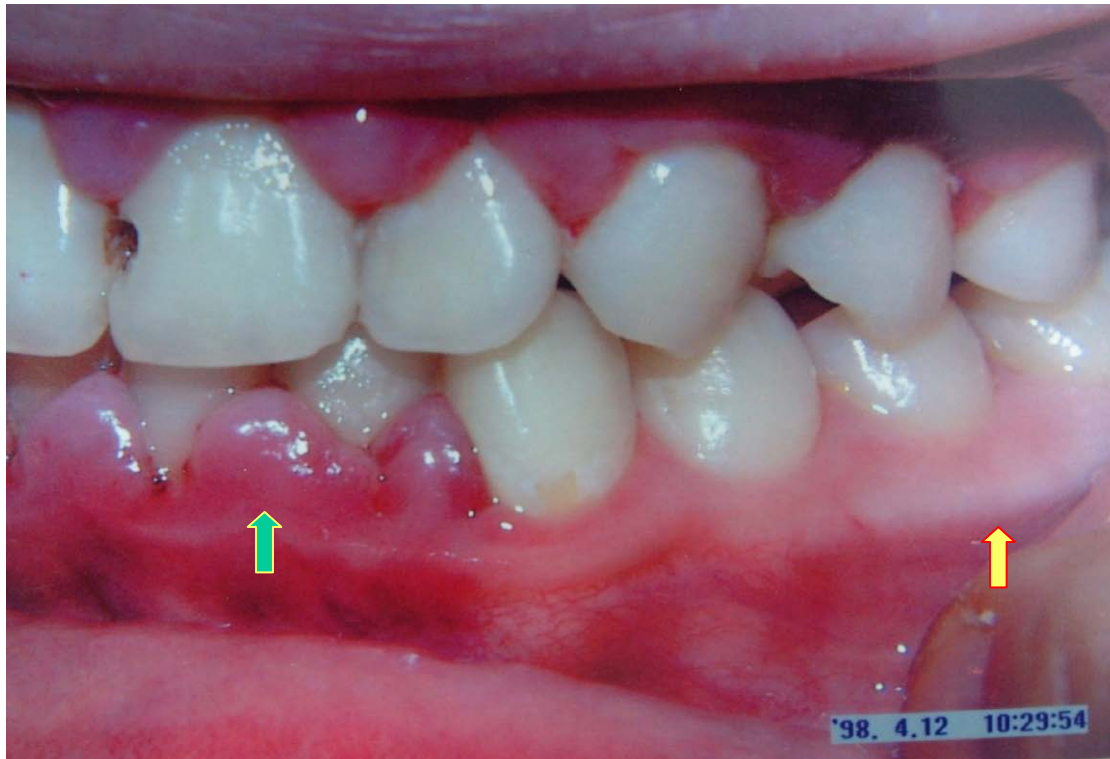


Sideline out of alignment



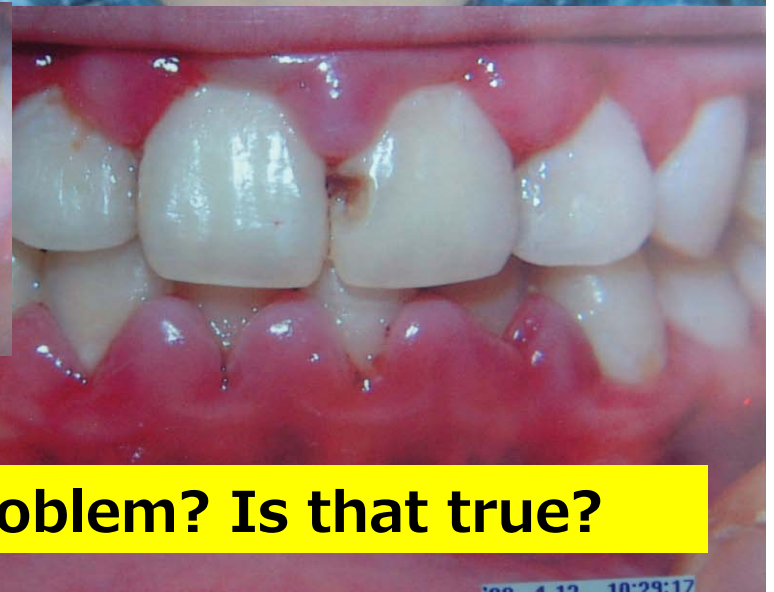
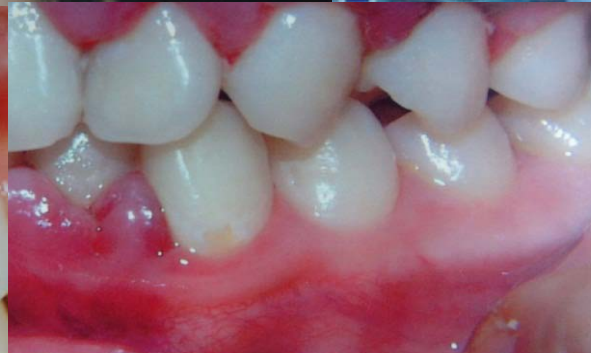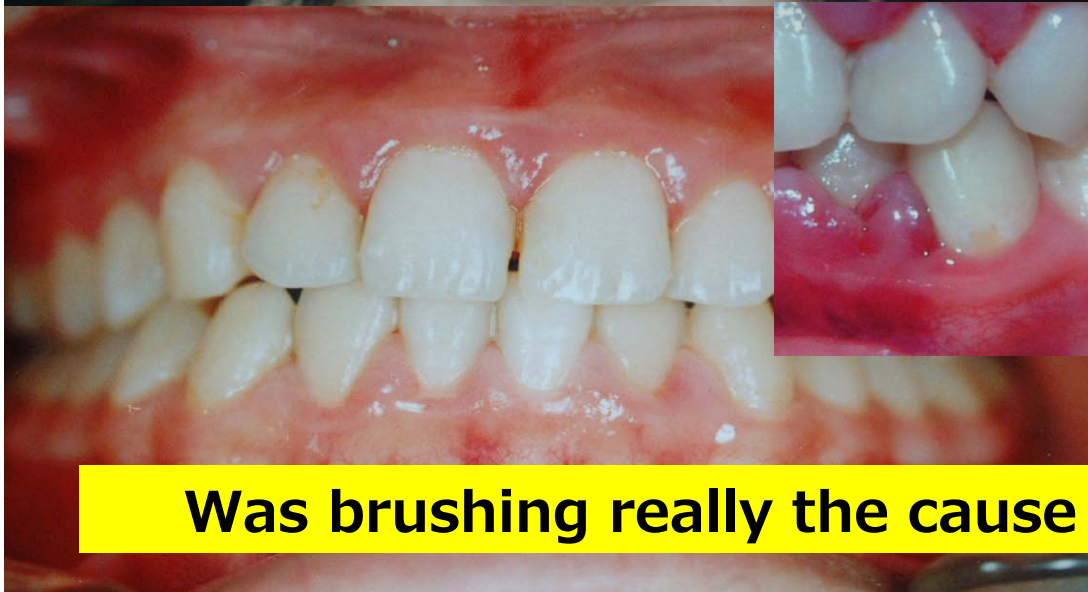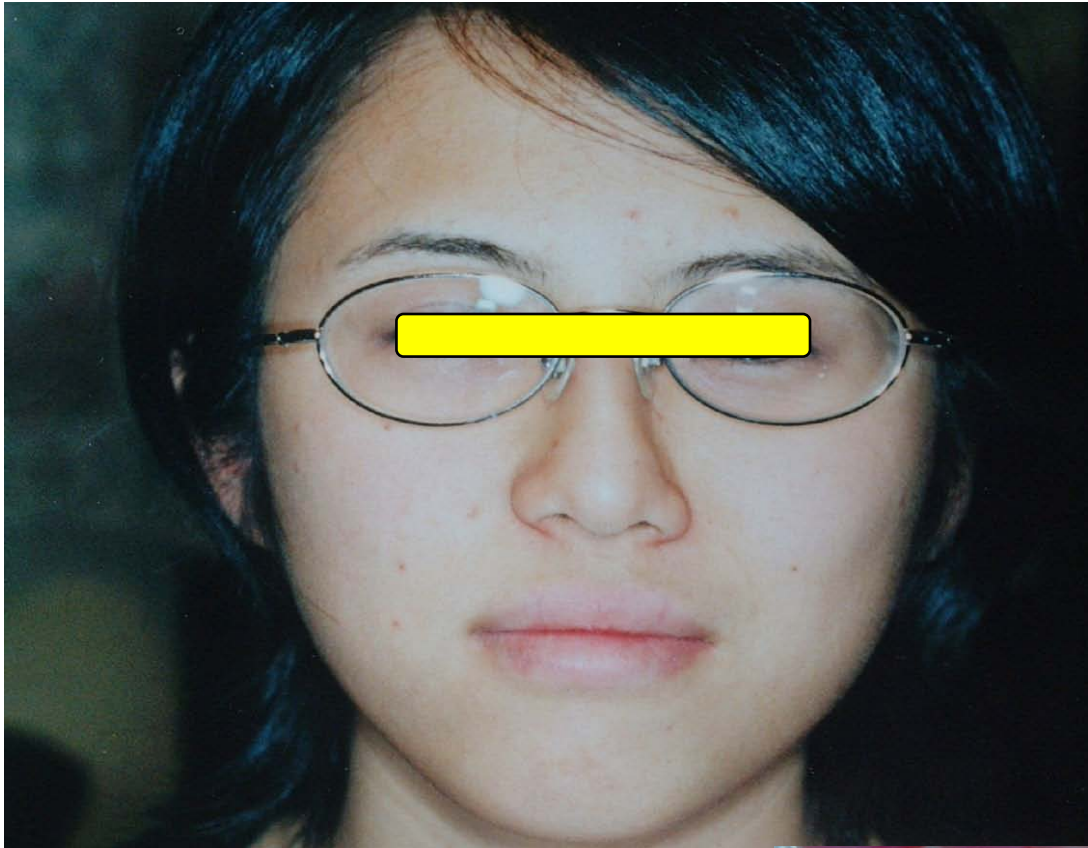
Clicking sound disappears in one second



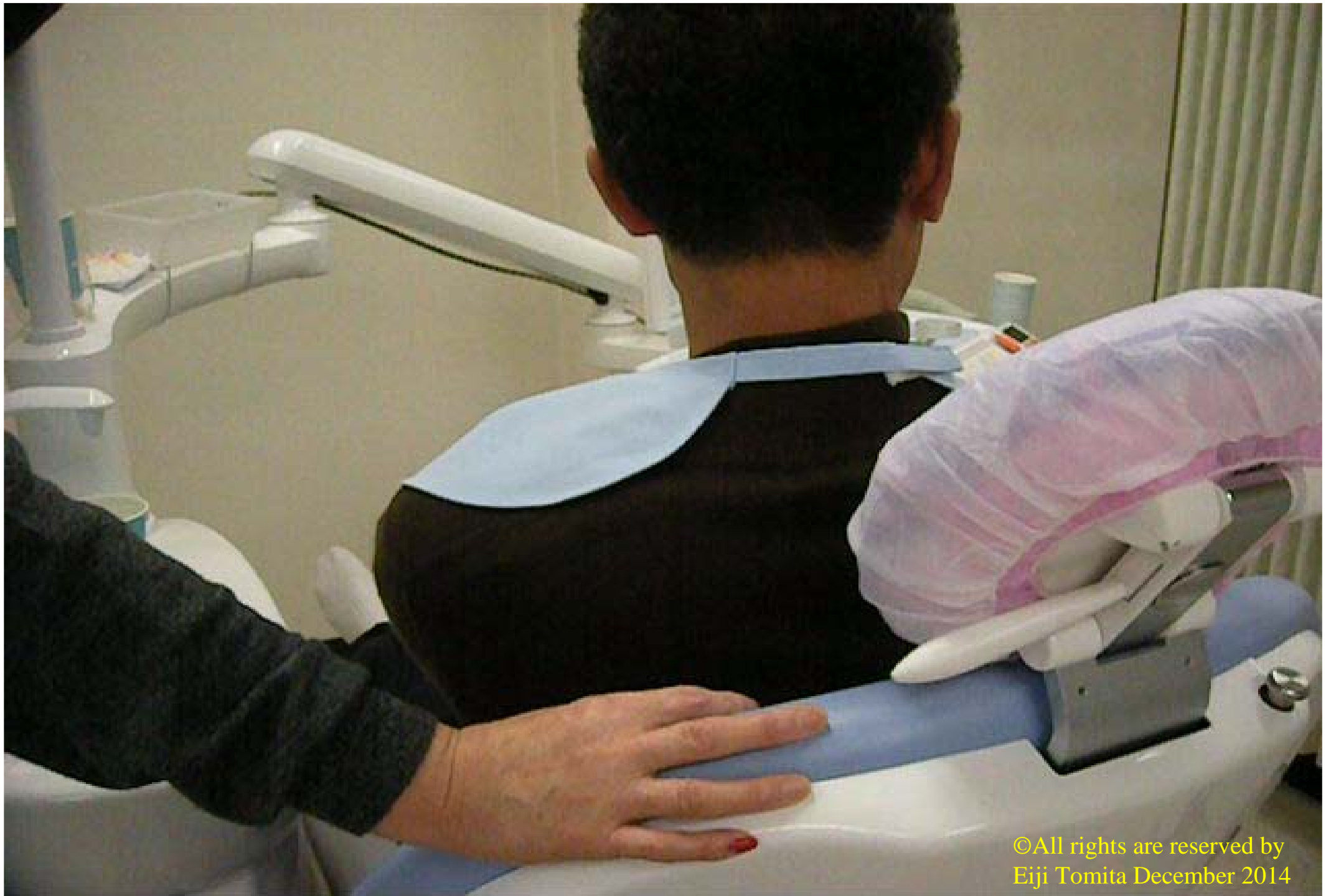

It is often said brushing teeth causes these problems.

©All rights are reserved by
Eiji Tomita December 2014

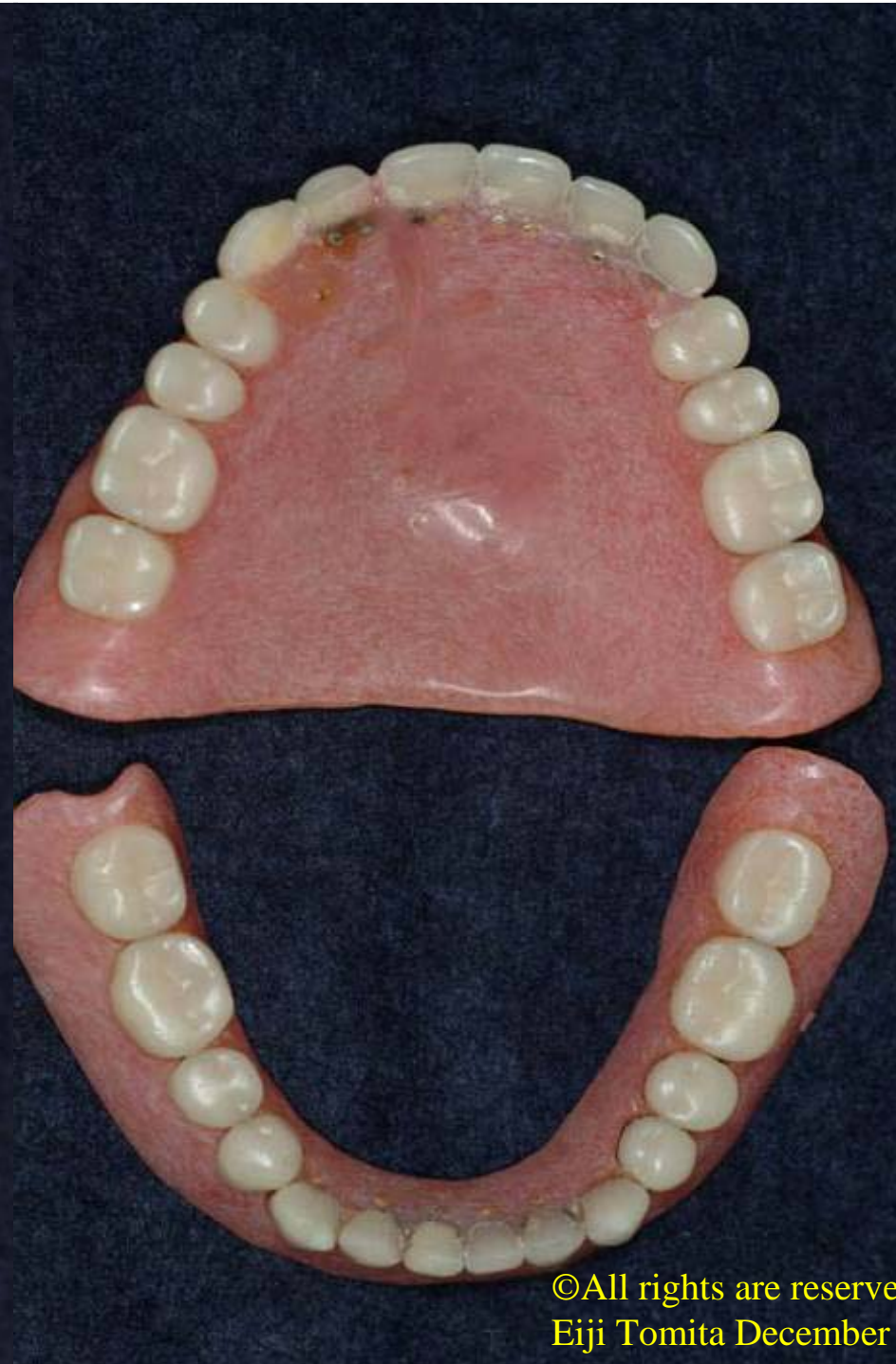
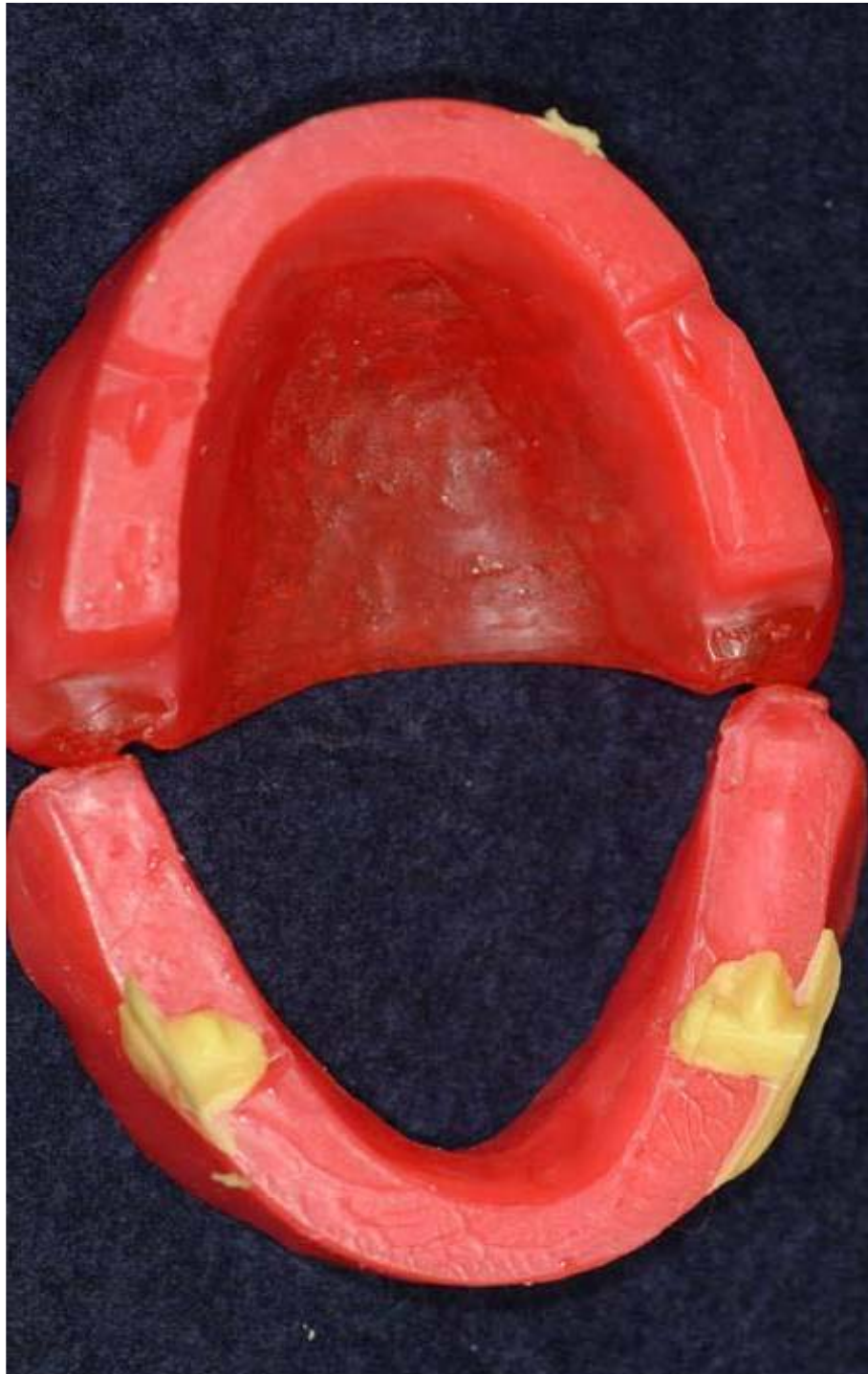
Was brushing really the cause of the problem? Is that true?

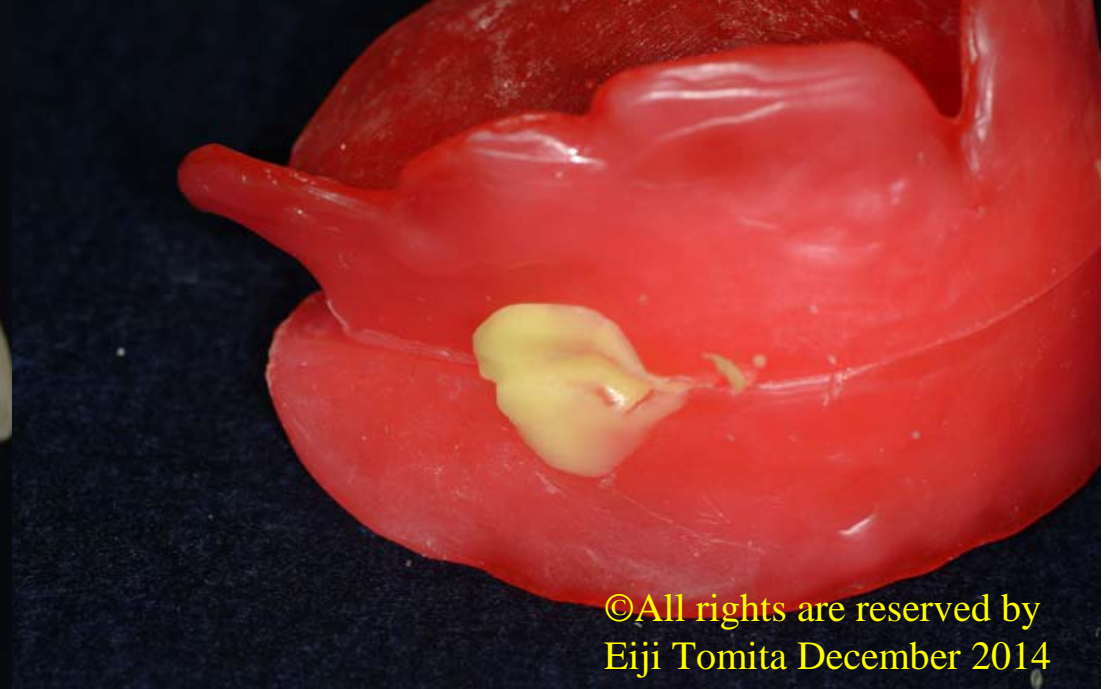
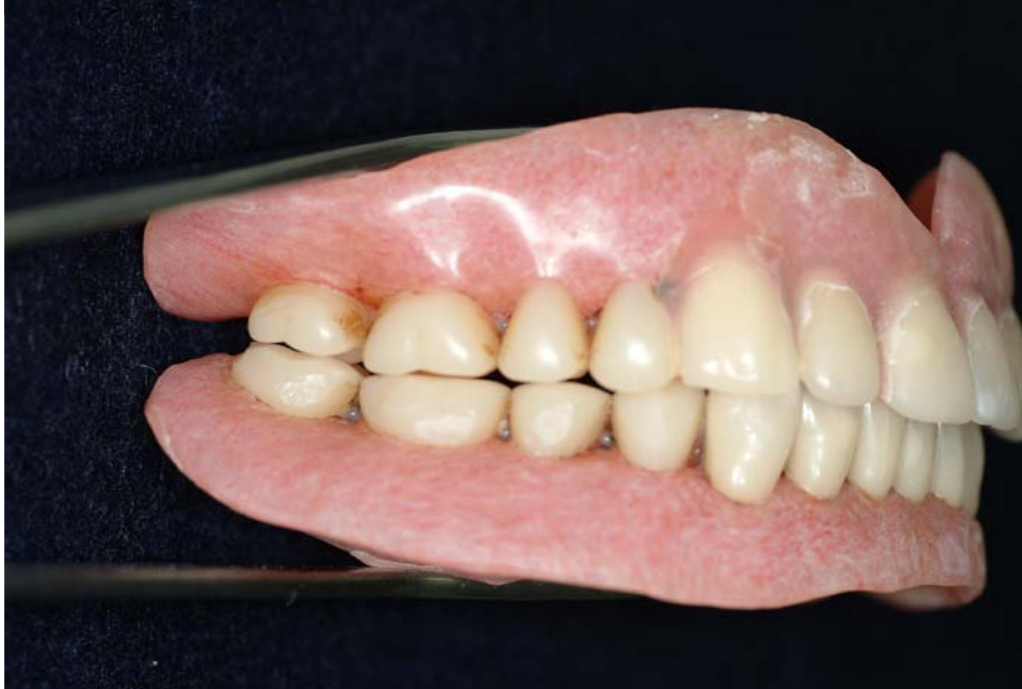
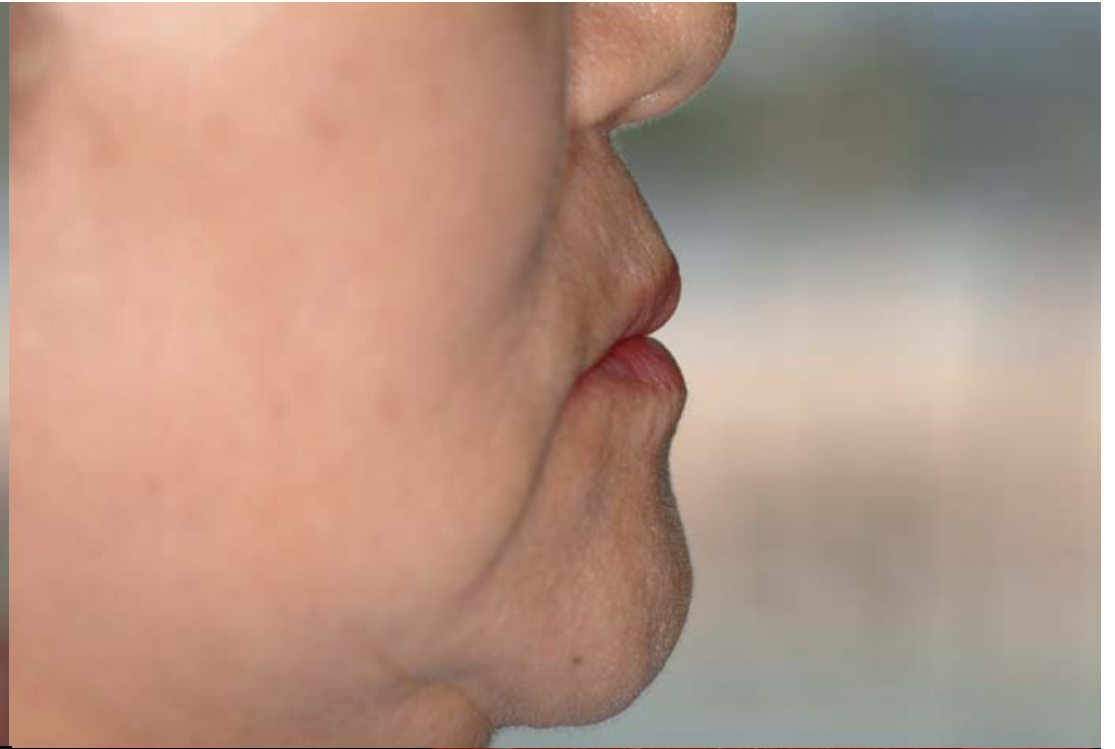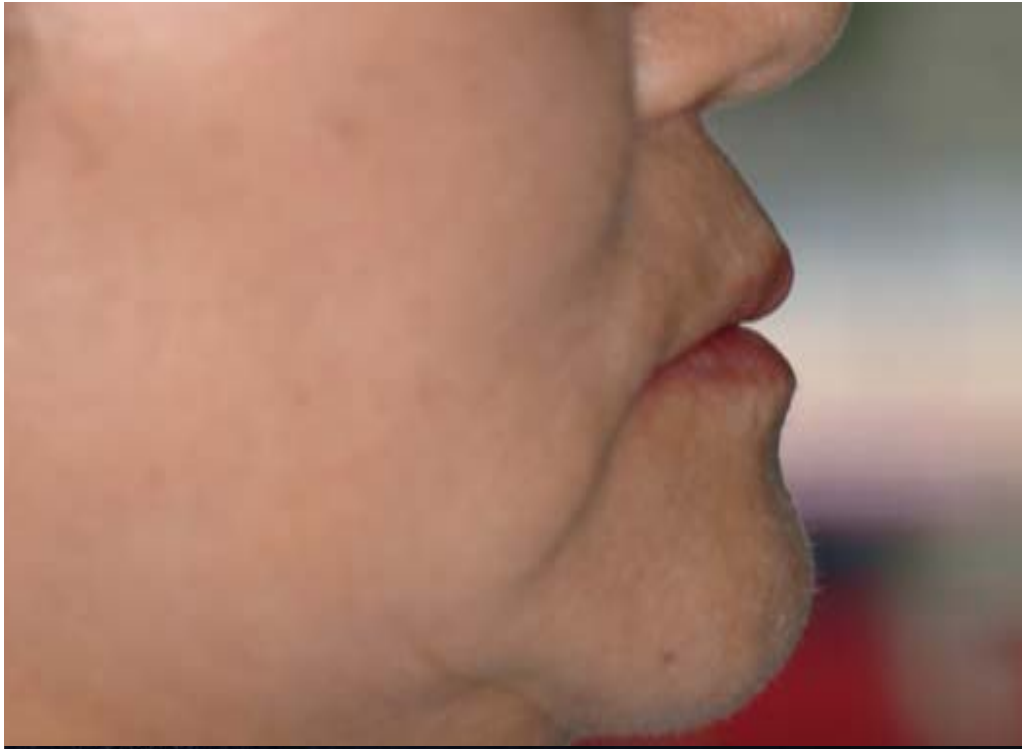©All rights are reserved by
Eiji Tomita December 2014

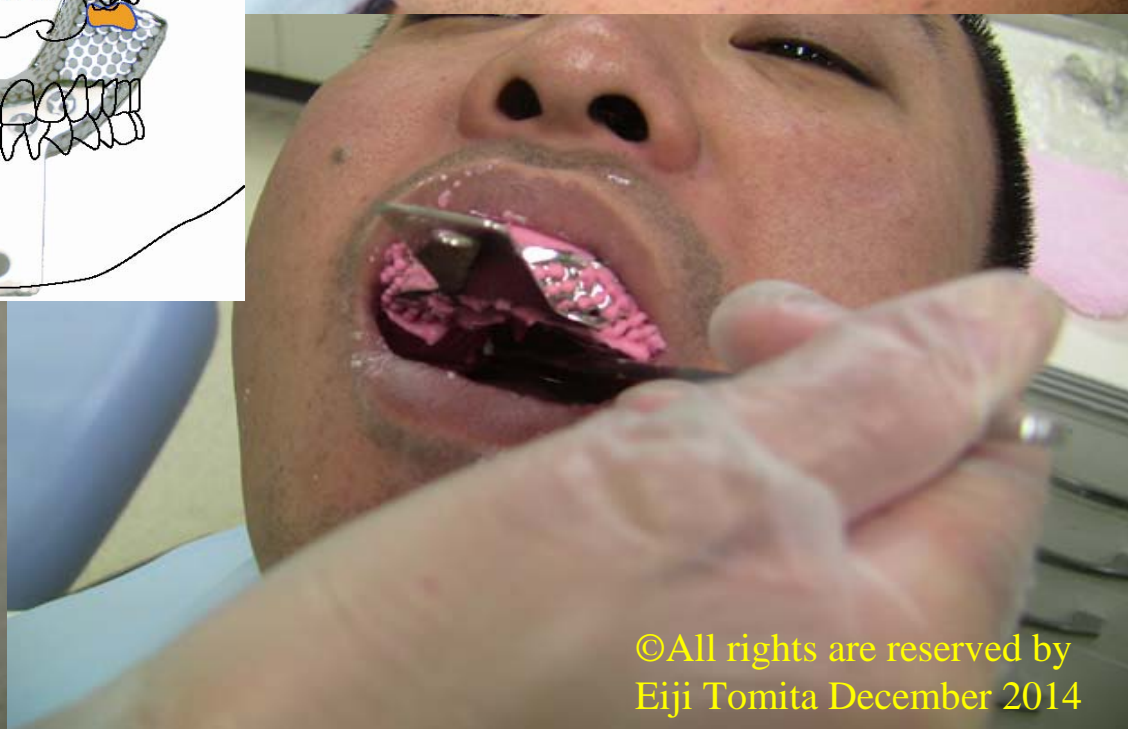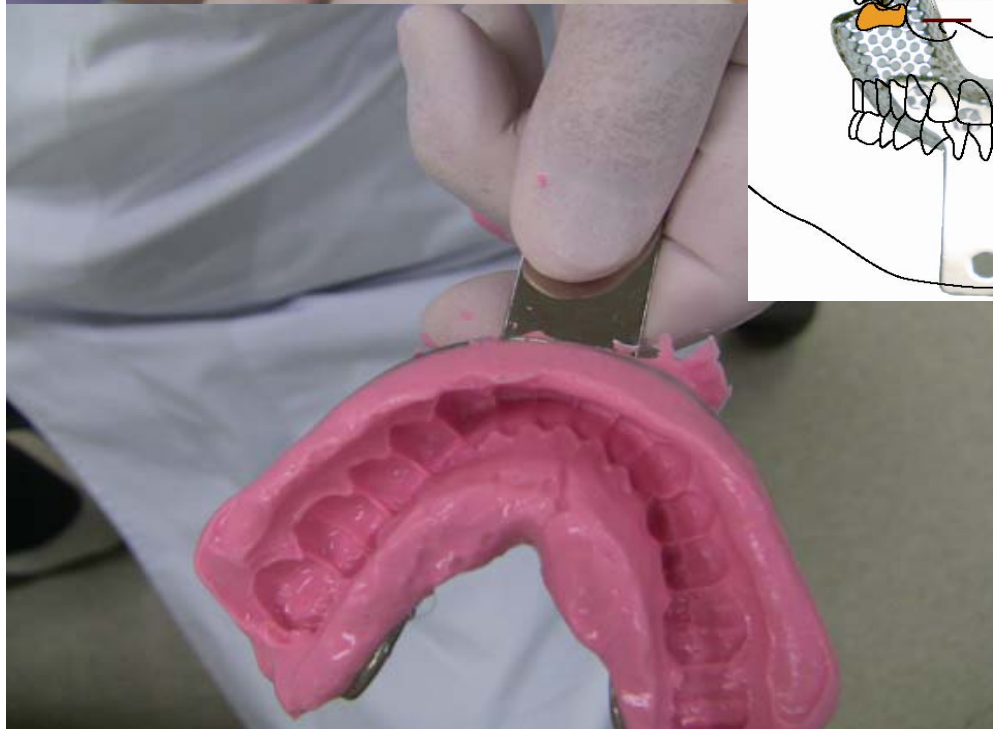
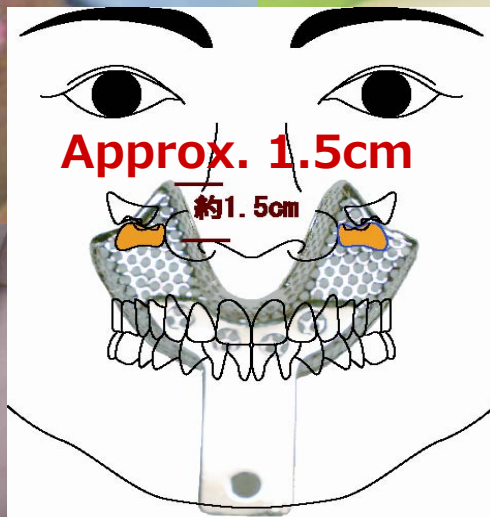
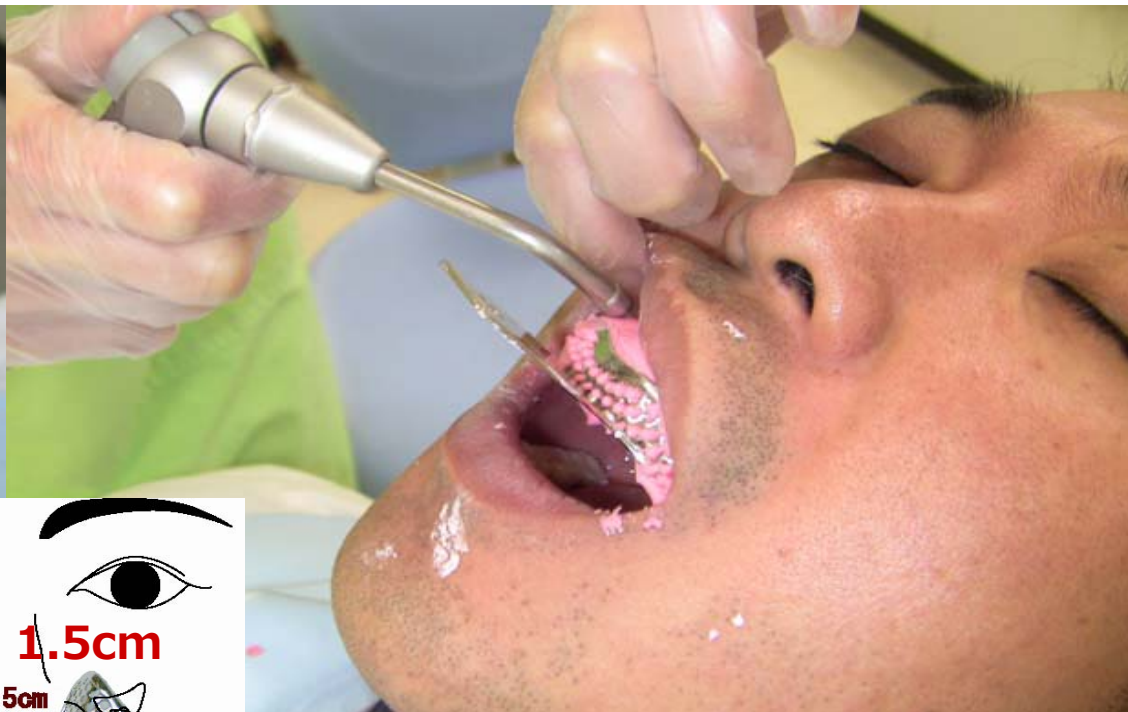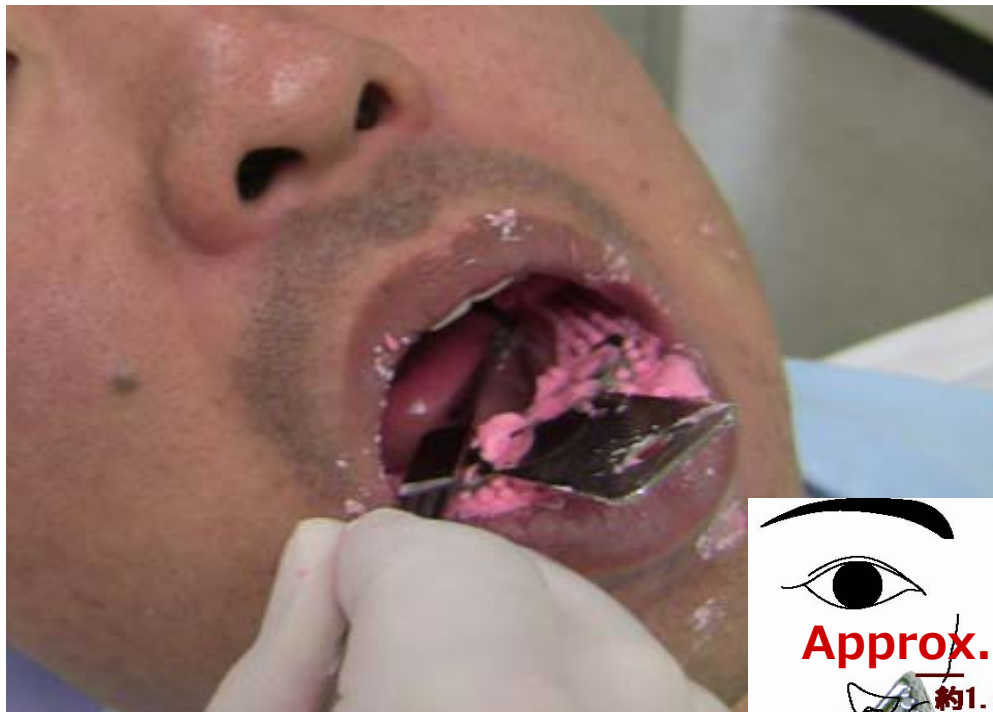**Deciding and measuring the correct
bite···the way to keep it unchanged.
How to take an dental impression
accurately.
Can be changed and produced
immediately.
Able to bite with front teeth when
wearing full denture.
Opening a big mouth won't let
the denture become loose or fall.**

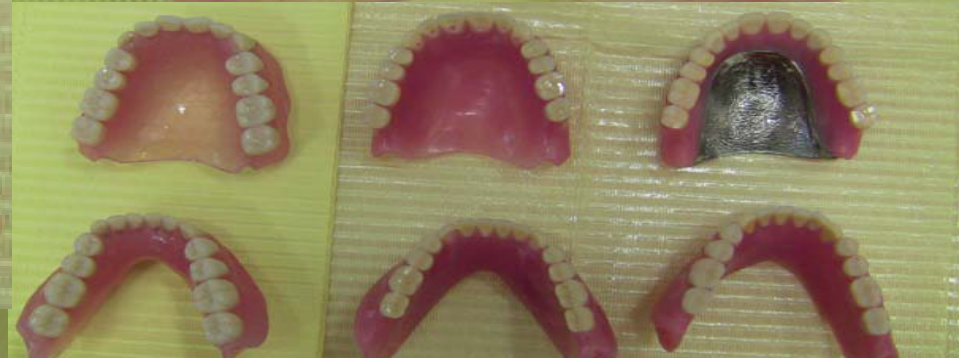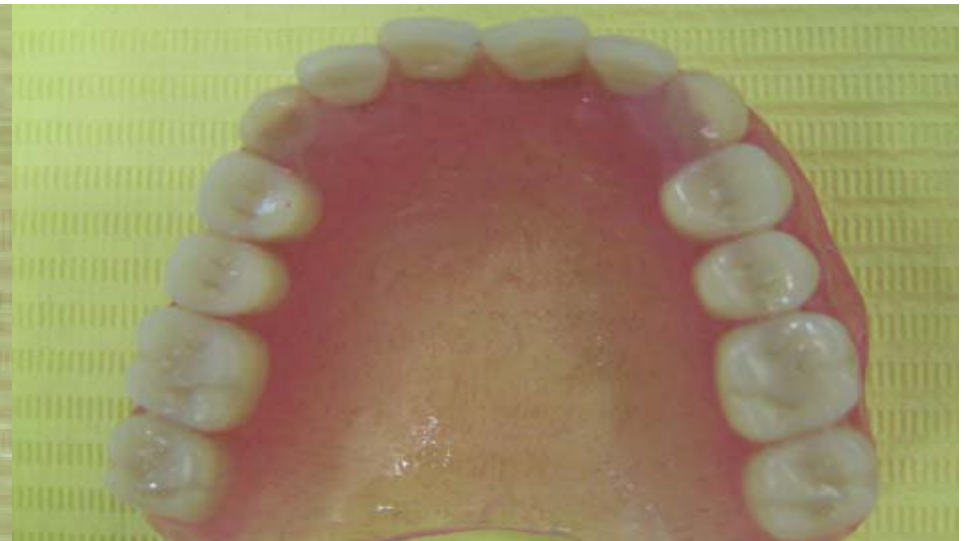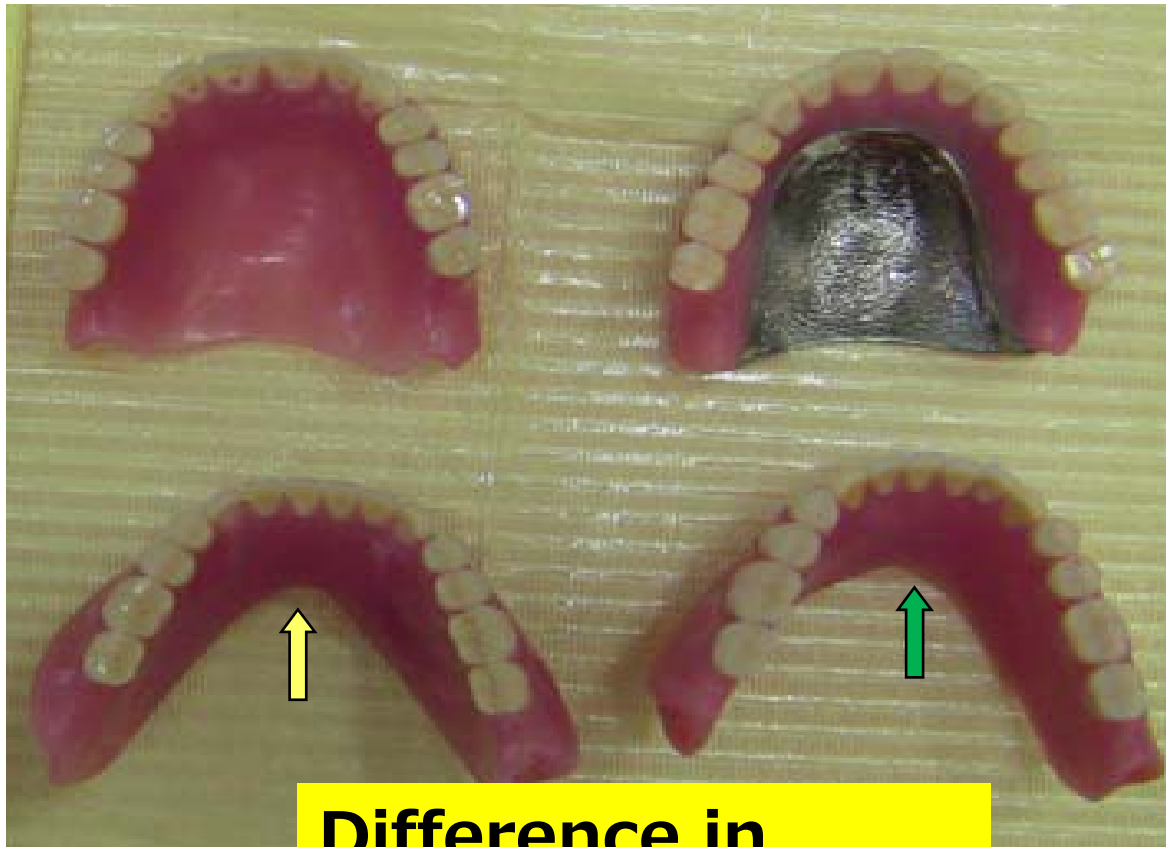


©All rights are reserved by
Eiji Tomita December 2014

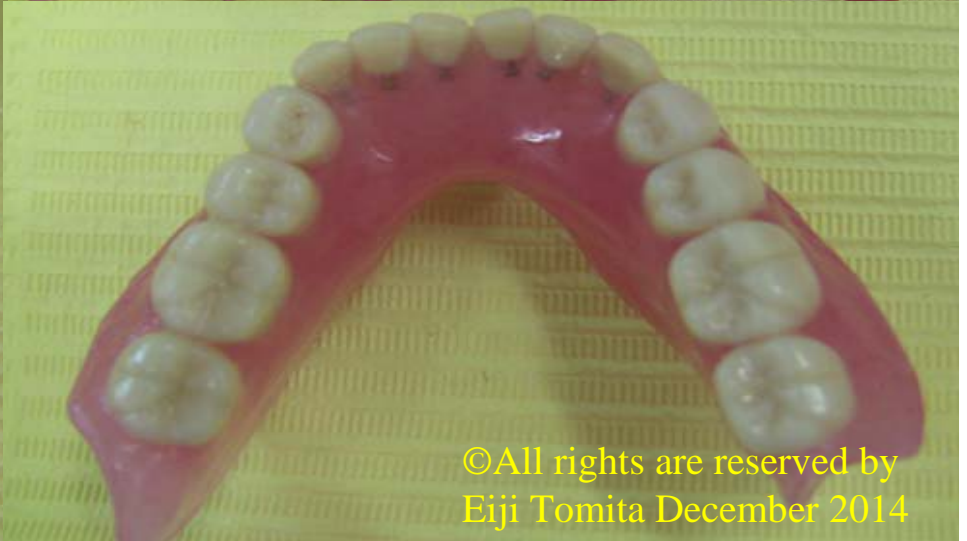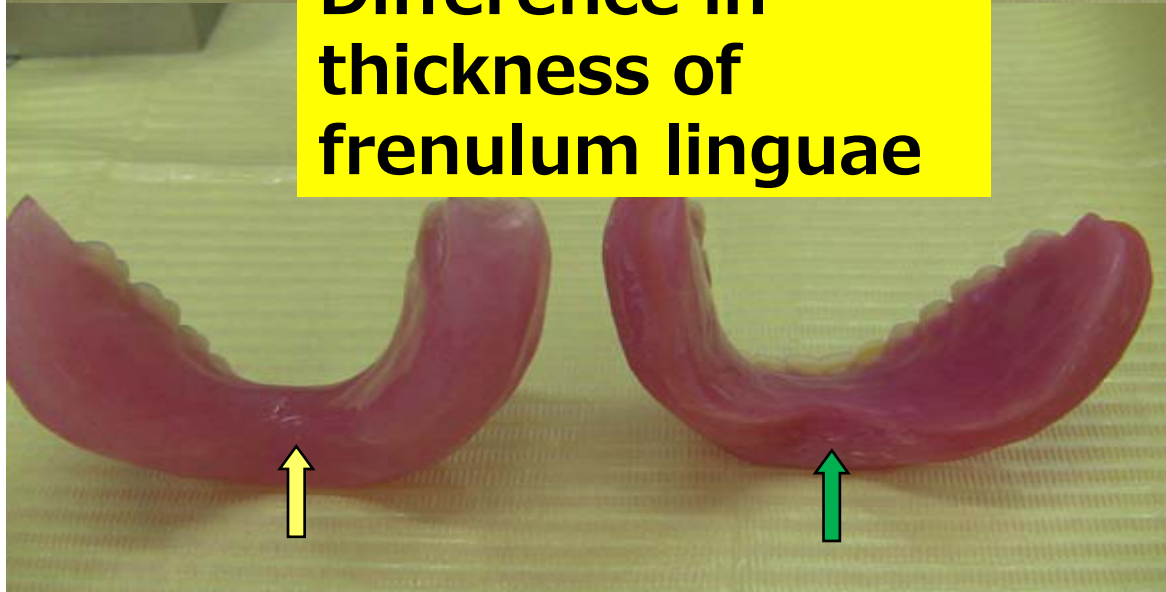


©All rights are reserved by
Eiji Tomita December 2014

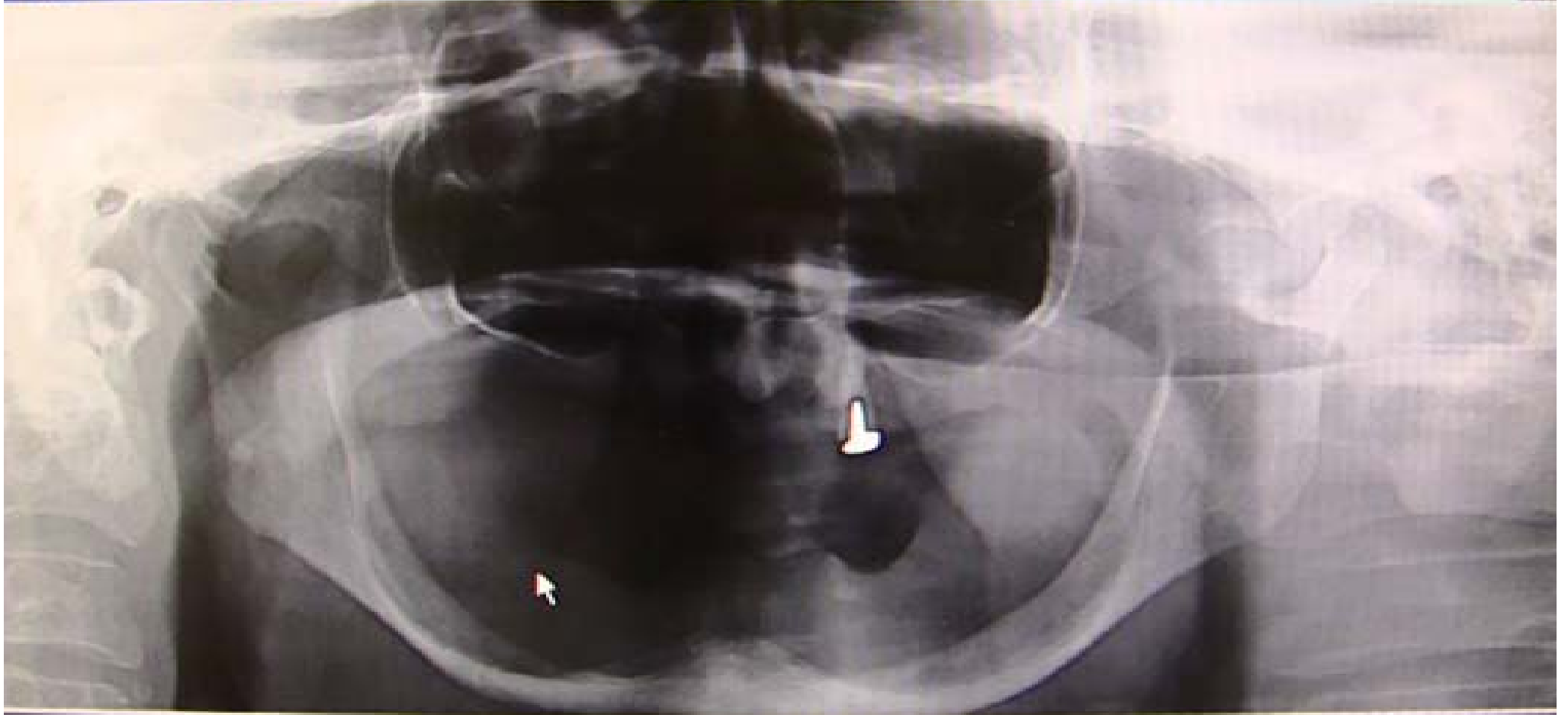



Difference in thickness of frenulum linguae

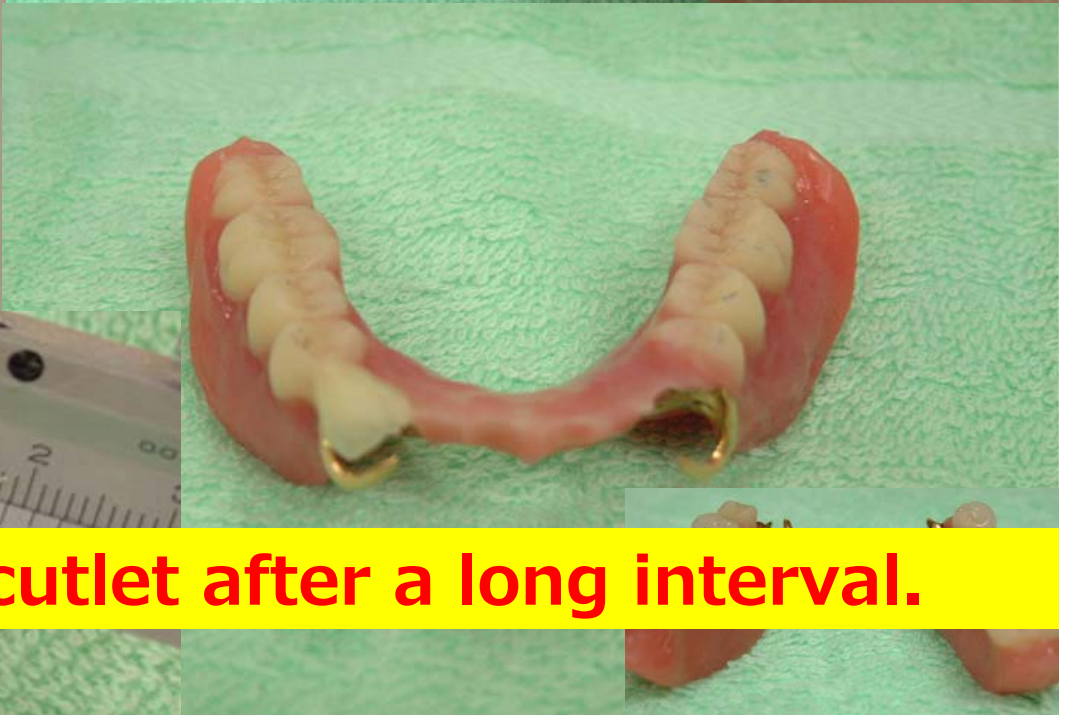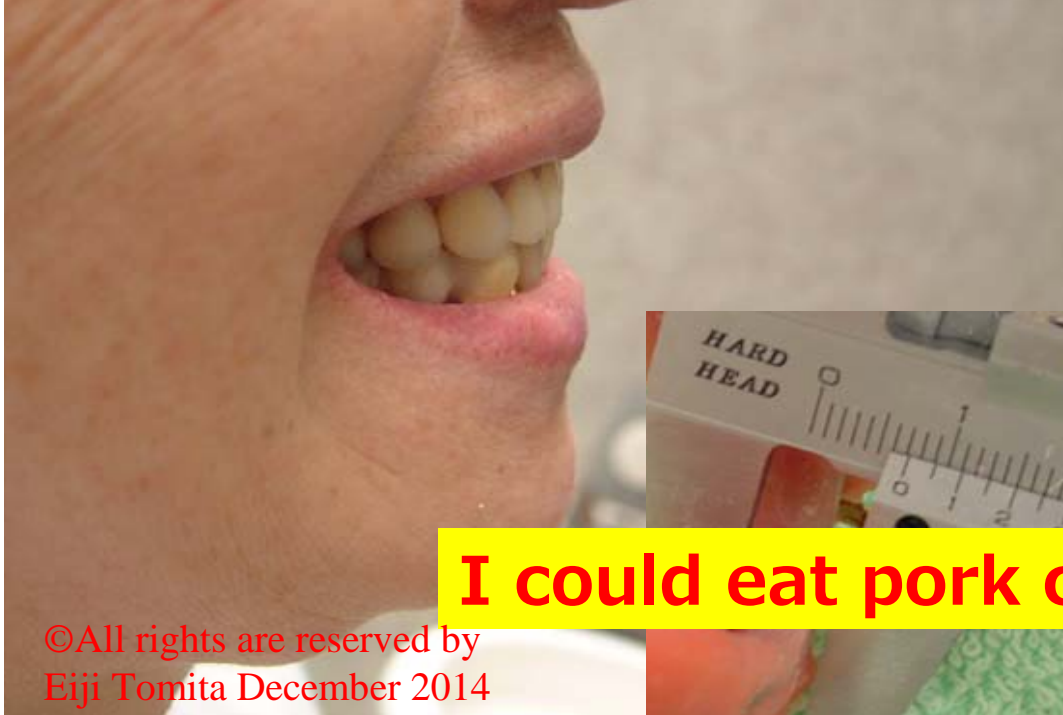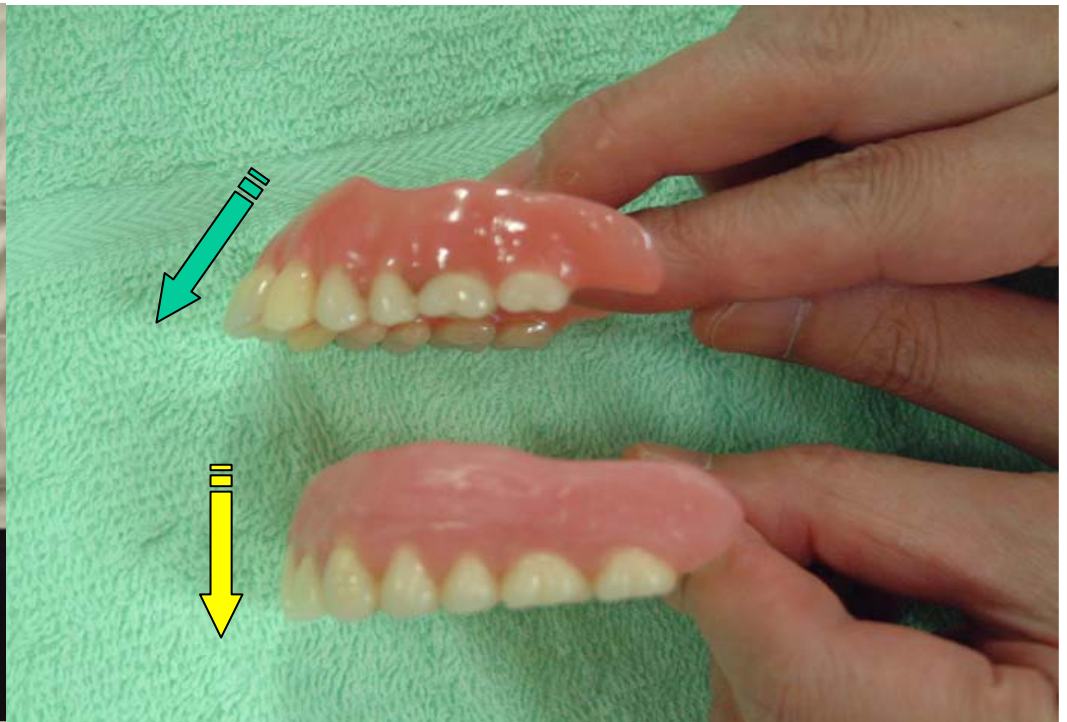


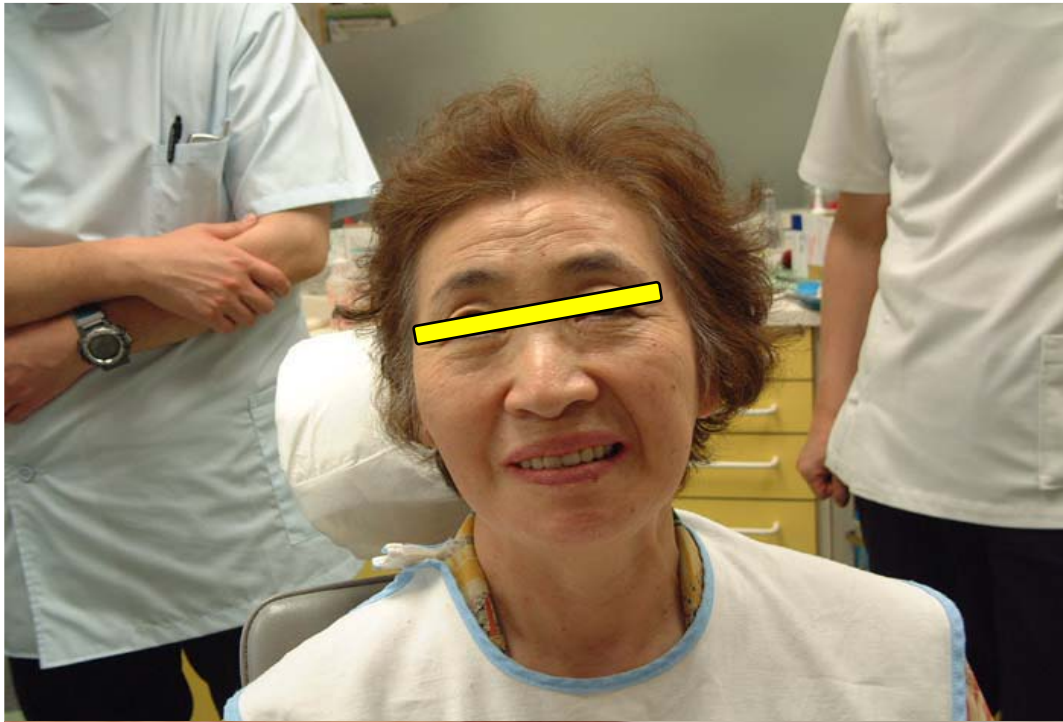02月26日 P80 79KV 6.4mA 14s

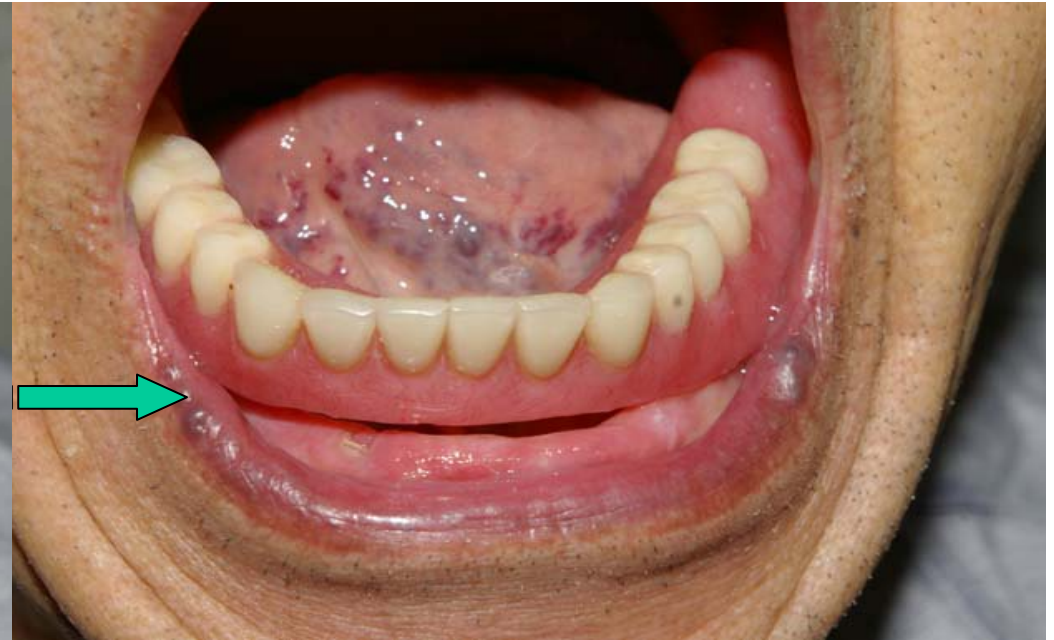
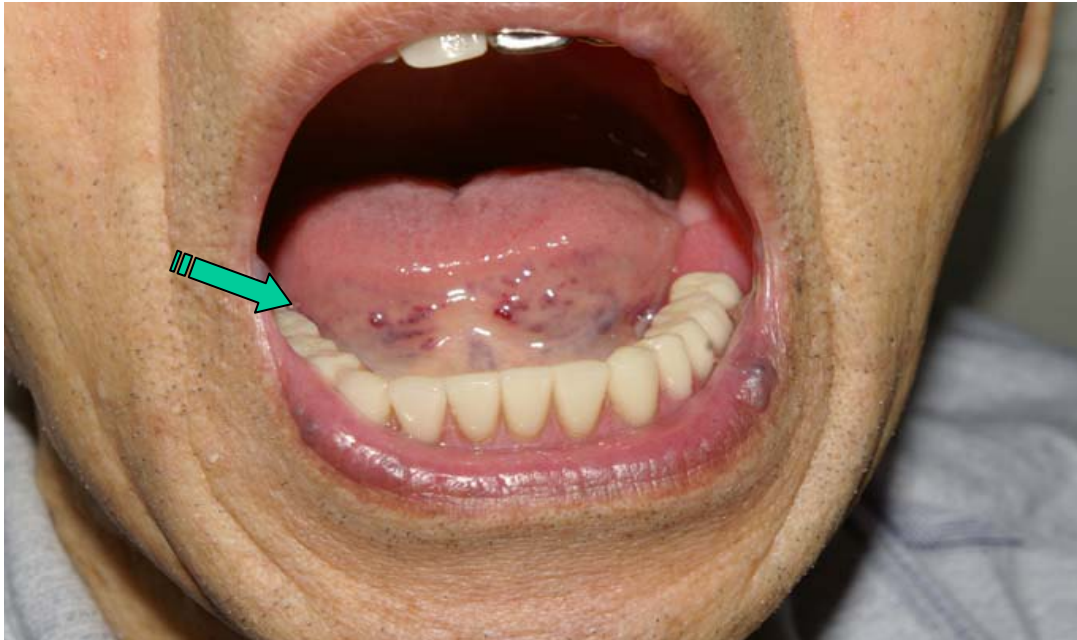
This is the case of no residual ridge, it's considered to be a difficult but actually an easiest case for the complete denture.

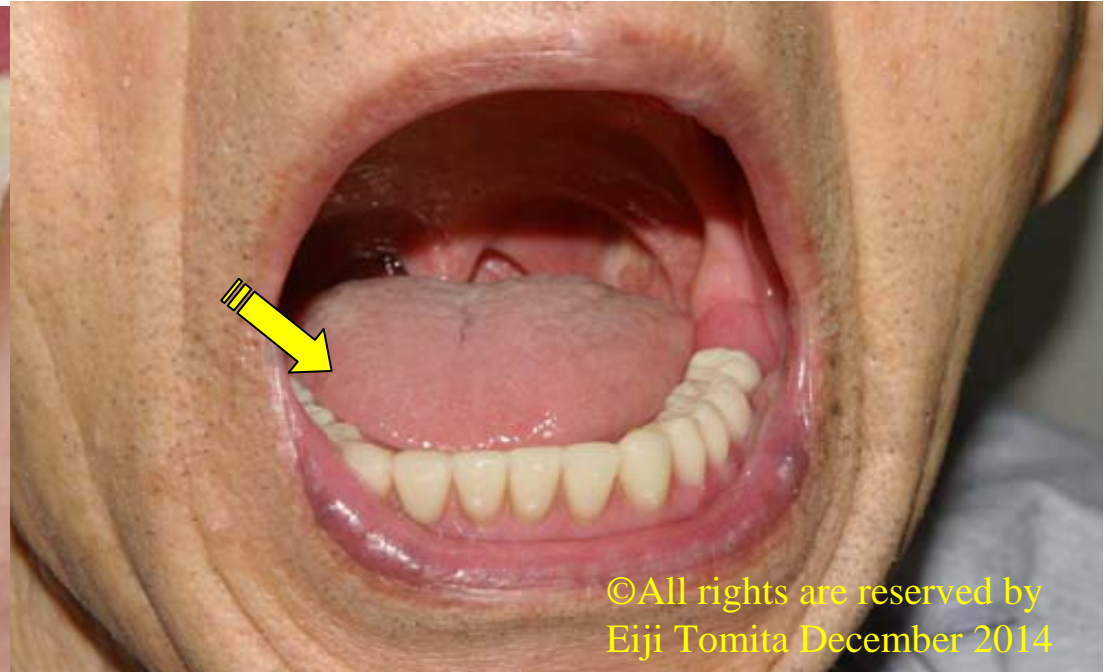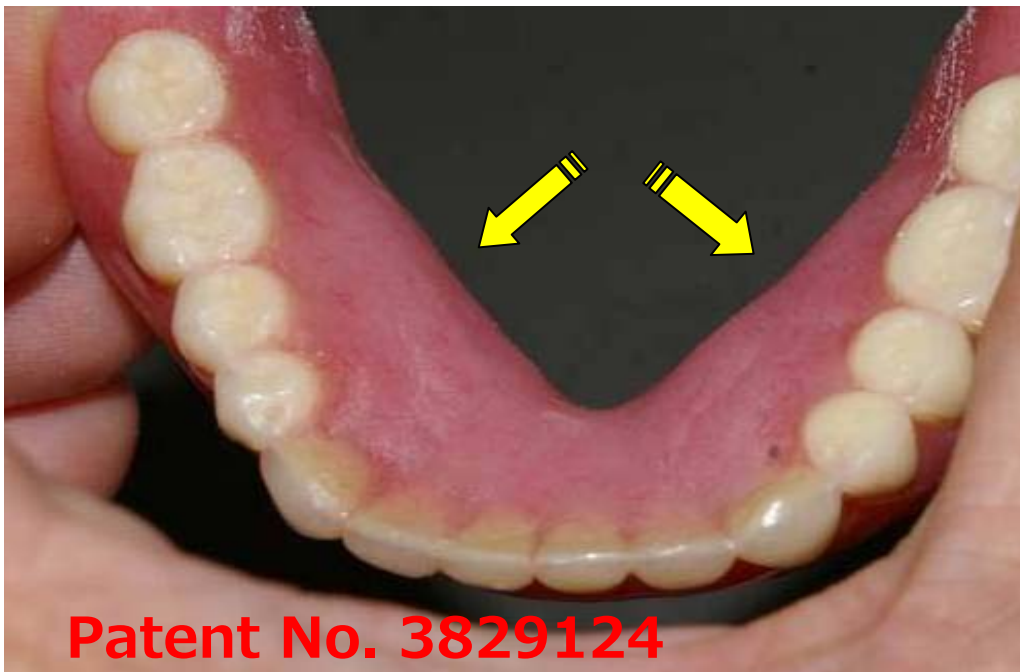
©All rights are reserved by
Eiji Tomita December 2014



I could eat pork cutlet after a long interval.

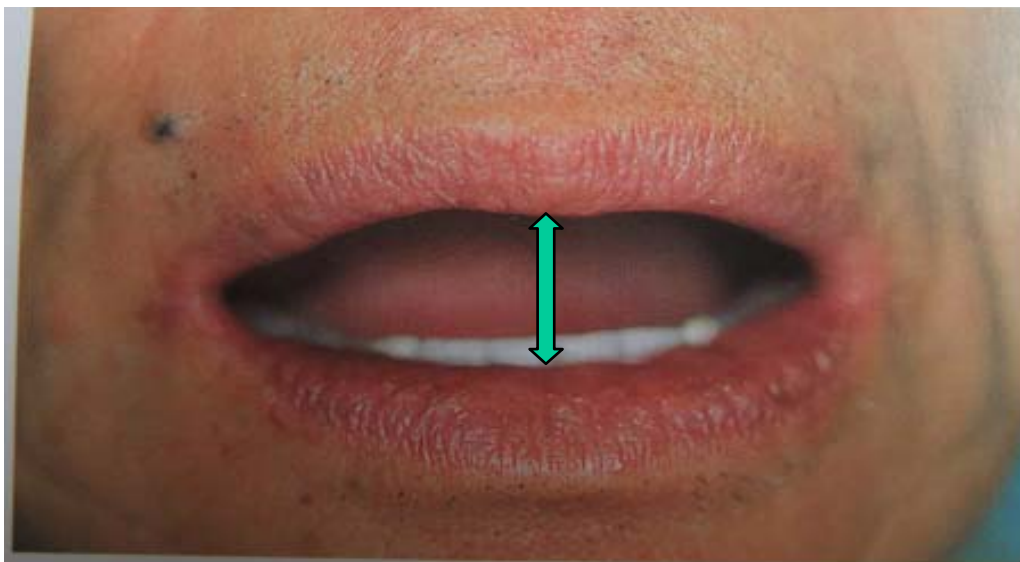


Having entire base adjusted brings the tongue forward



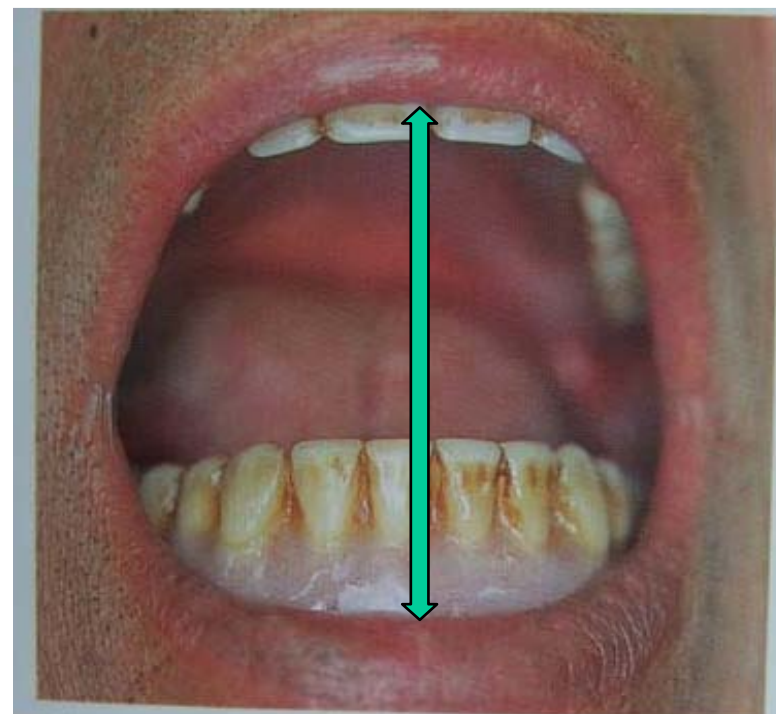
Patent No. 3829124

©All rights are reserved by
Eiji Tomita December 2014

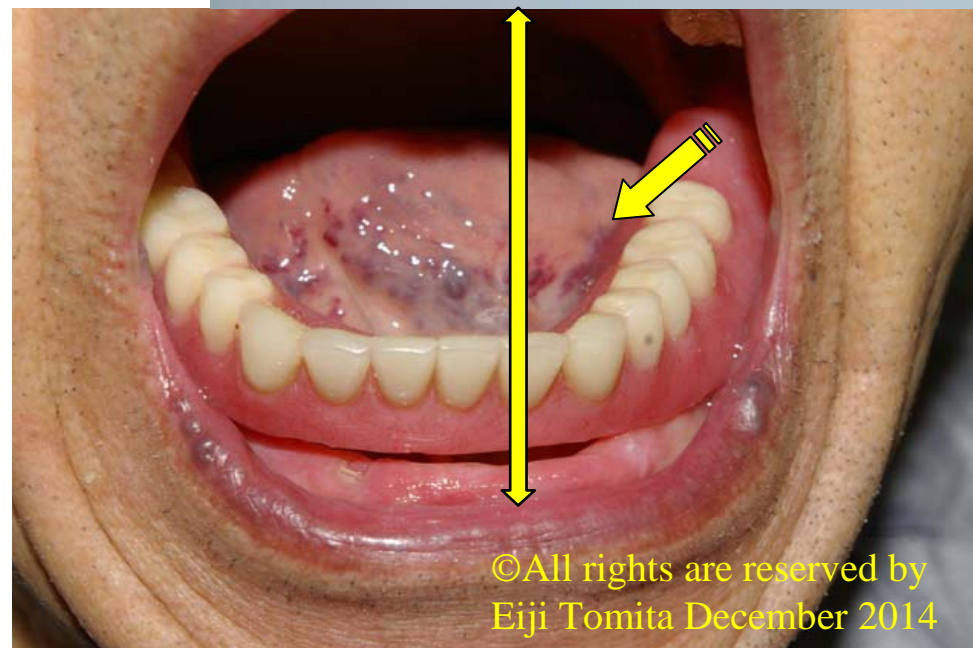
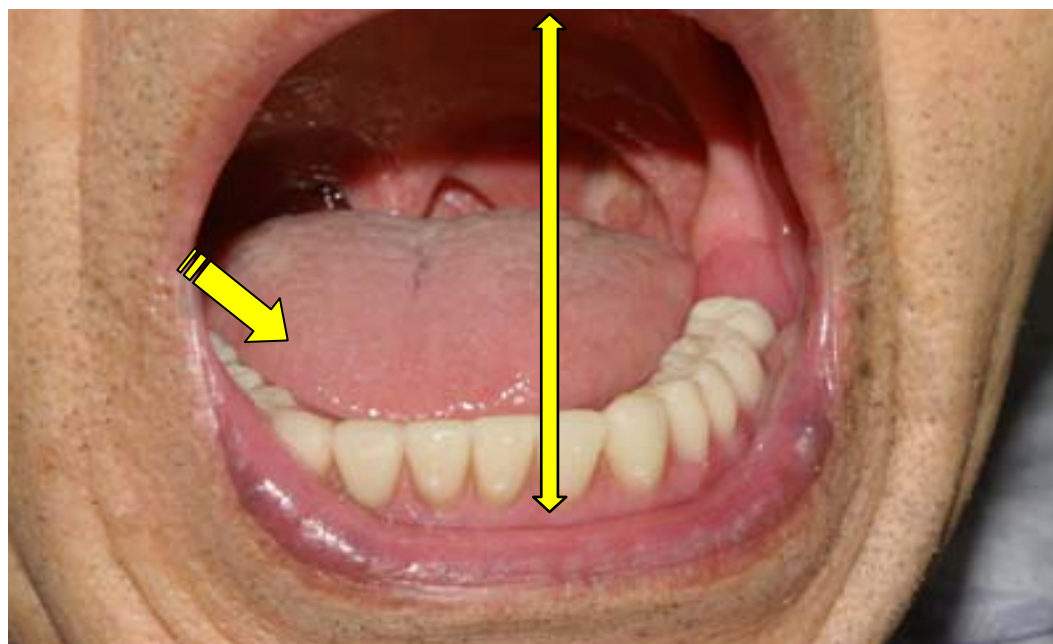


26 装着した状態で開口しても浮き上がらない

Photos from a magazine!



4 開口時、下顎義歯が浮き上がる



©All rights are reserved by
Eiji Tomita December 2014



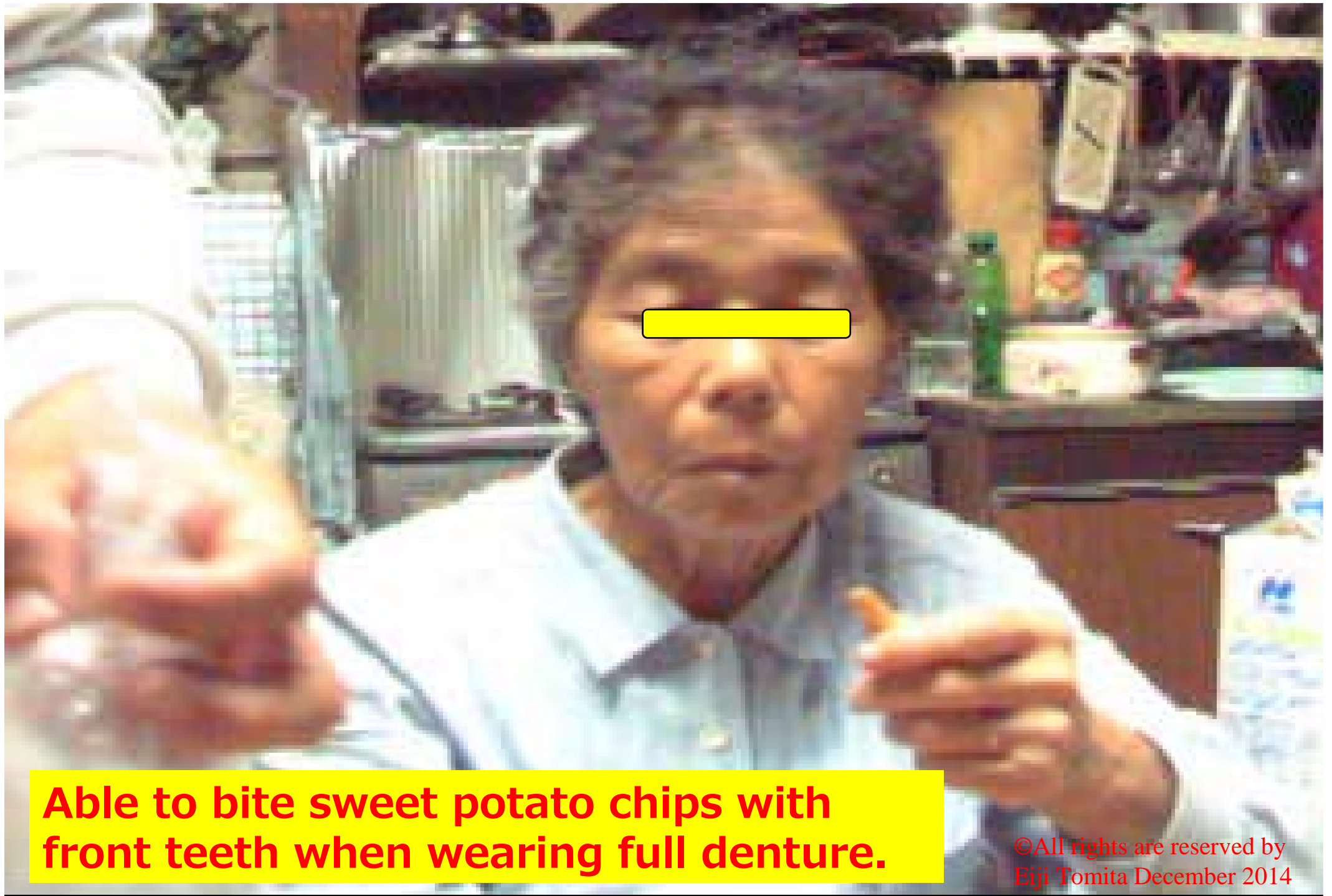Sweet potato chips

©All rights are reserved by
Eiji Tomita December 2014

A photograph showing a man in a plaid shirt in the foreground, leaning over a table and biting a piece of food. In the background, another man in a striped shirt is seated at the table, looking on. The table is covered with a green cloth and has various items on it, including a pink paper with yellow slices, a blue water bottle, and some papers. The setting appears to be a laboratory or a research facility.

Bite with front teeth

©All rights are reserved by
Eiji Tomita December 2014

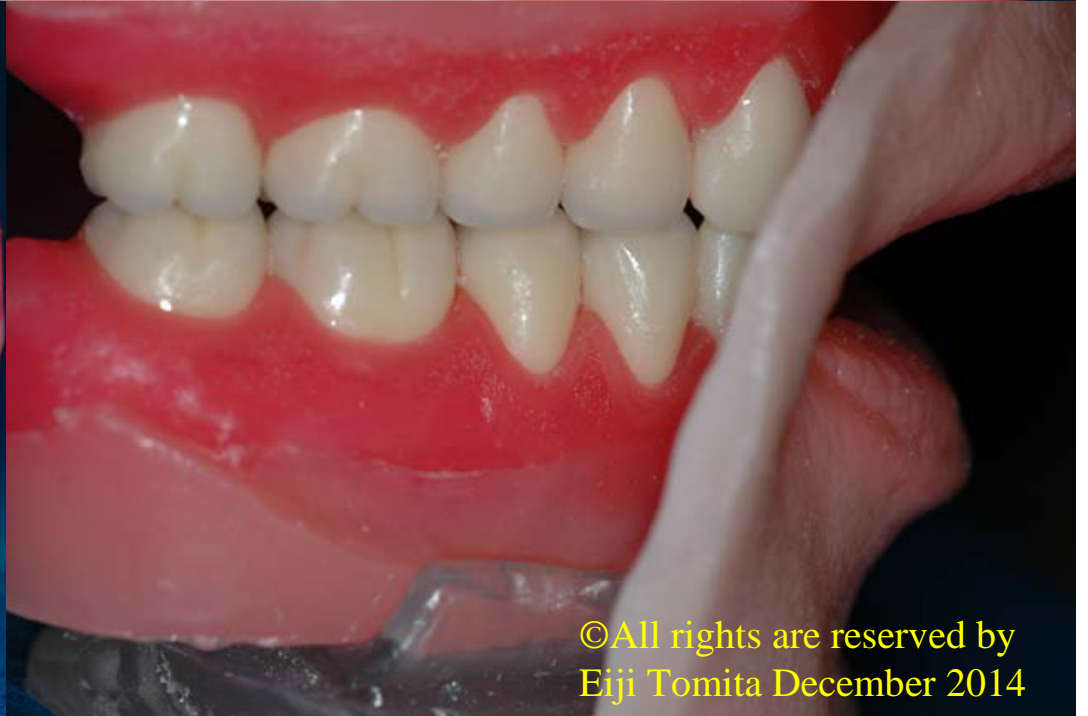
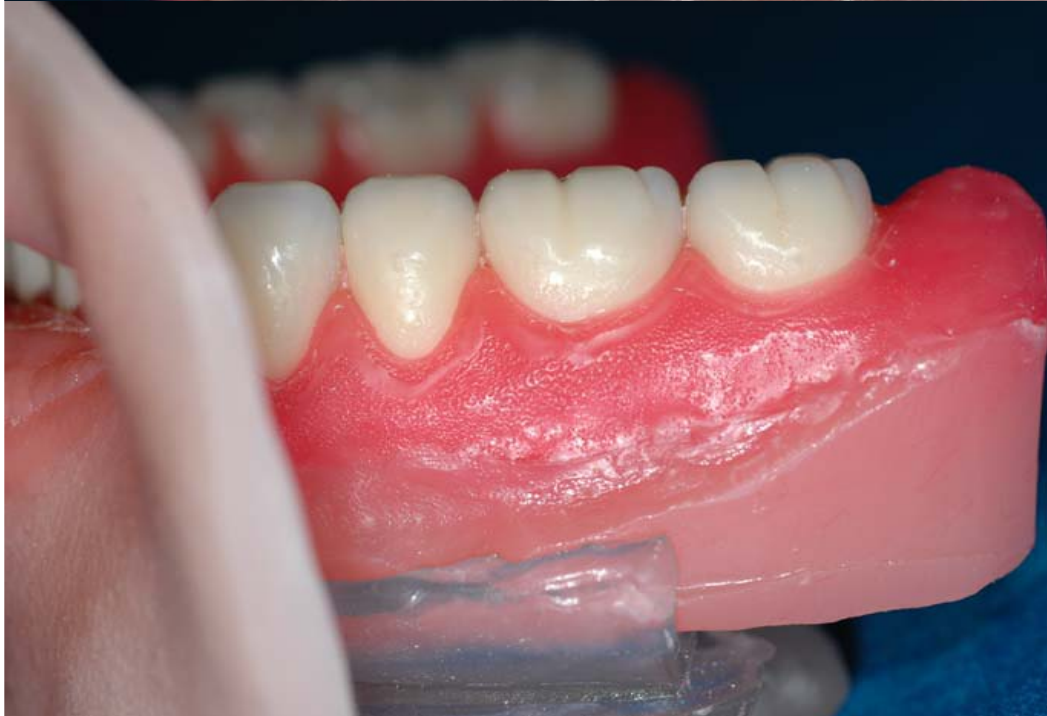
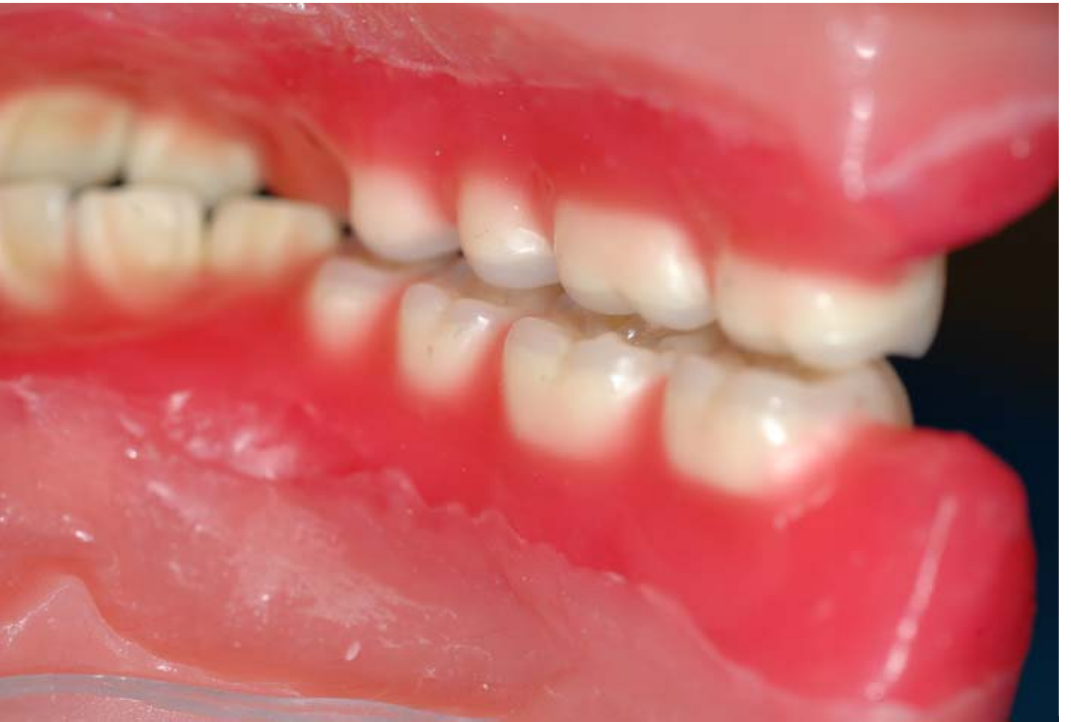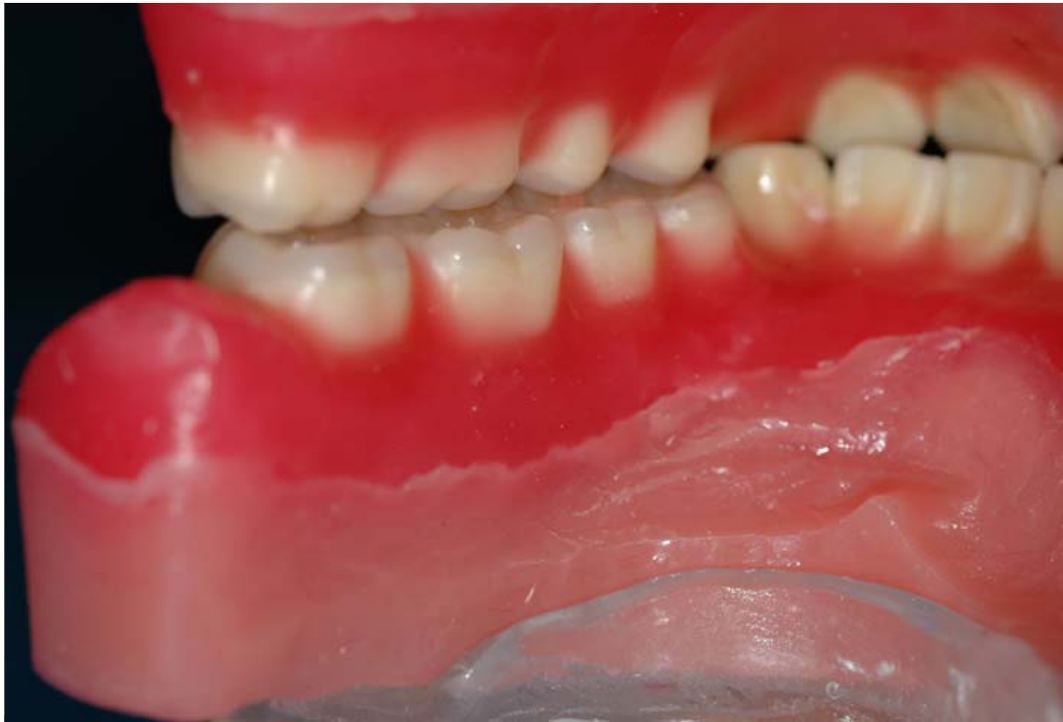Able to bite sweet potato chips with front teeth when wearing full denture.



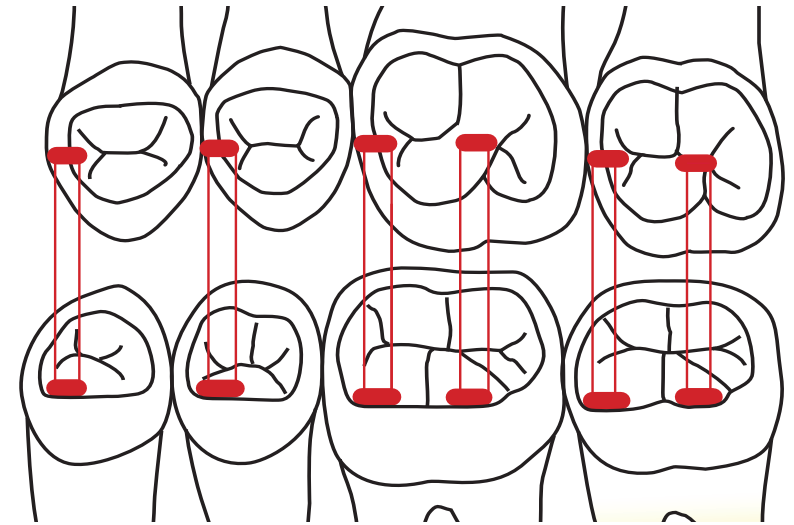
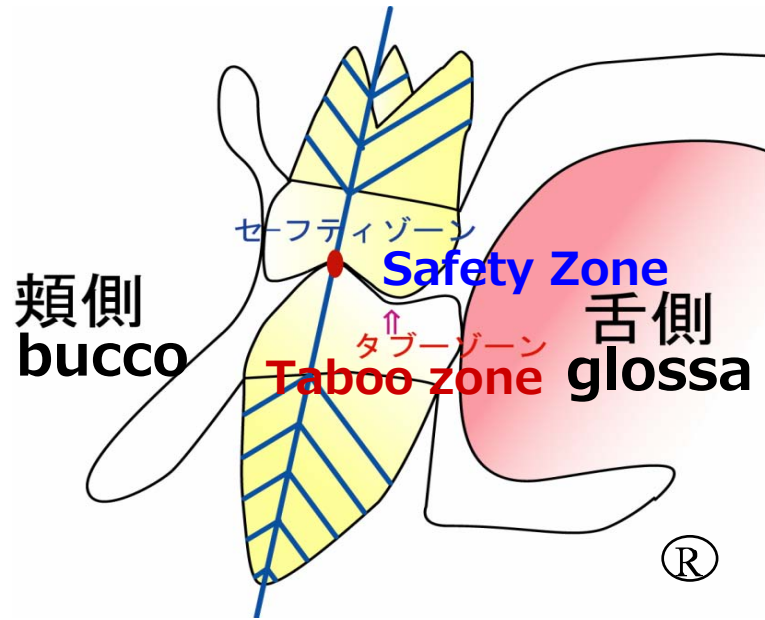
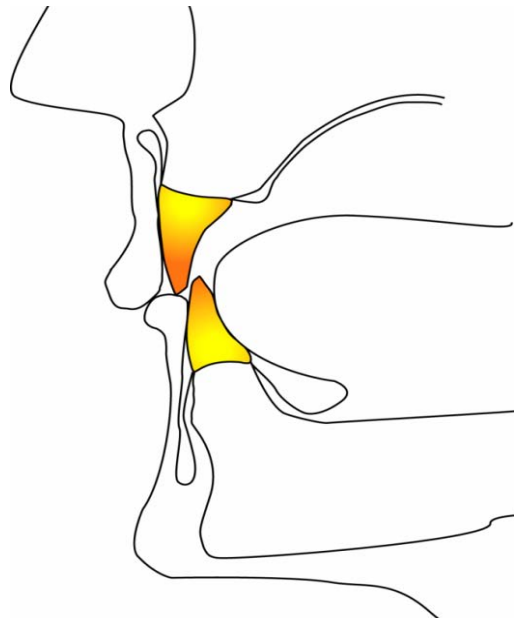
Interview with Dr. Matsubara

©All rights are reserved by
Eiji Tomita December 2014



健康咬合の定義 L・B・O

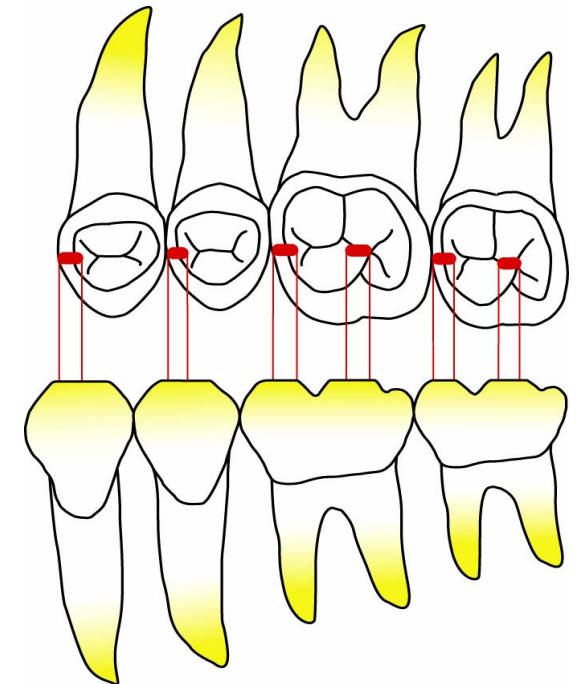

ロアー・バッカーライズド
オクルージョン




Leave the space
of a sheet of
occluding paper

Safety zone... occlusion point

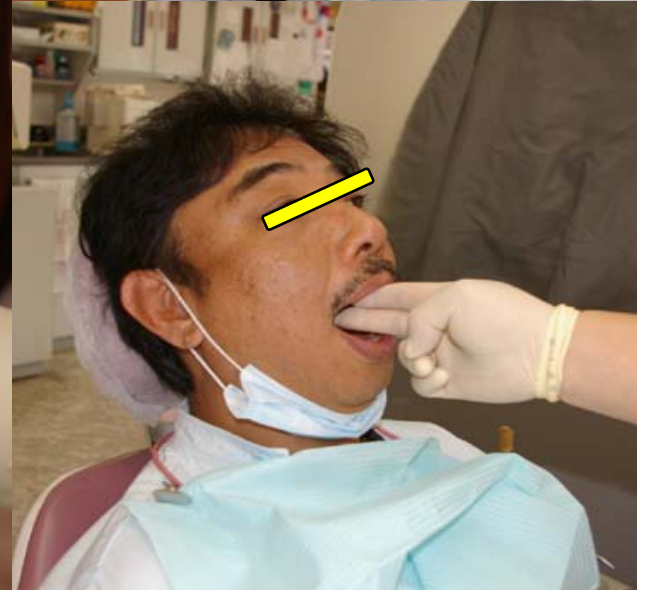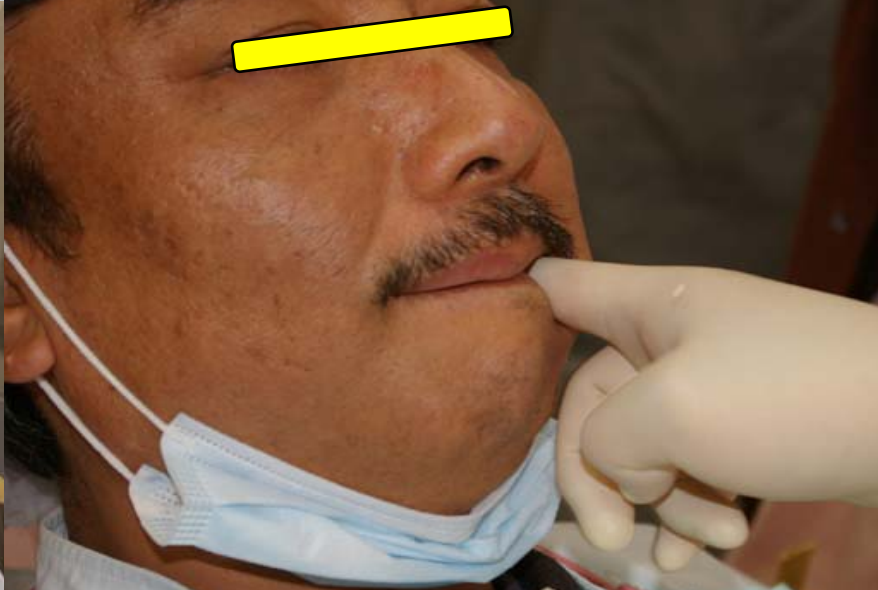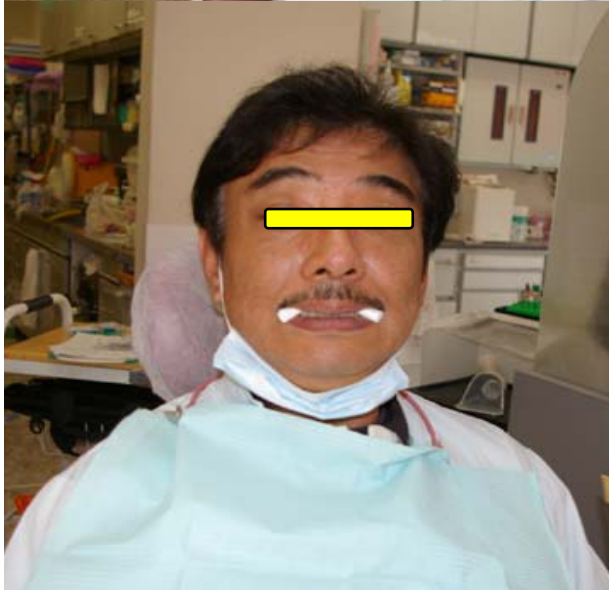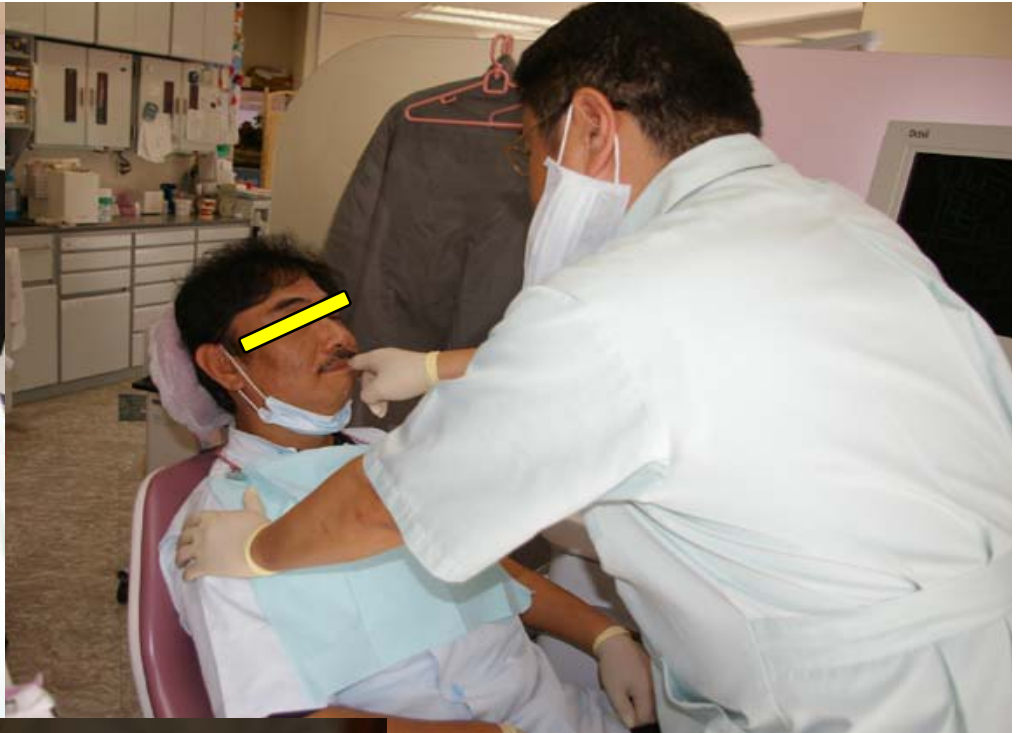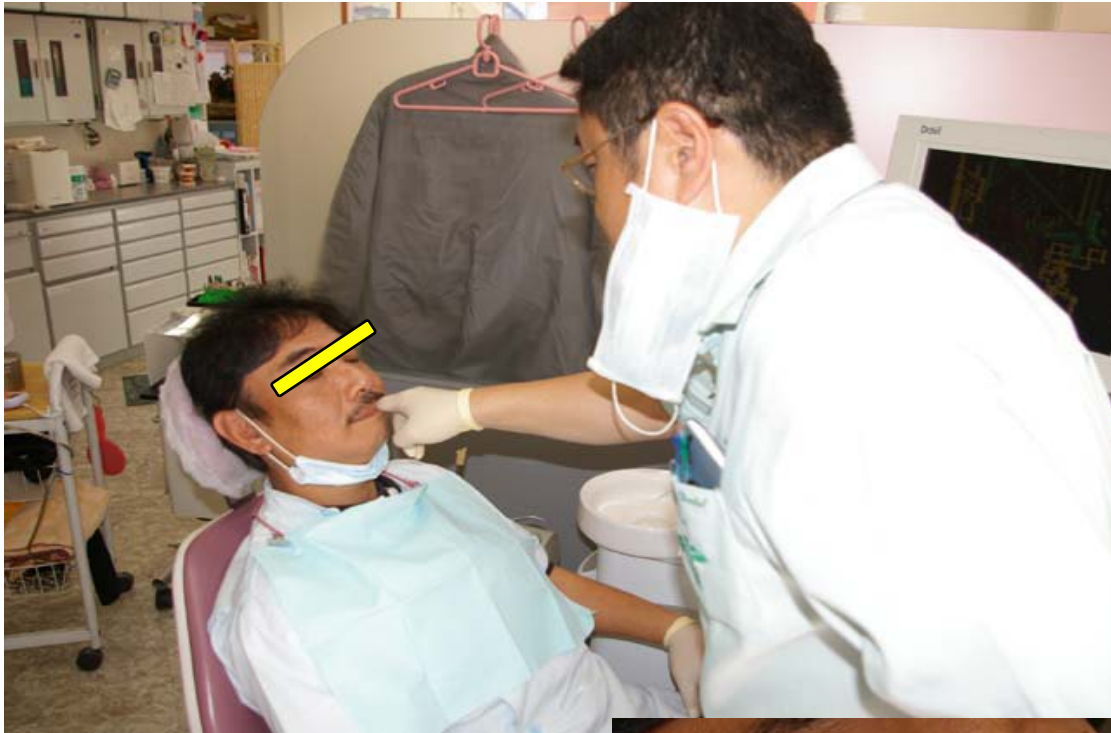Taboo zone... non-occlusion point





This trademark shows our wish
for everyone to be healthy.

©All rights are reserved by
Eiji Tomita December 2014



Lockjaw, fixed in about 5 minutes.

©All rights are reserved by
Eiji Tomita December 2014